



**Chettinad**  
Dental College & Research Institute



***Department of ORAL MEDICINE, DIAGNOSIS & RADIOLOGY***

**SPECIAL CASE RECORD**

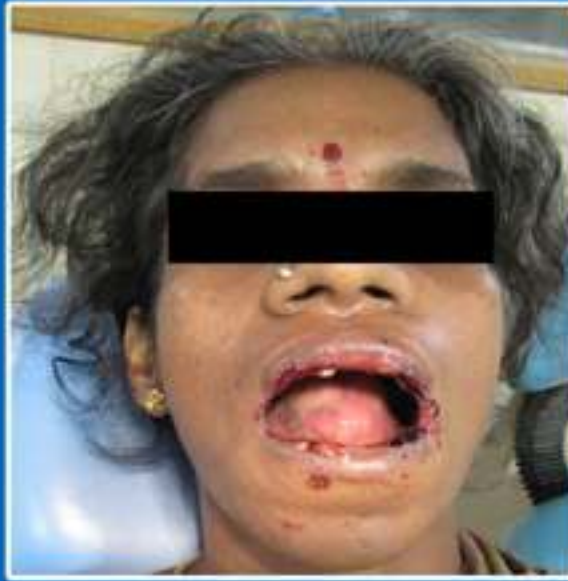*Patient Name: Mrs.Hemavathy*

*Age/sex: 35y/F*

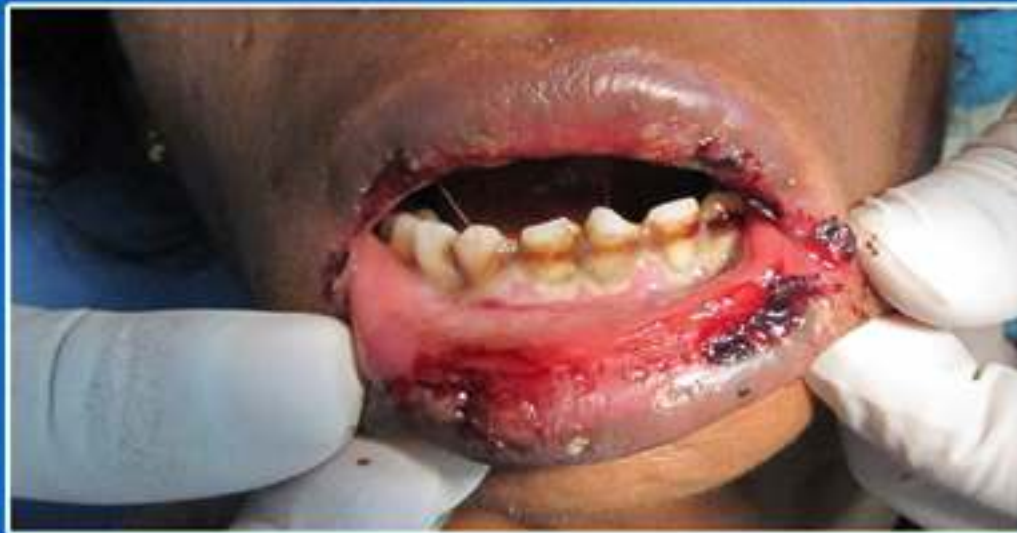*OP No: 201004200045*

*Diagnosis: Erythema Multiforme*

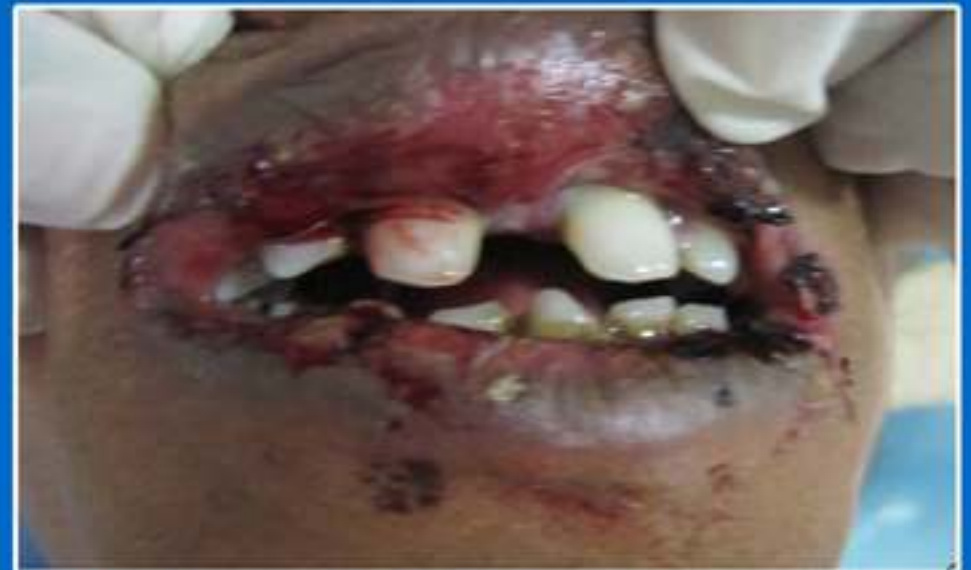# *Pre Treatment*



*Profile*



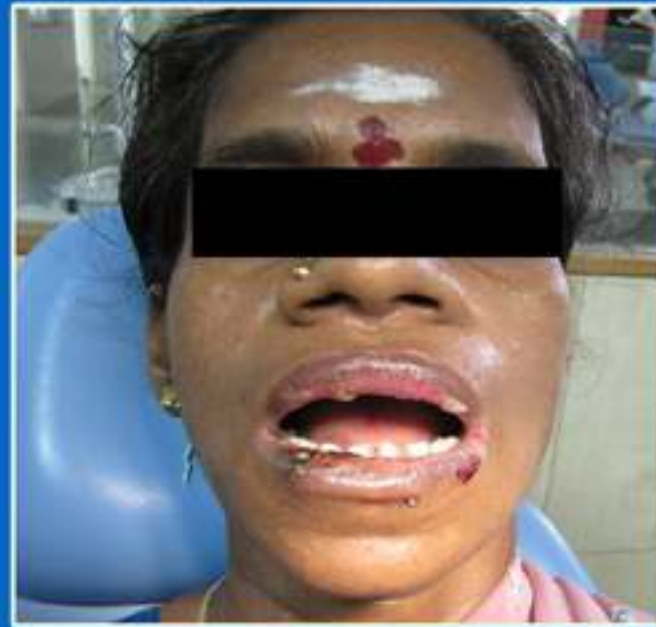*Lower*



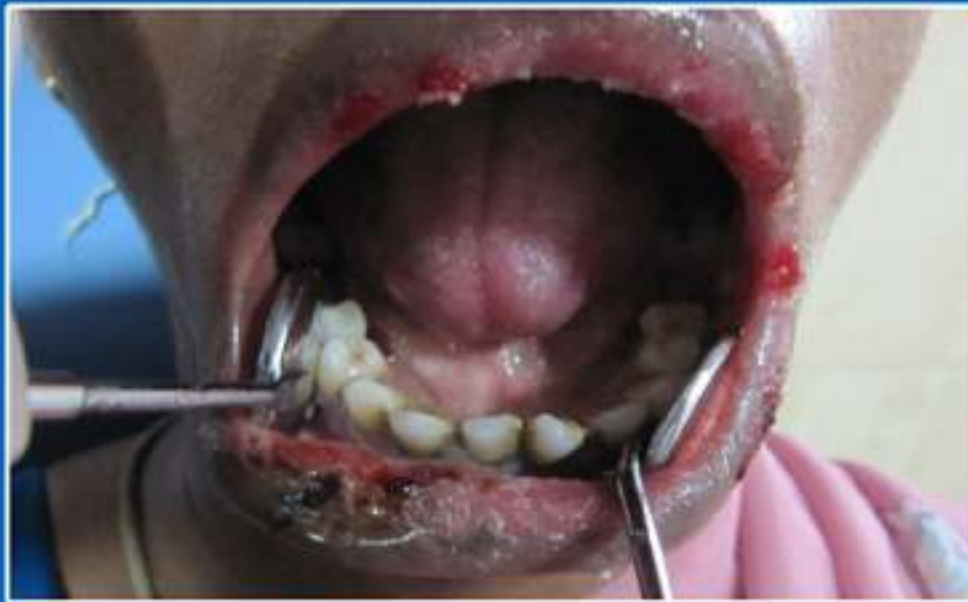*Upper*

*Labial Mucosa*

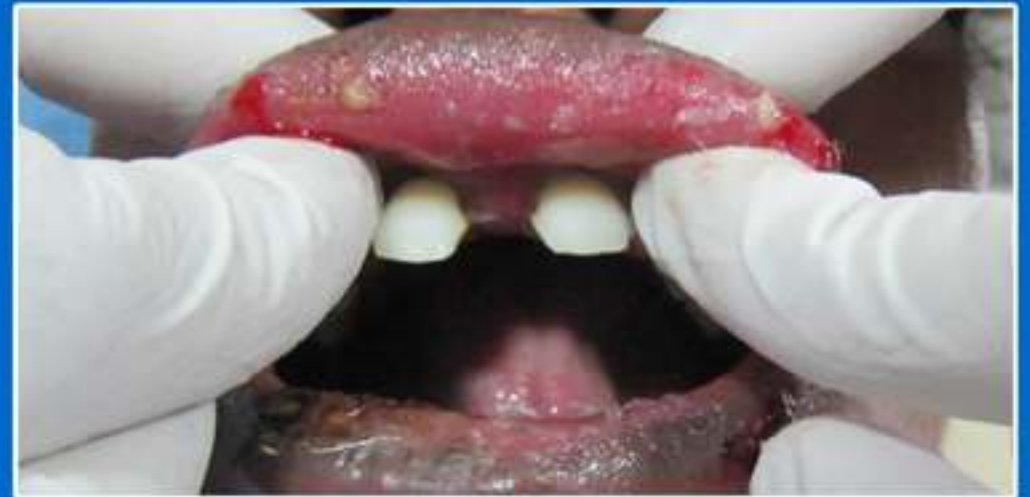# *3 Days Post Treatment*



*Profile*



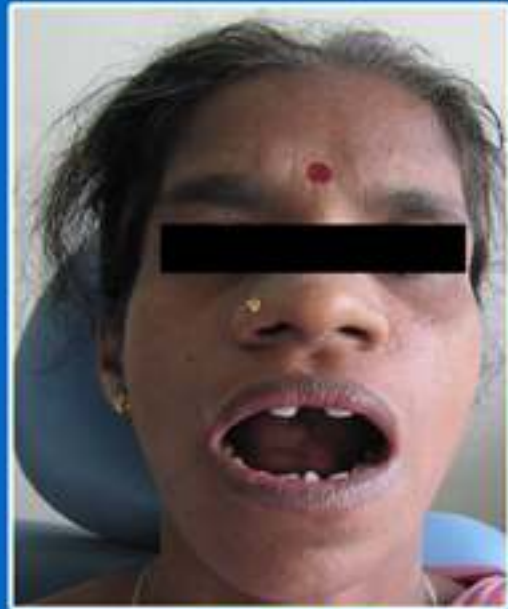*Lower*



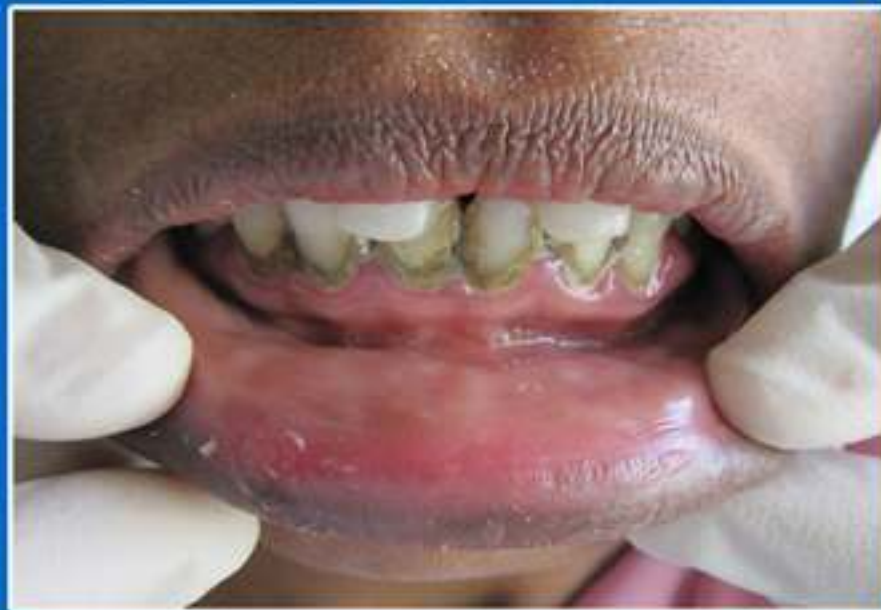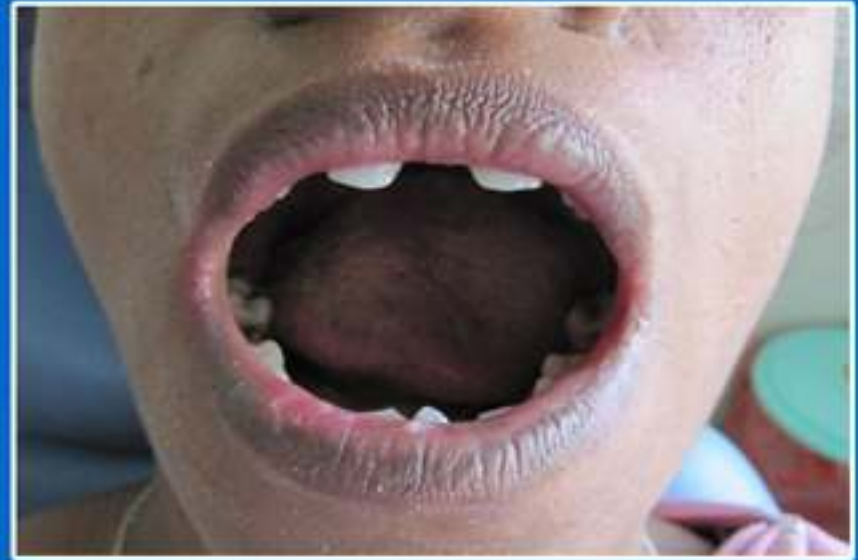*Upper*

*Labial Mucosa*

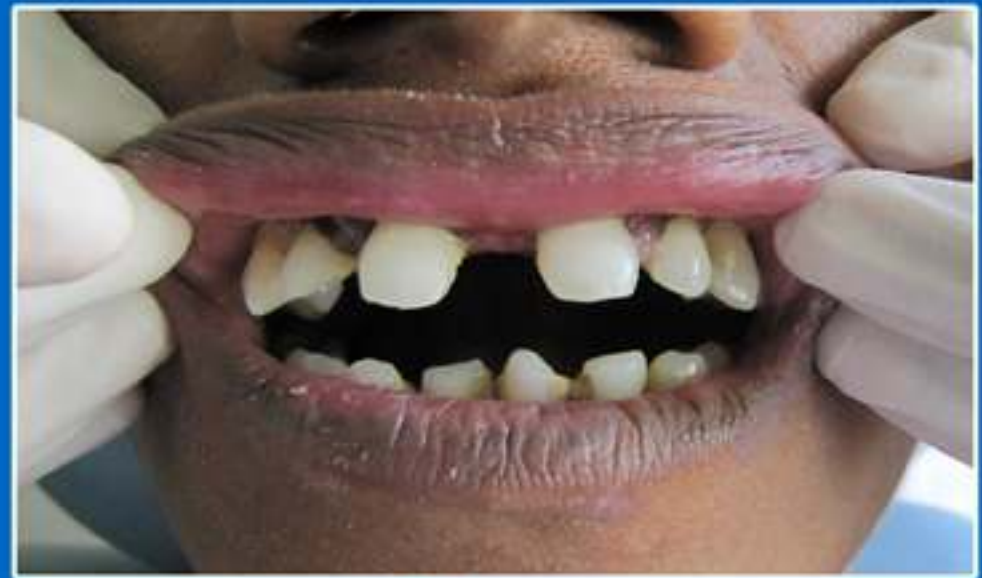# 9 Days Post Treatment



*Profile*



*Lower*



*Upper*

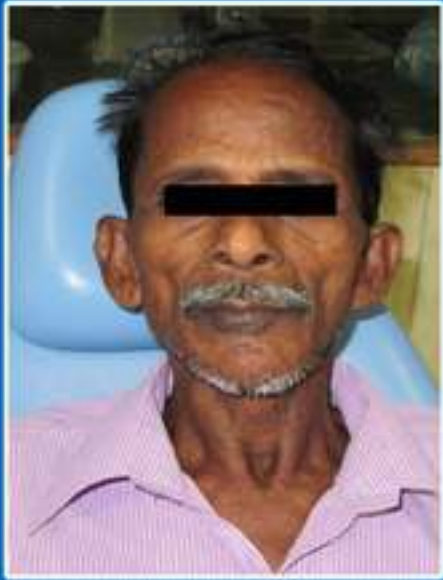*Patient Name: Mr.Karthikeyan*

*Age/sex: 55y/M*

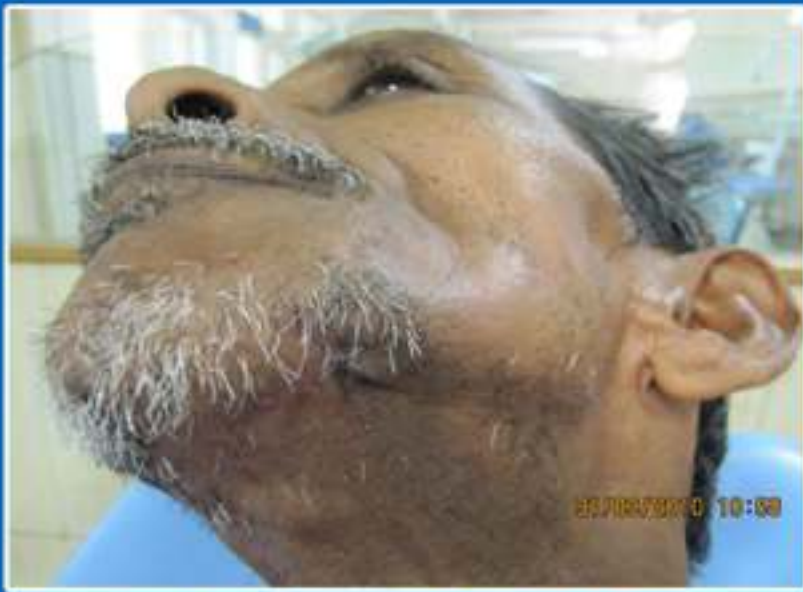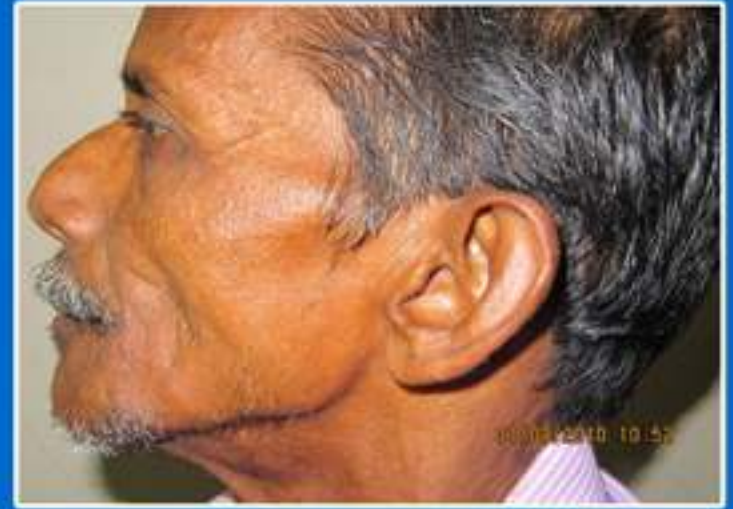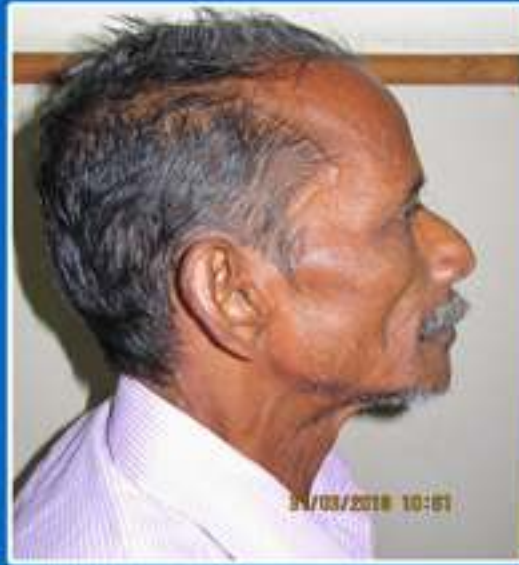*OP No: 201003310001*

*Diagnosis: T.B. Osteomyelitis with Pathological #  
of Left Mandibular Parasymphysis*

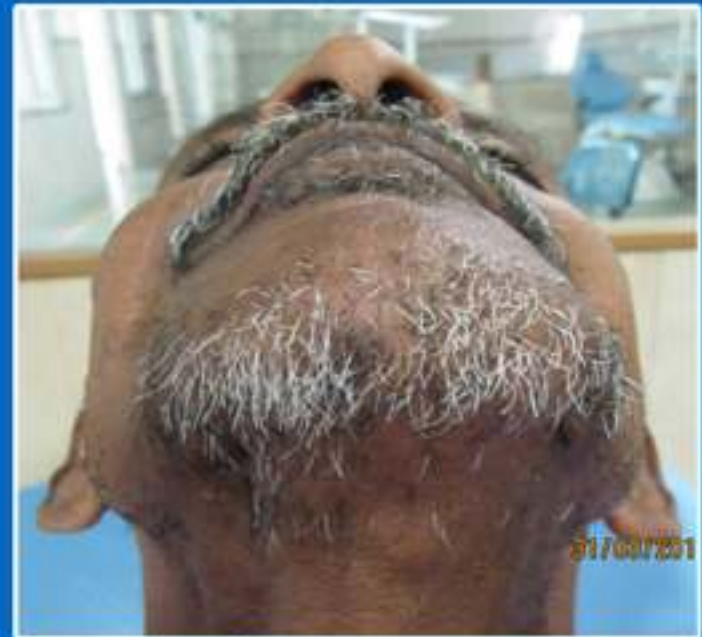# *T.B. Osteomyelitis*



*Profile*

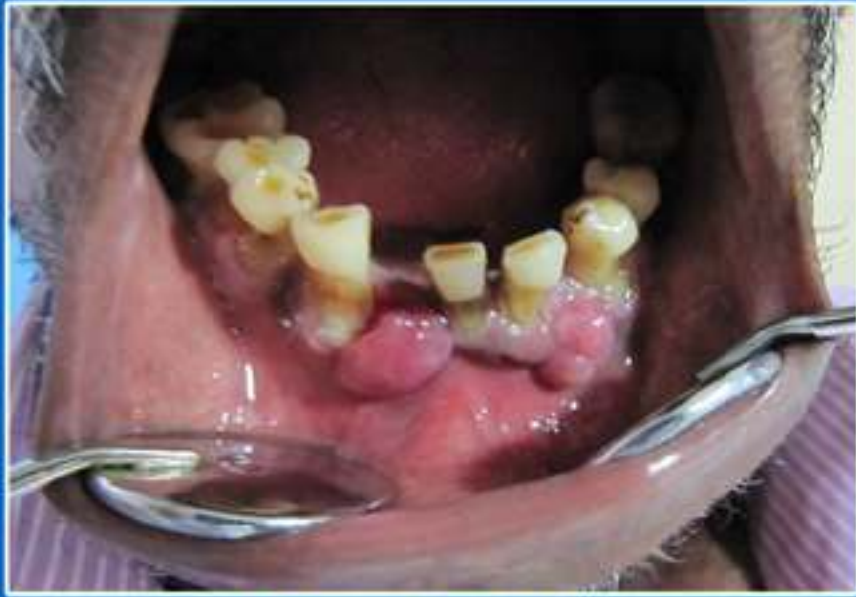

*Extra Oral Sinus with Skin Puckering*

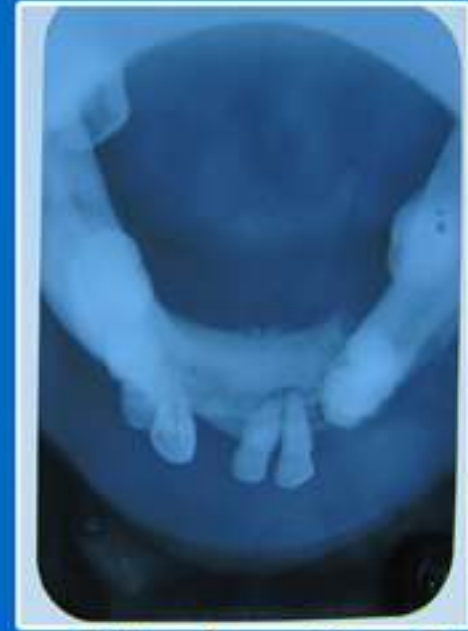

*Facial Asymmetry*

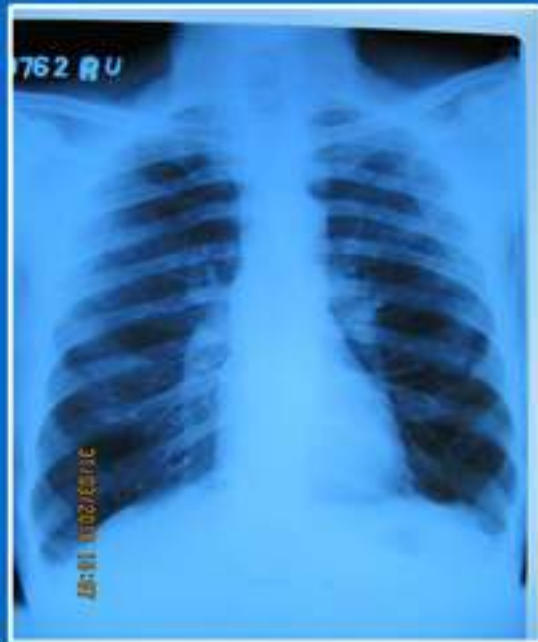# *T.B. Osteomyelitis*



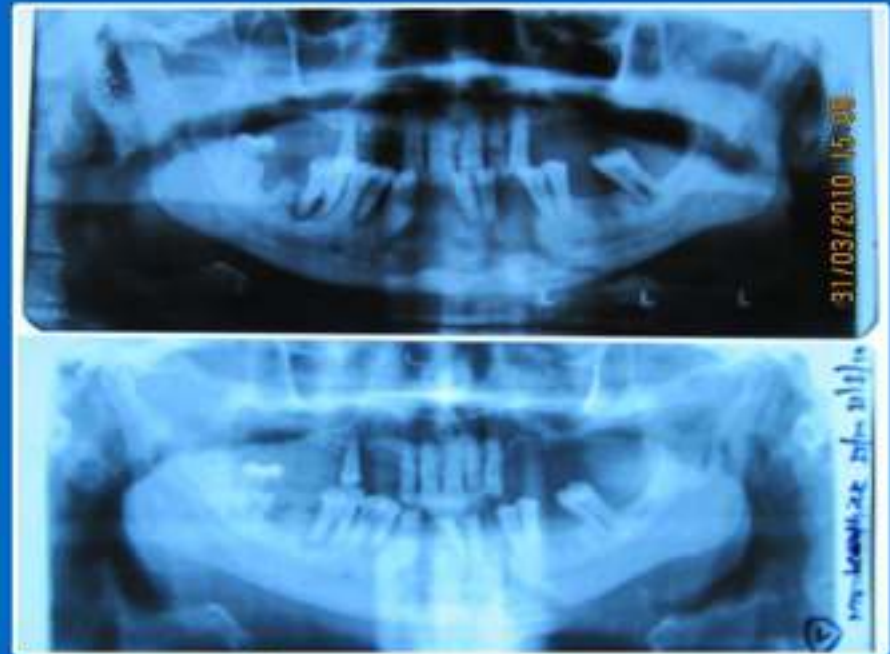
*Intra Oral*



*Mandibular Occlusal*



*Chest X-Ray*



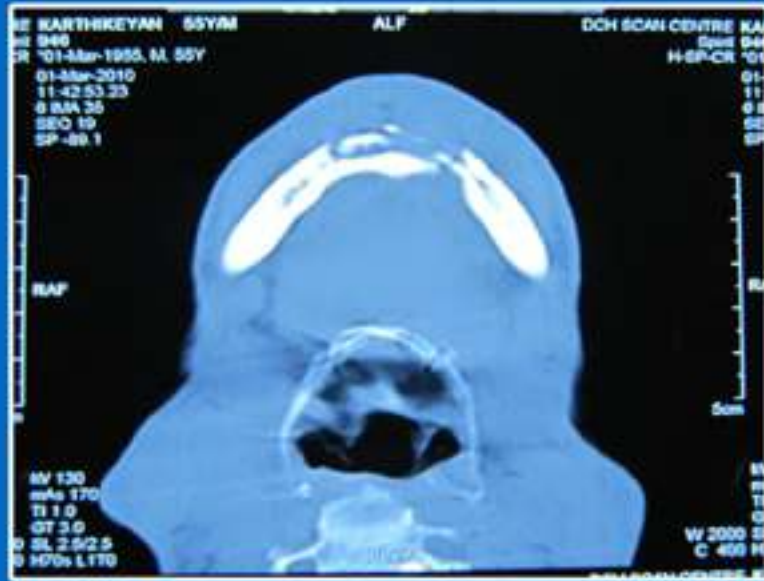*OLD*

*NEW*

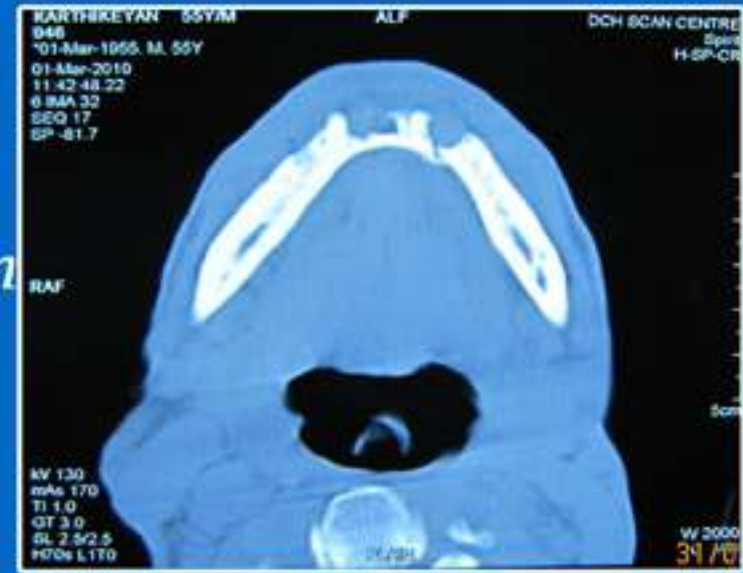
*Orthopantomogram*



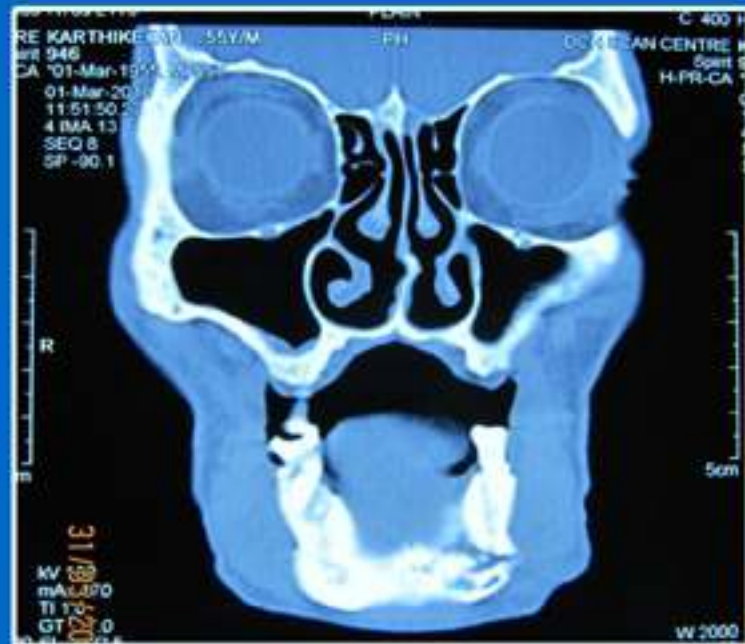# T.B. Osteomyelitis



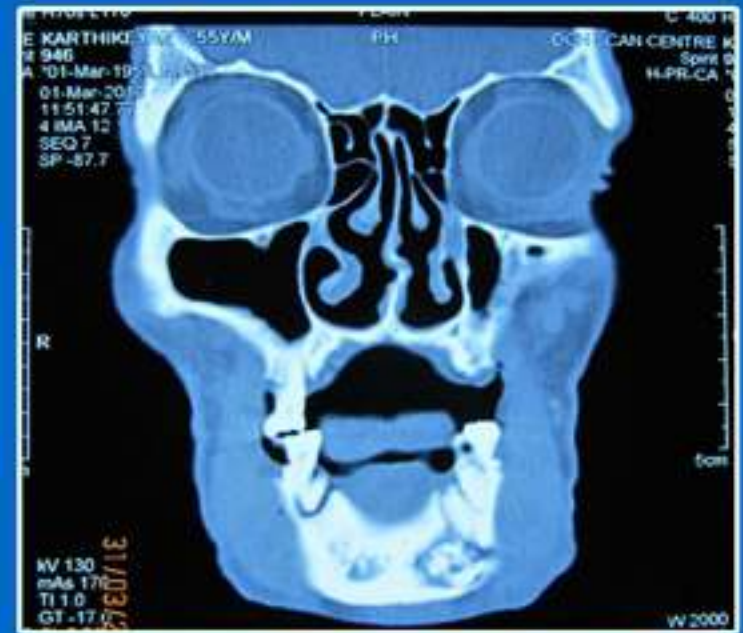*Axial Section*



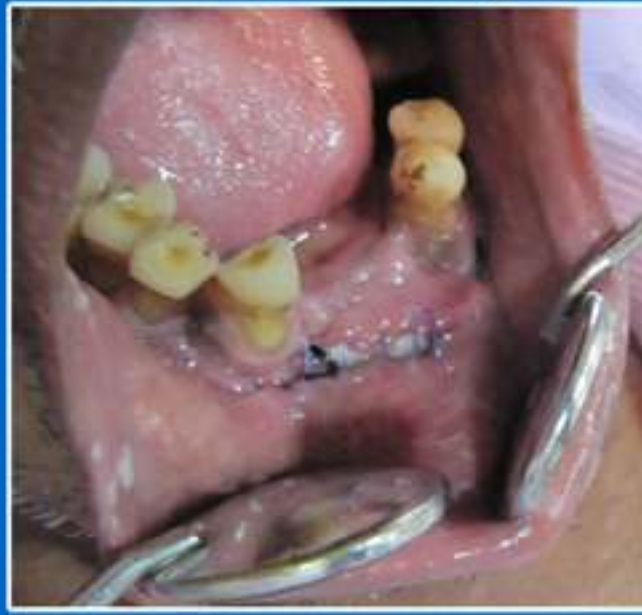## *Computerised Tomography*



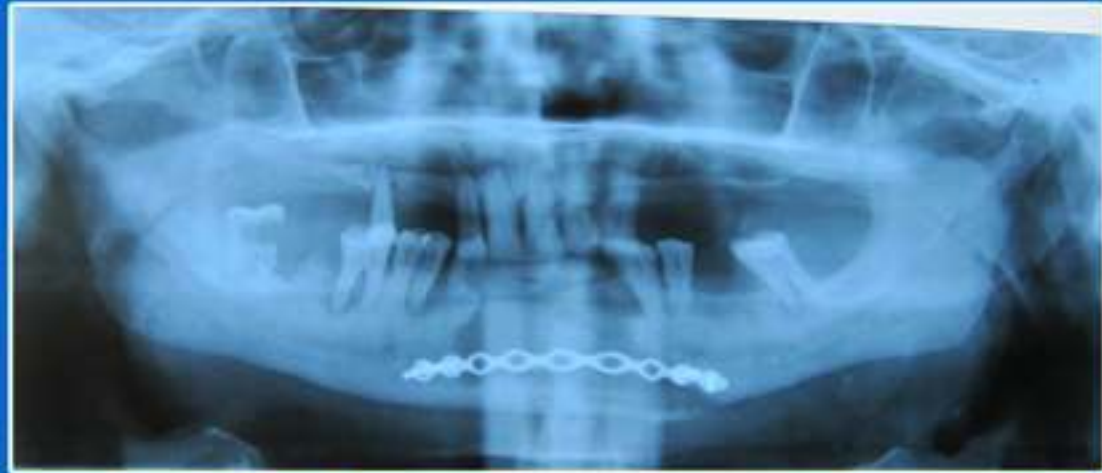*Coronal Section*



# *T.B. Osteomyelitis*

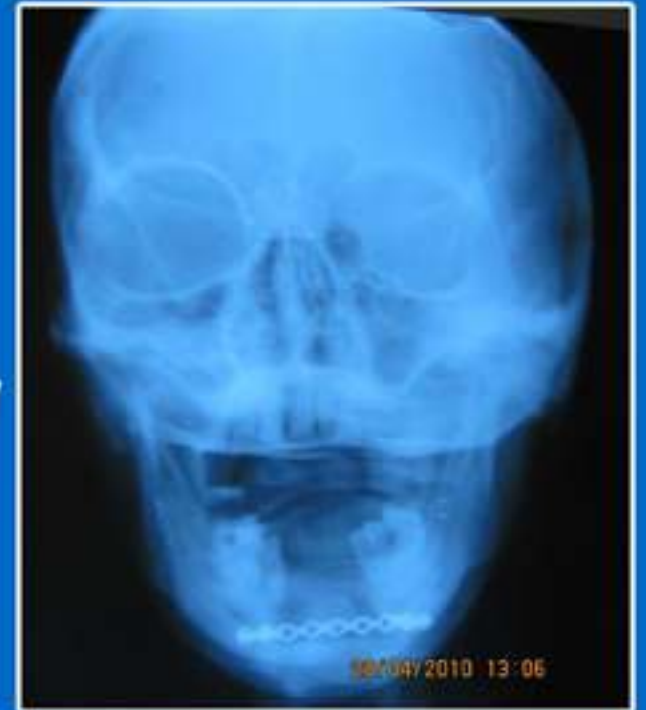

*Post Treatment*



*Orthopantomogram*

*PA Skull*



*Patient Name: Mrs.Ellammal*

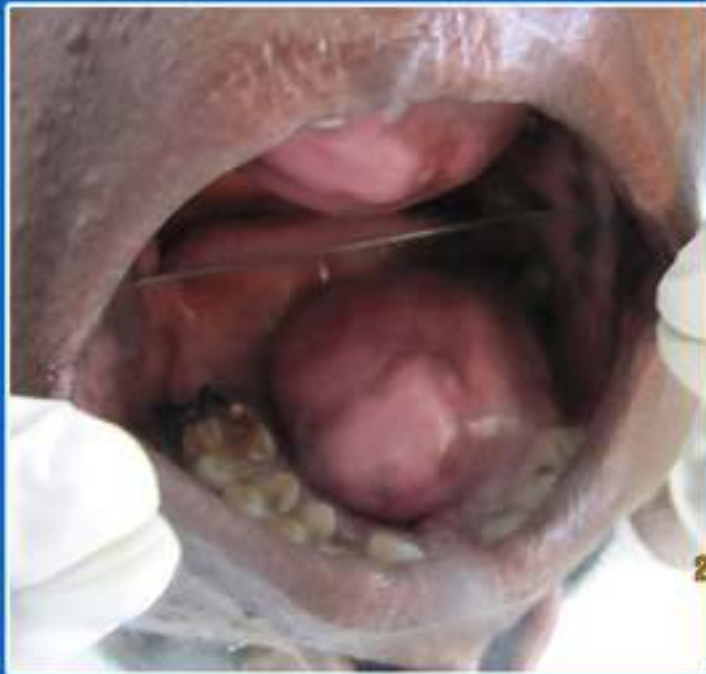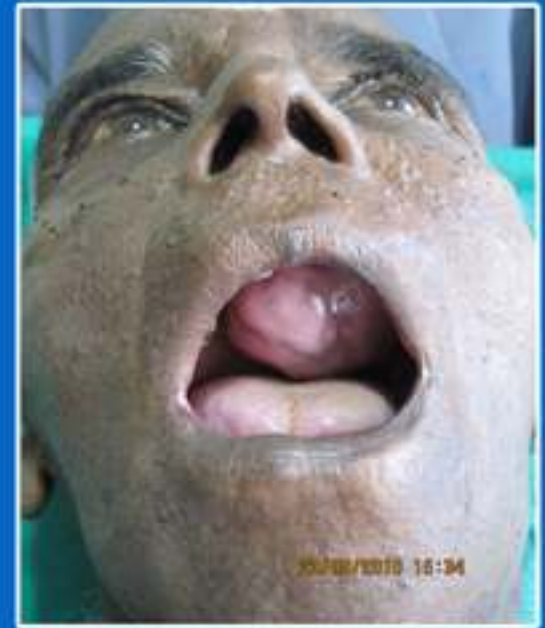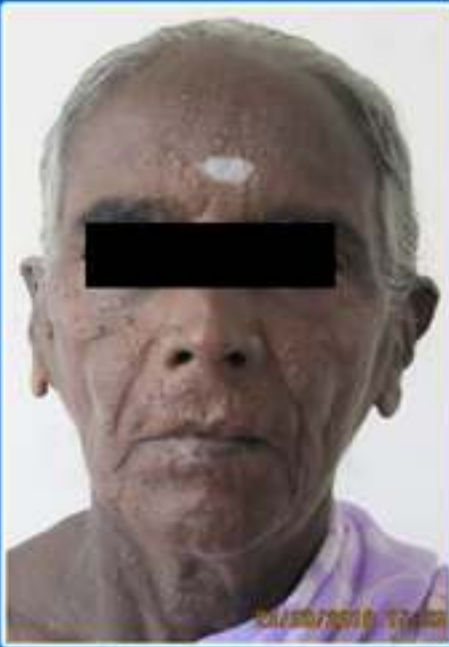*Age/sex: 56y/F*

*OP No: 201027120013*

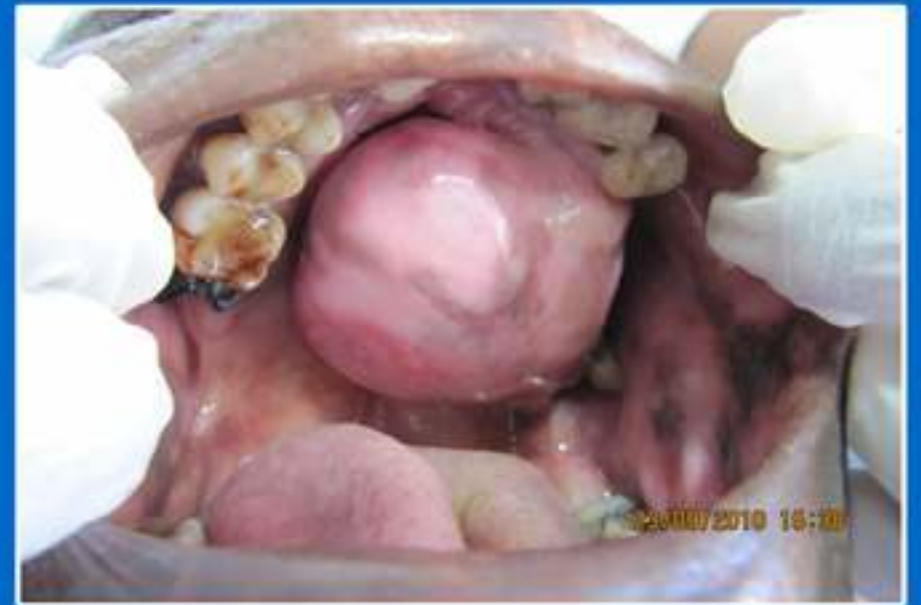*Diagnosis: Pleomorphic Adenoma of Palate*

# *Pleomorphic Adenoma of Palate*

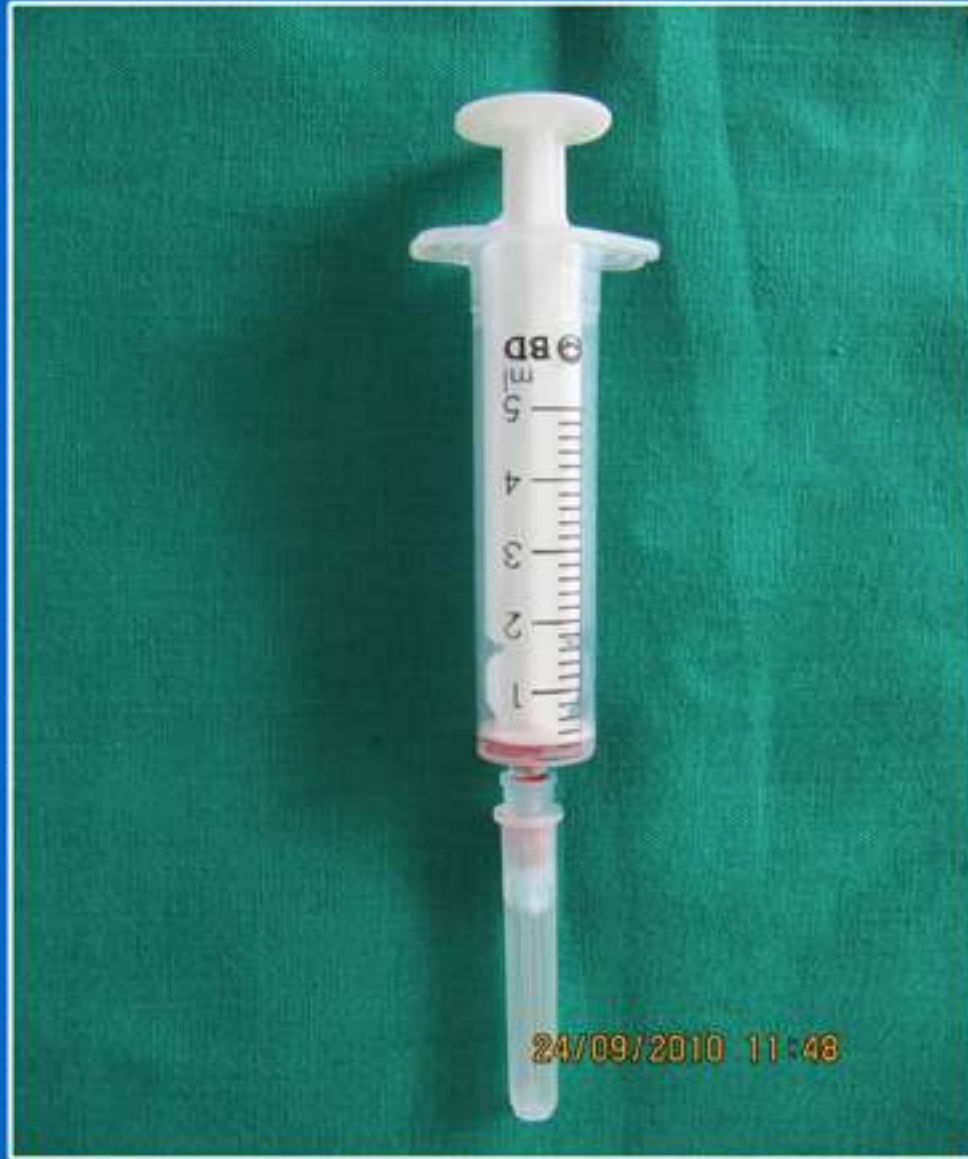*Profile*



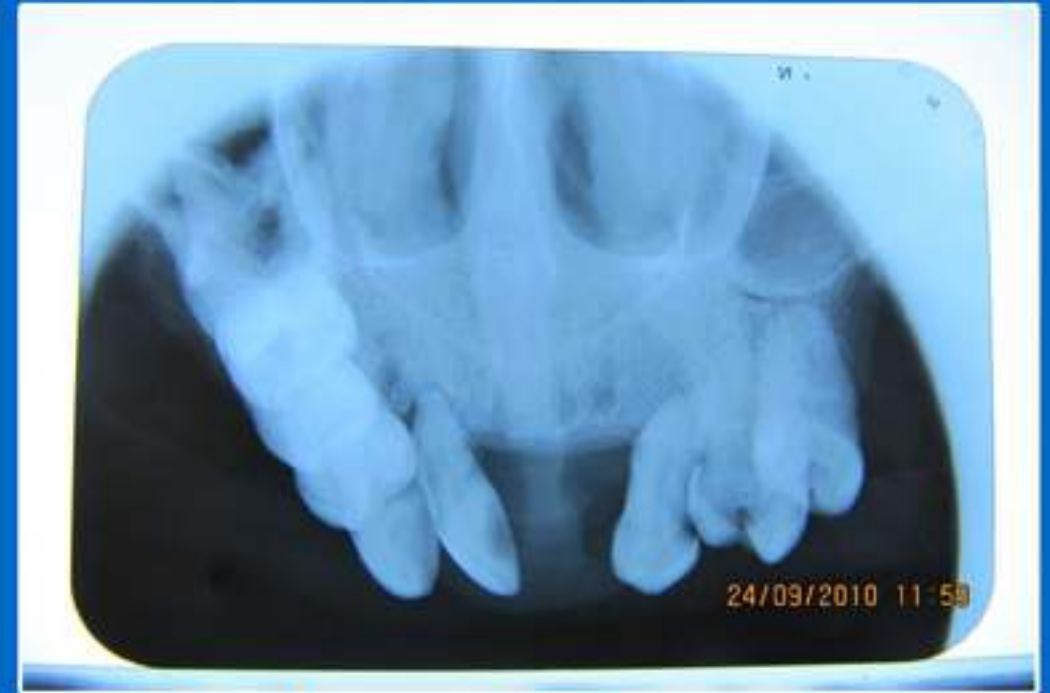*Palatal Swelling*



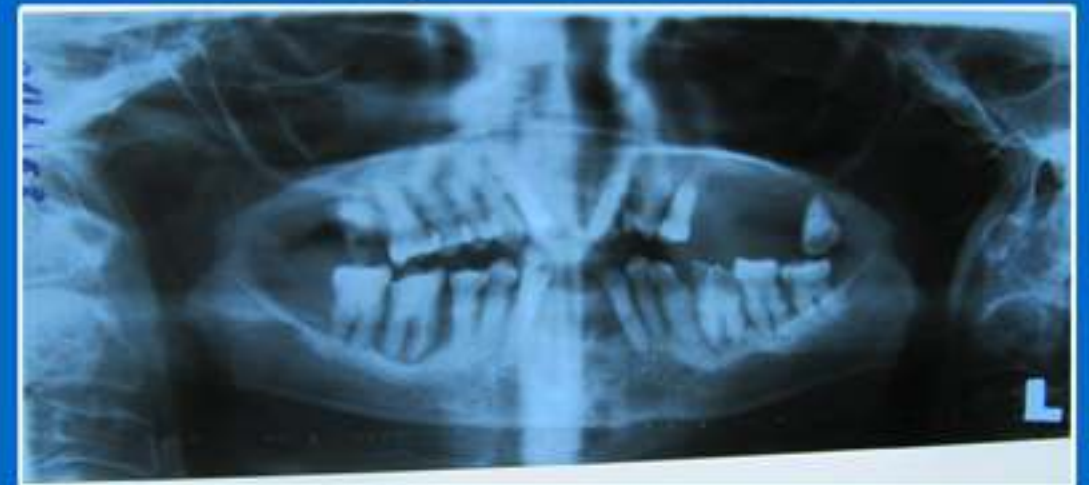# *Pleomorphic Adenoma of Palate*



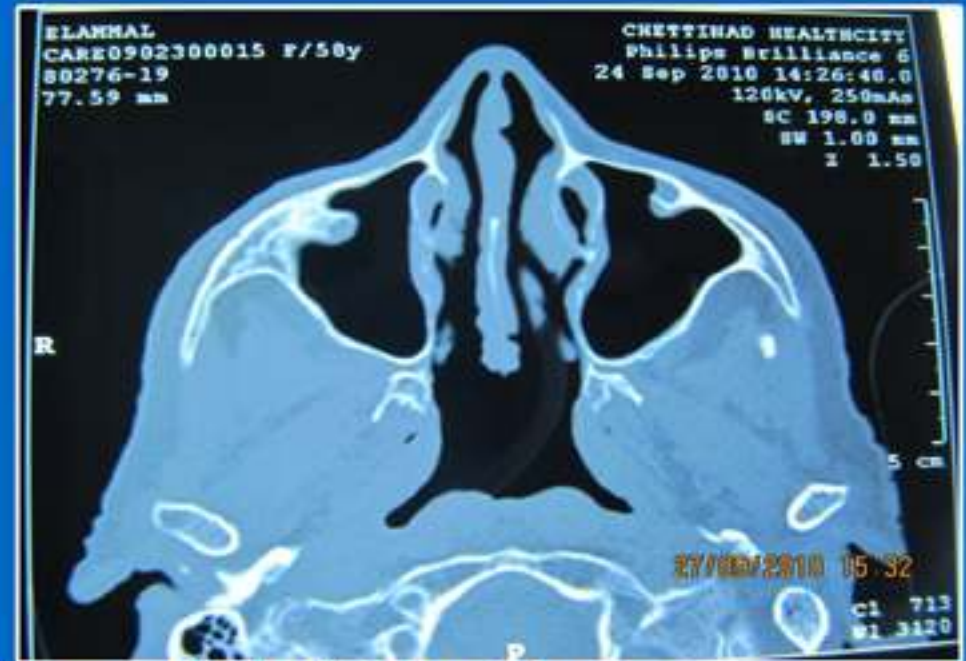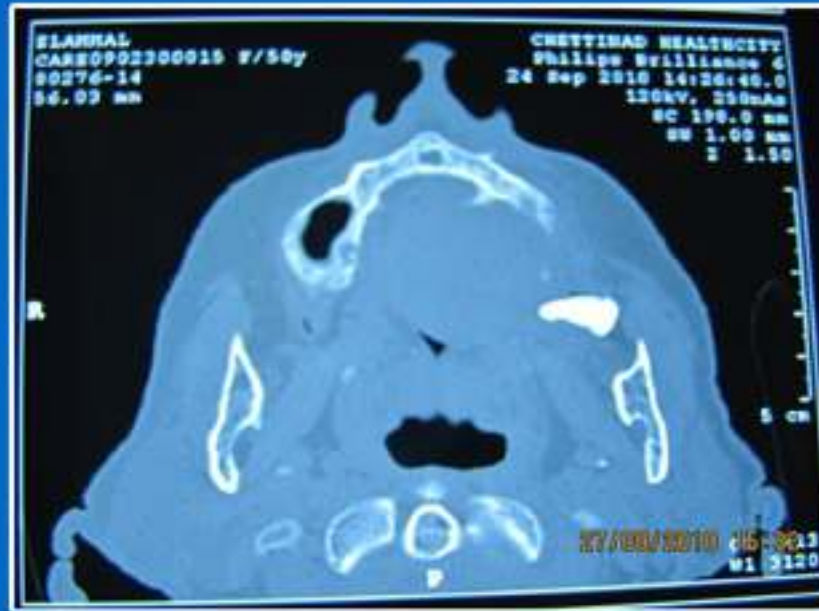*Aspirate*



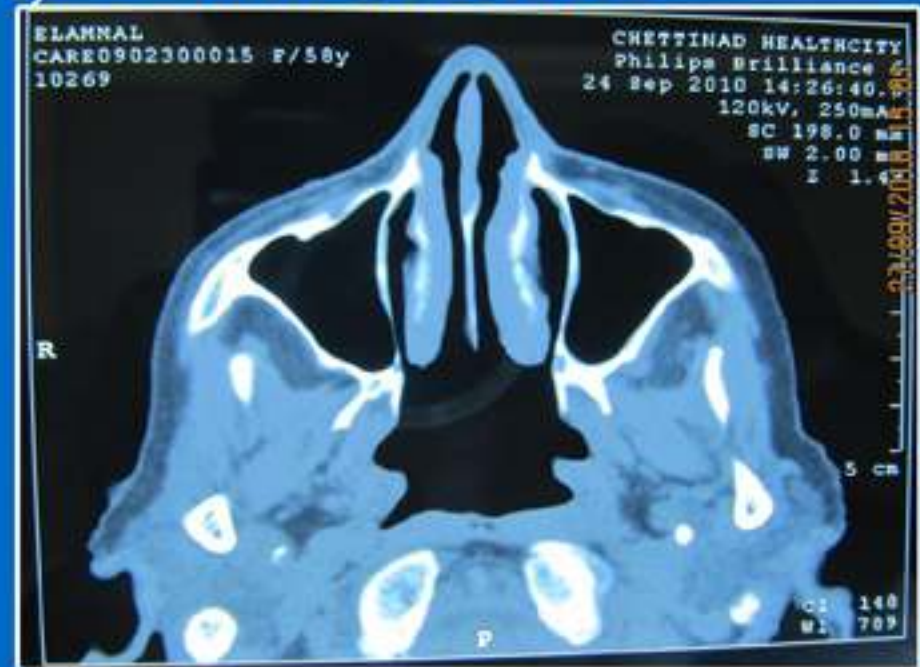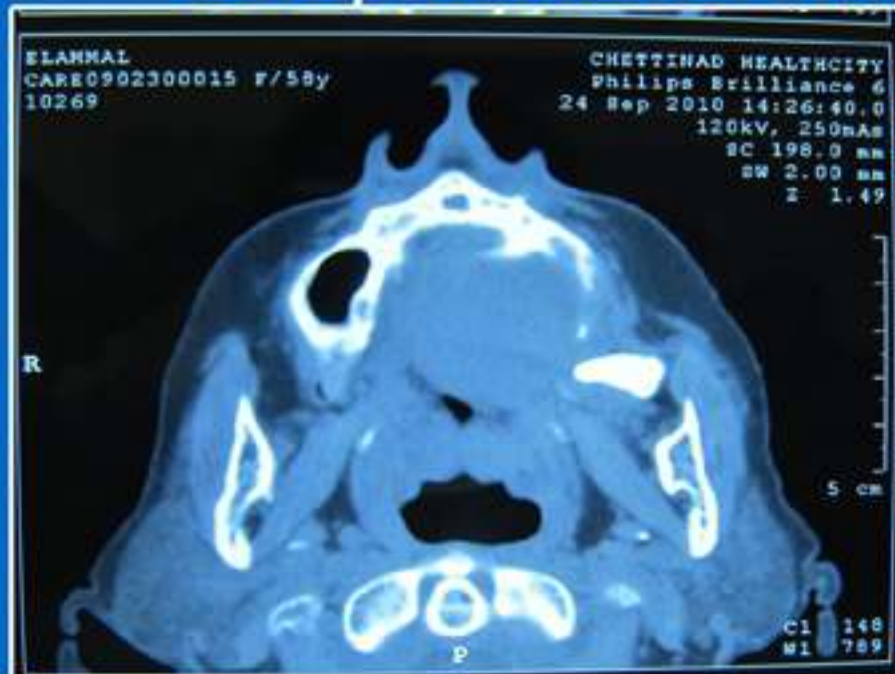
*No Bony Involvement*



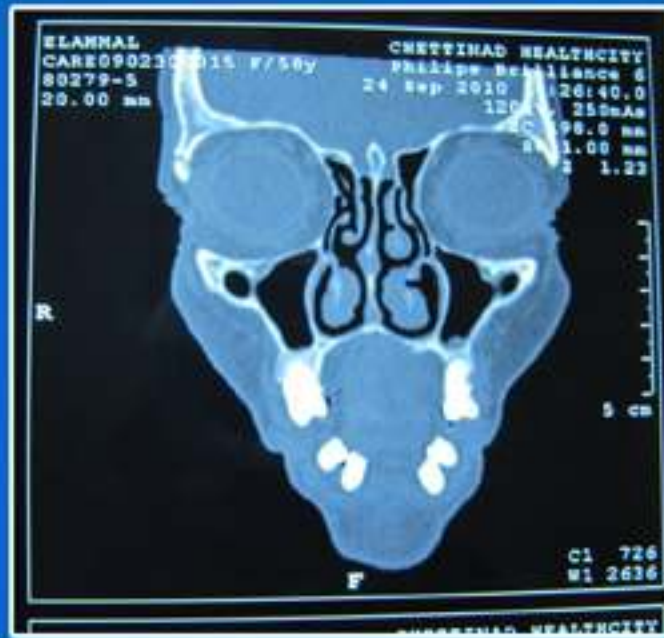# Pleomorphic Adenoma of Palate



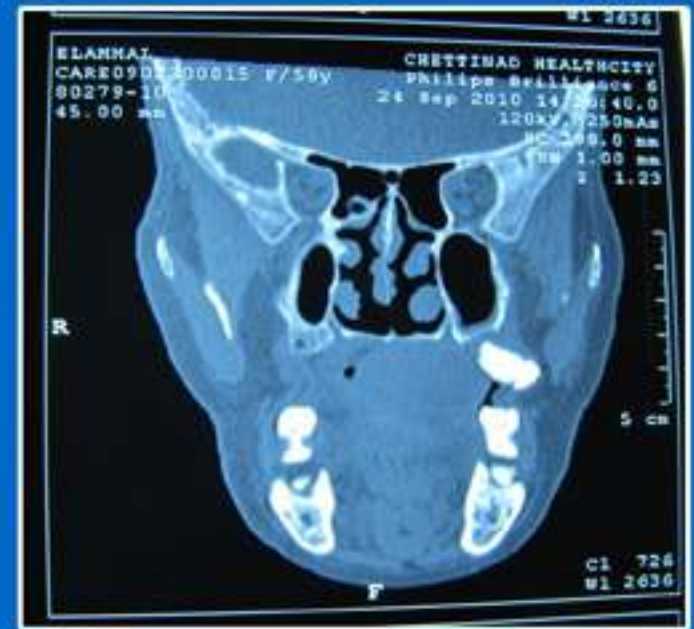## Computerised Tomography - Axial Sections



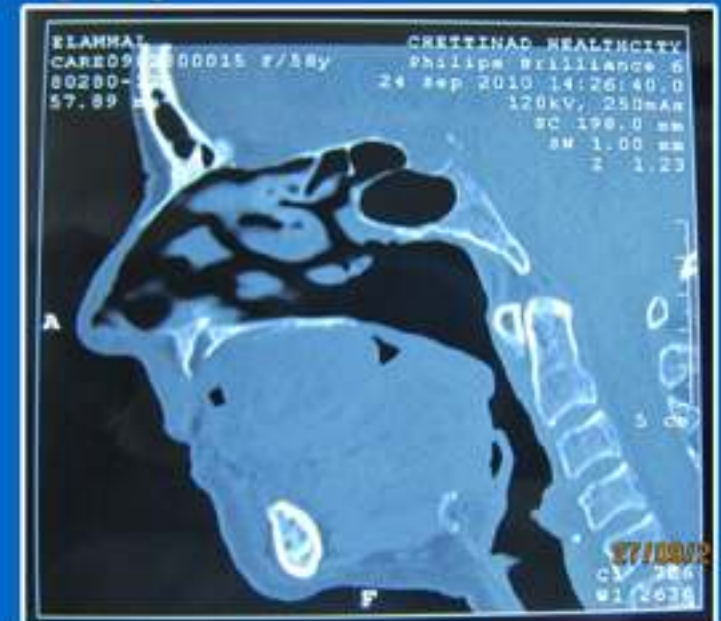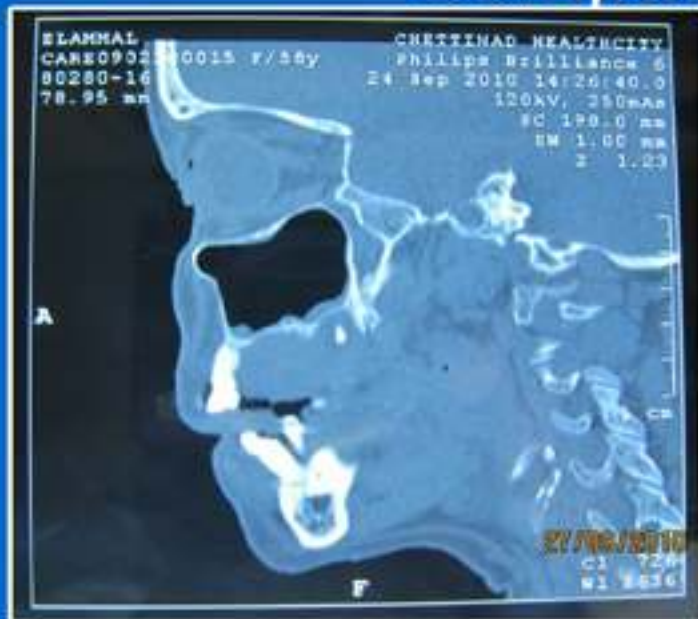# *Pleomorphic Adenoma of Palate*



*Coronal Section*

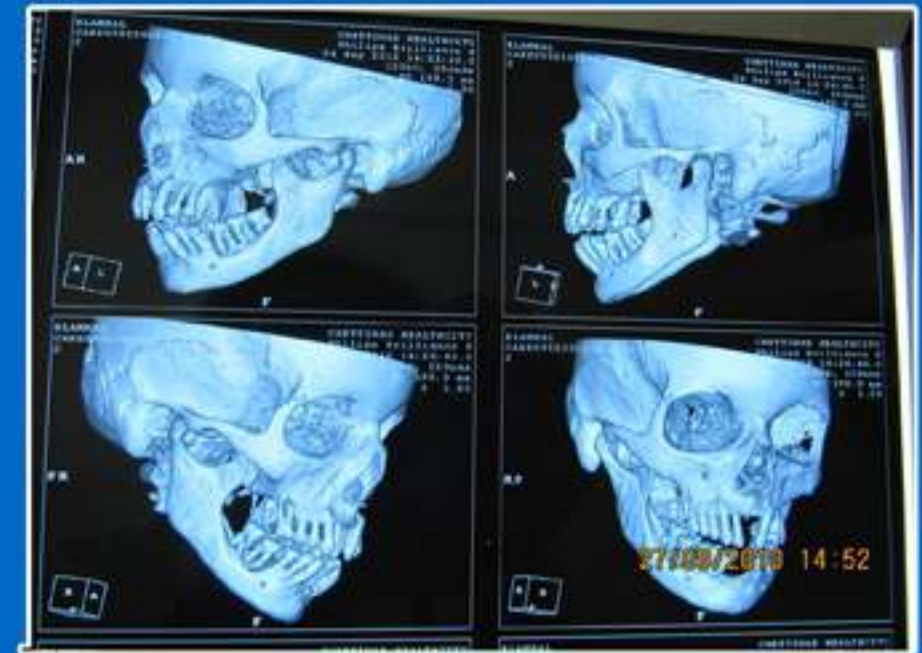
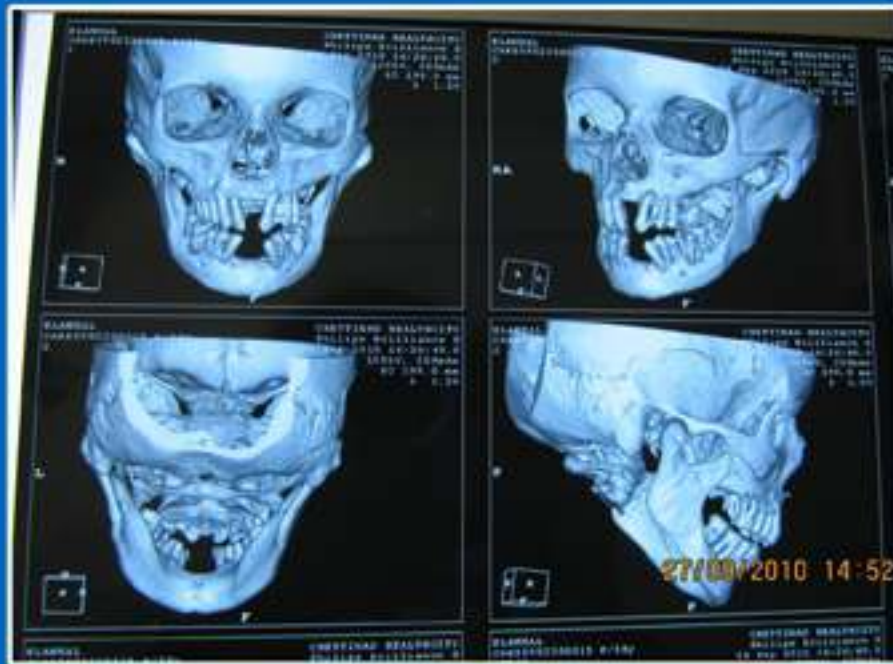

## *Computerised Tomography*

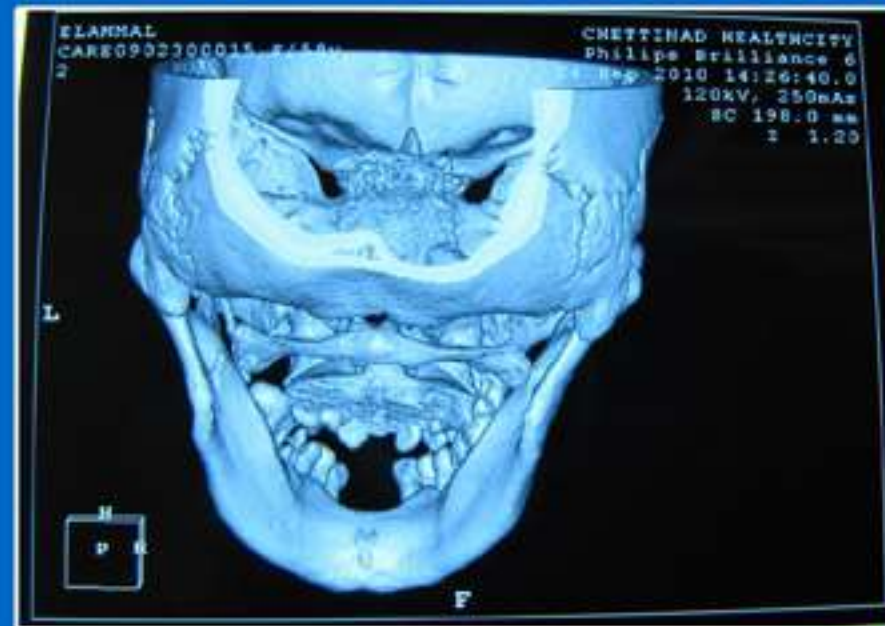

*Sagittal Section*

# Pleomorphic Adenoma of Palate

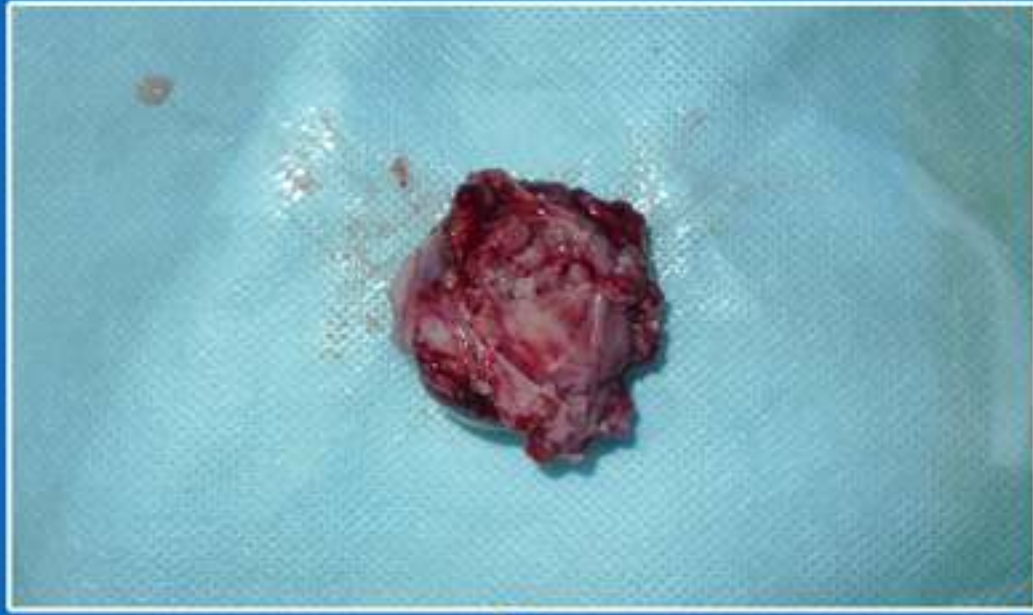

## 3D Computerised Tomography

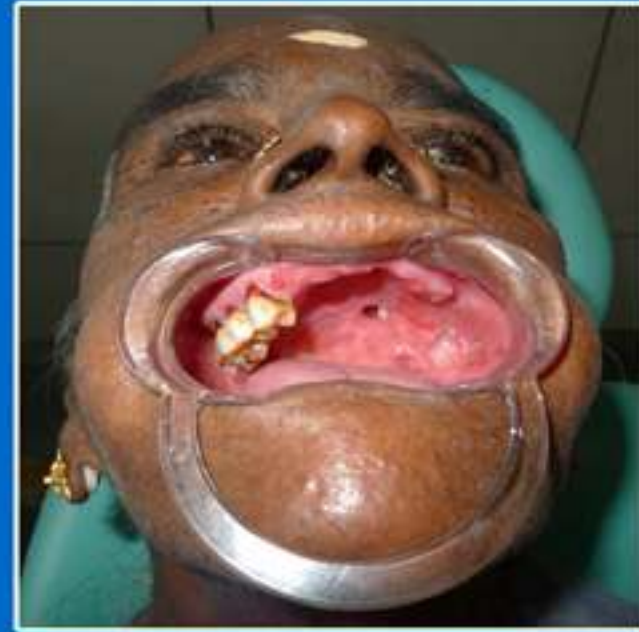



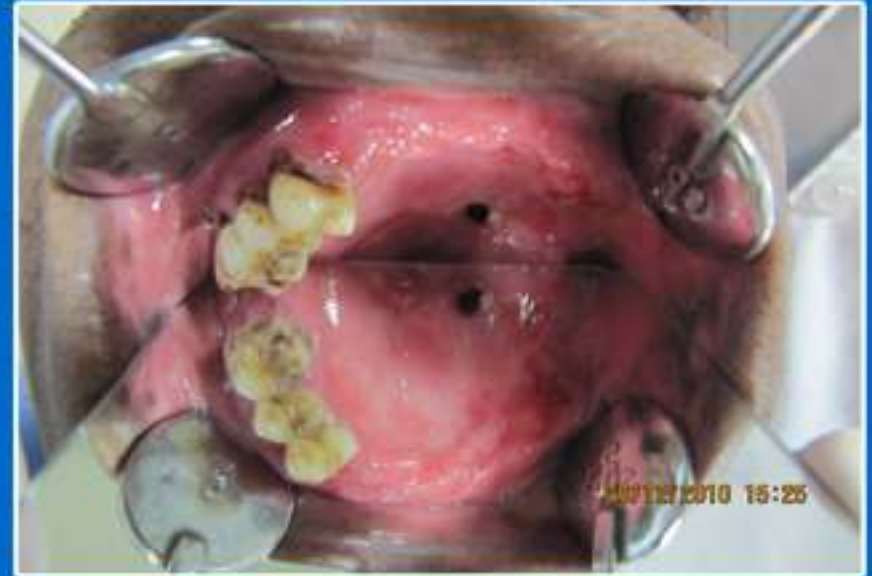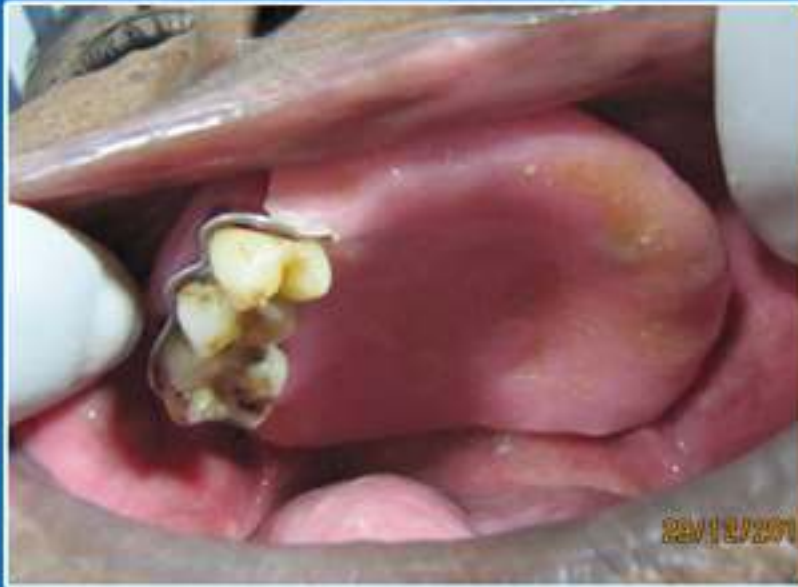# *Pleomorphic Adenoma of Palate*



*Surgical Specimen*



*Post Operative*



*Patient Name: Mrs.Umarani*

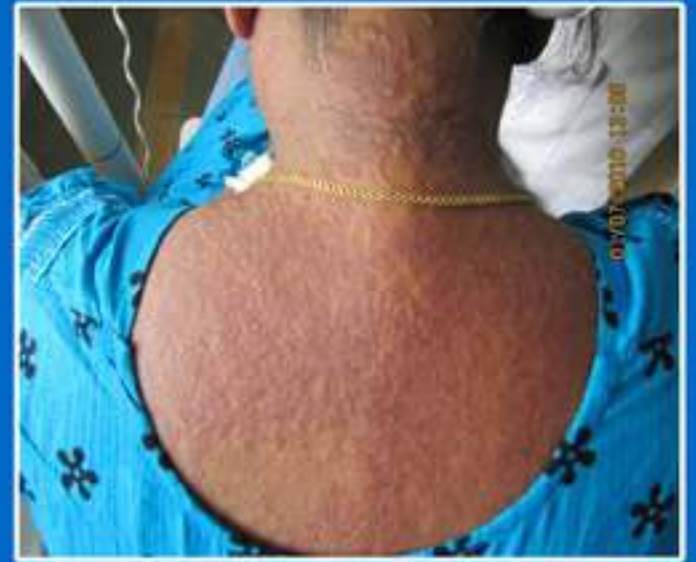*Age/sex: 39y/F*

*OP No: 201007010019*

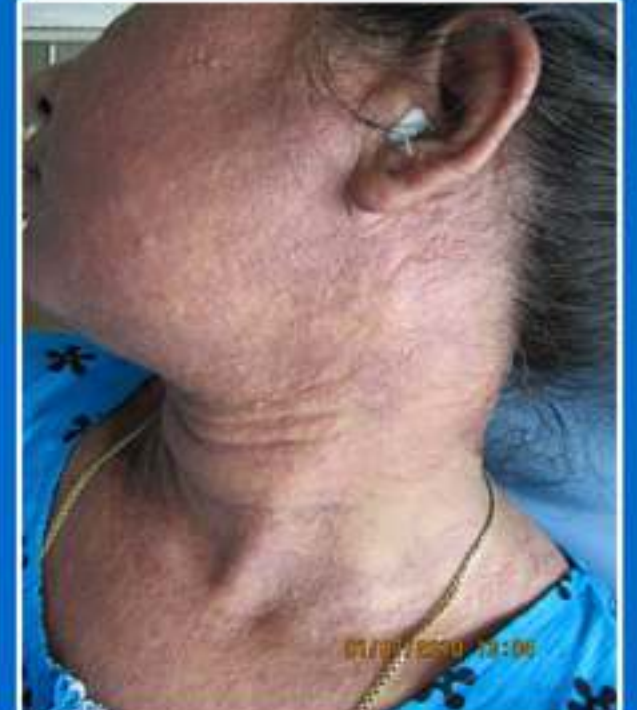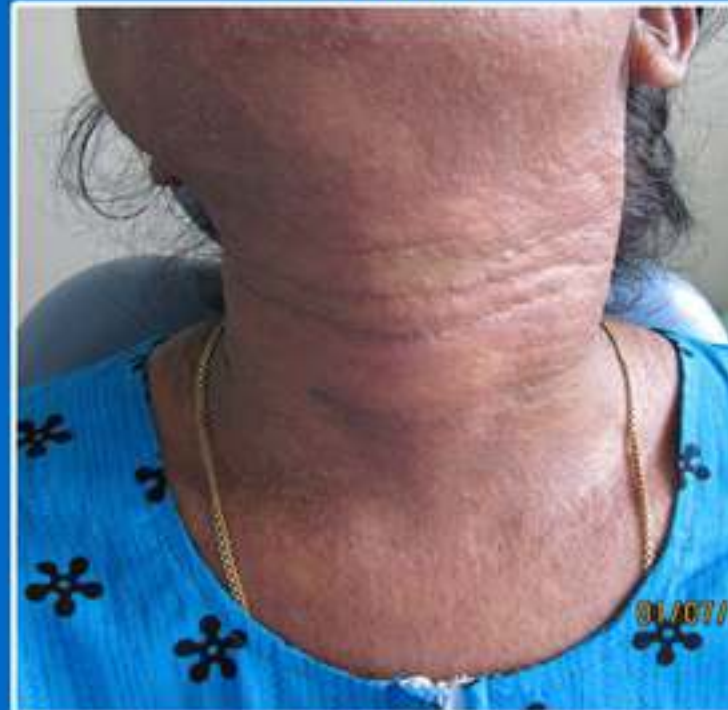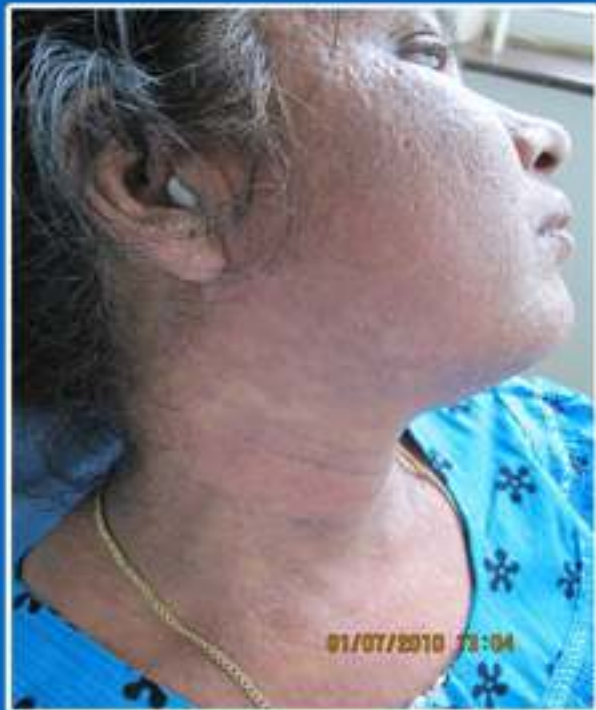*Diagnosis: Erythema Multiforme  
- Drug Induced*

# *Erythema Multiforme*

*- Drug Induced*

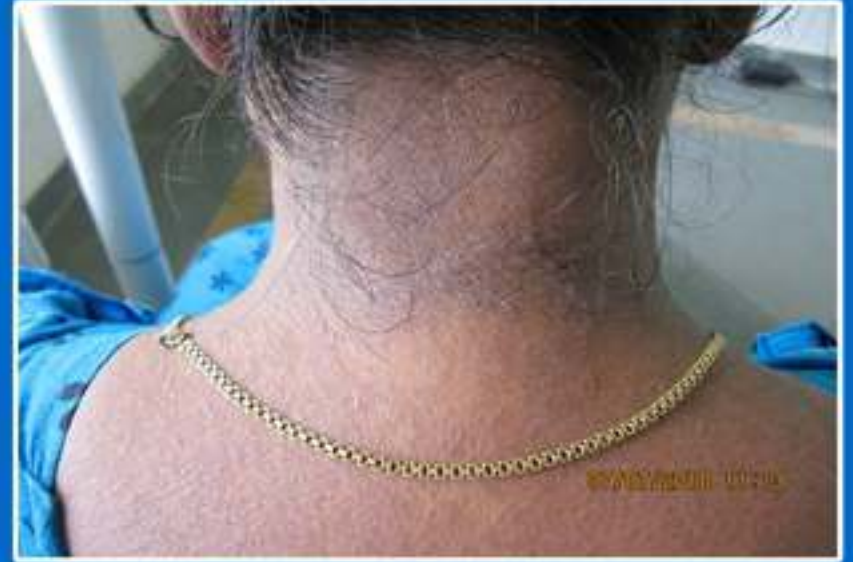
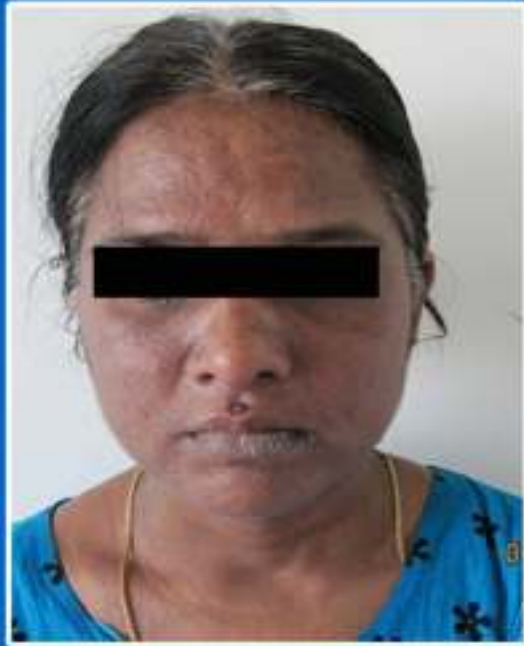
*Maculopapular  
Rashes*

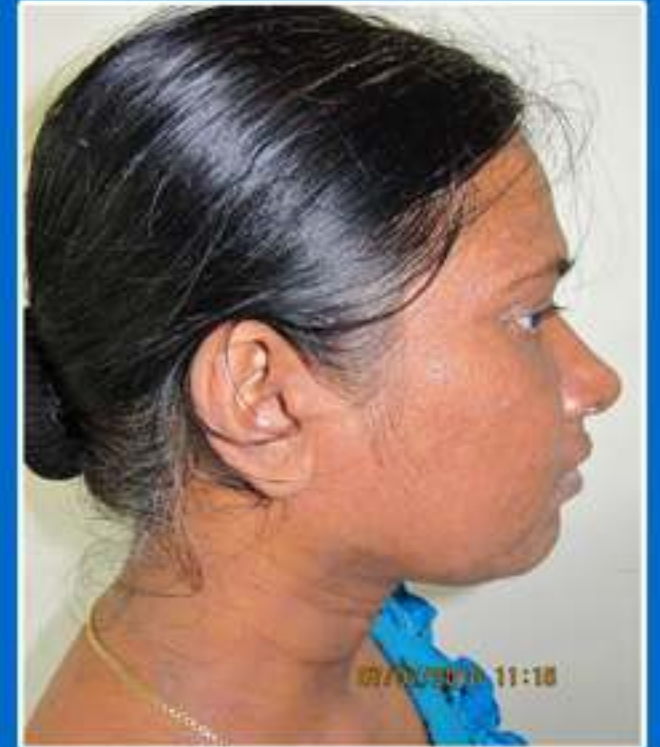
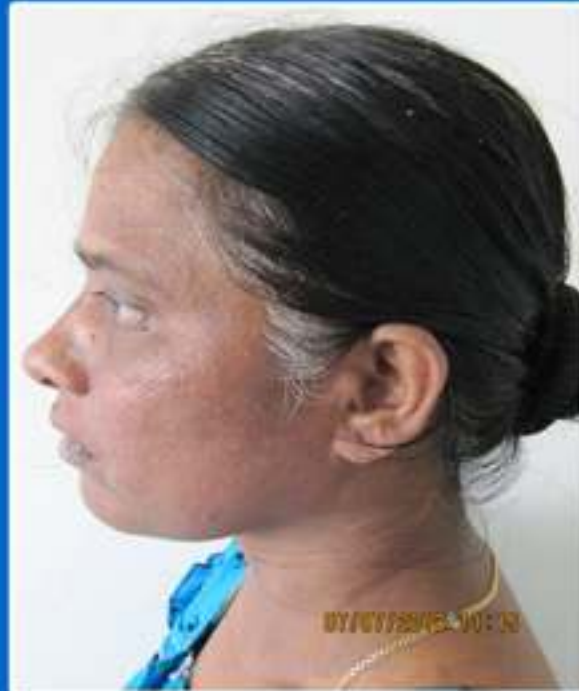
# *Erythema Multiforme*

*- Drug Induced*

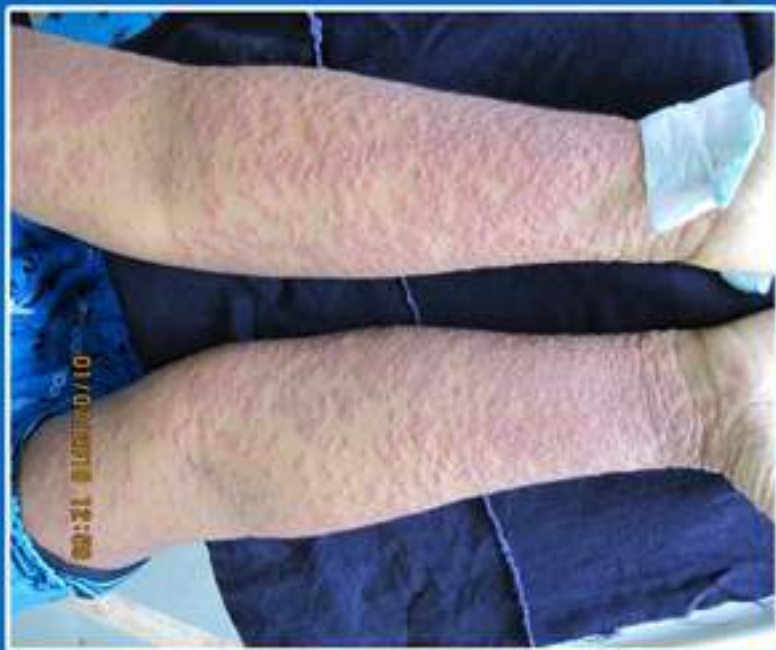

## *Post Treatment*

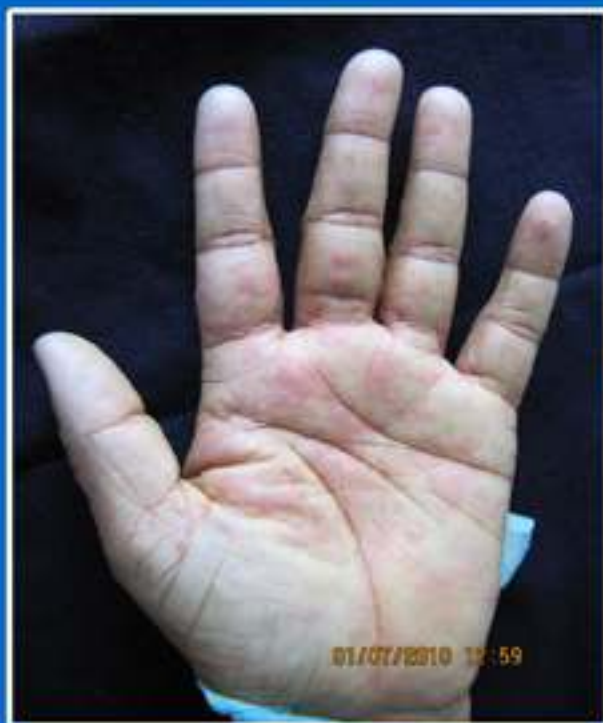
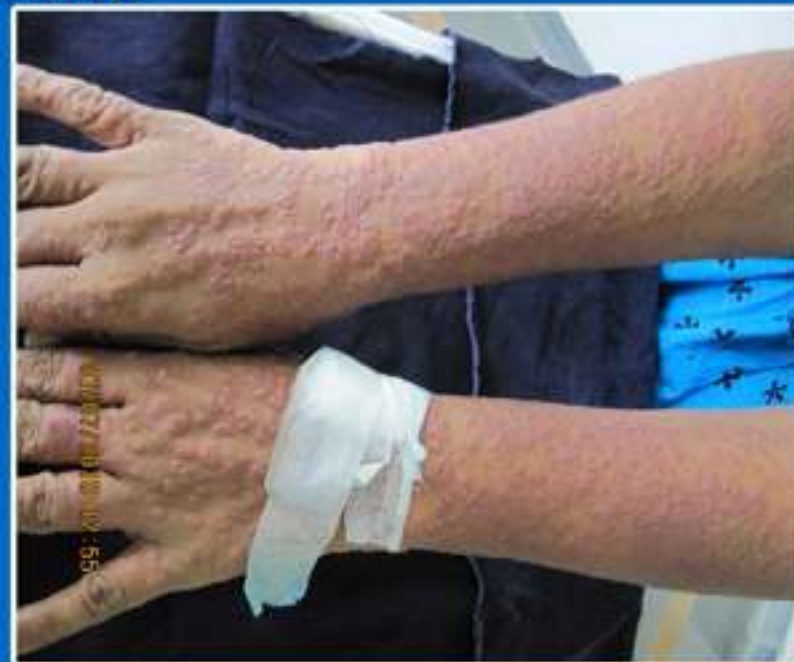
# *Erythema Multiforme*

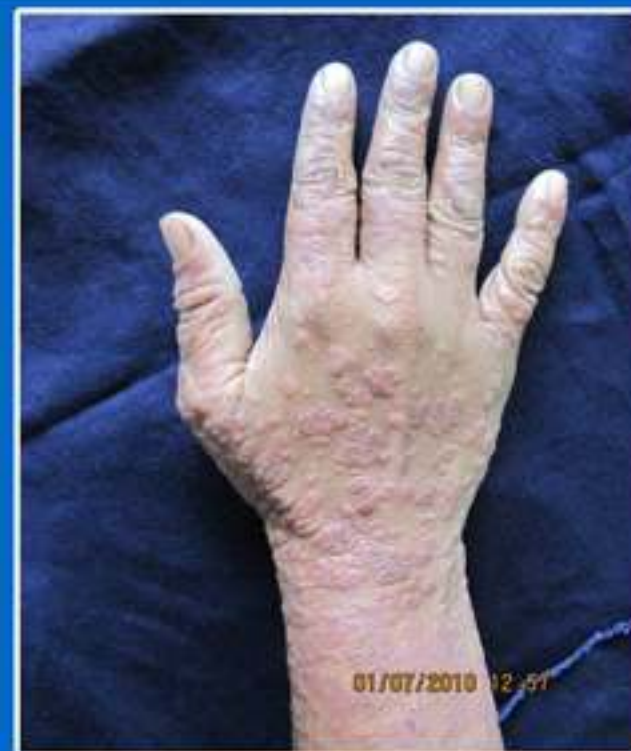*- Drug Induced*



*Maculopapular  
Rashes*

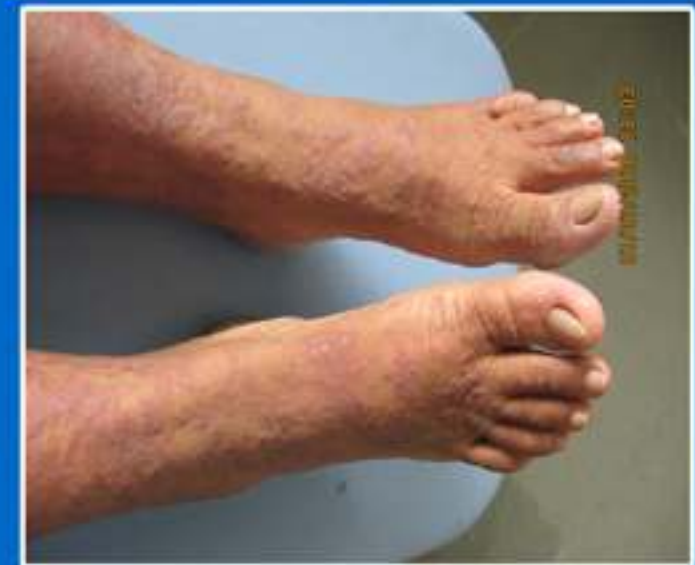
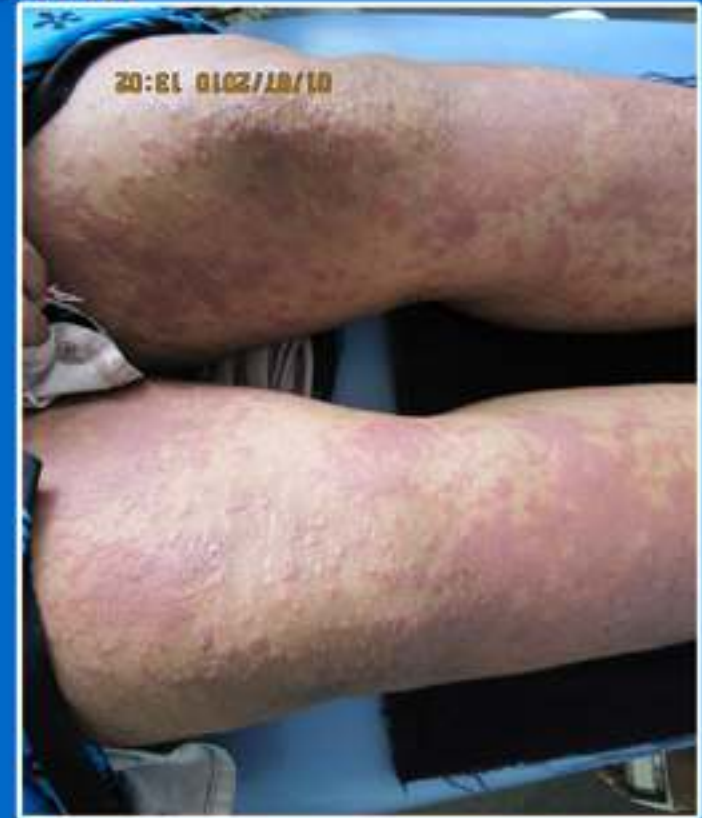
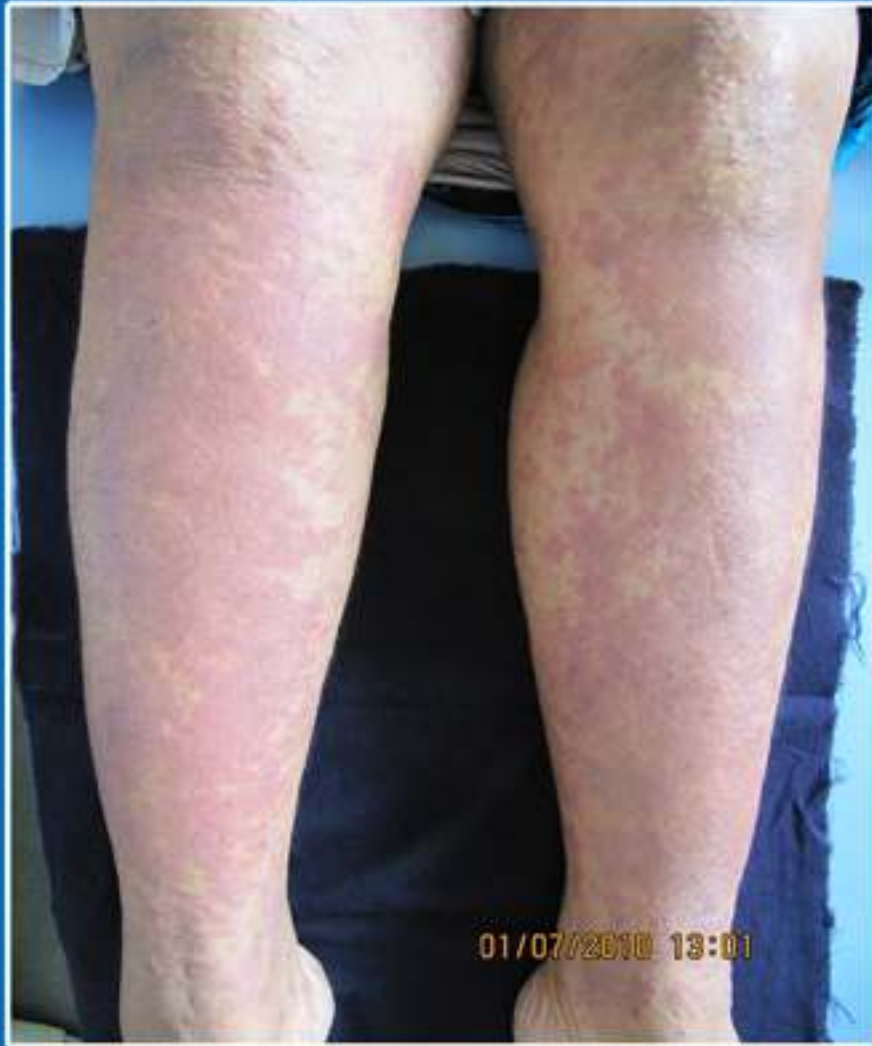*Target Iris  
Lesions*



# *Erythema Multiforme*

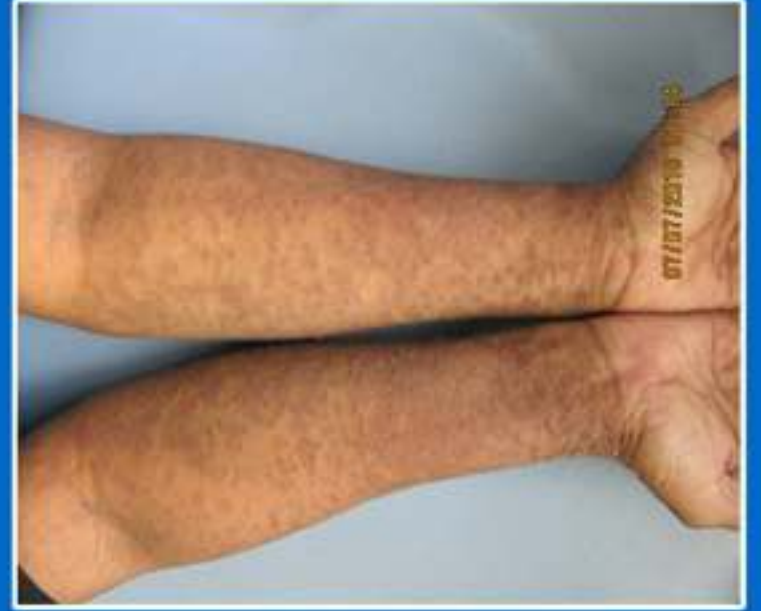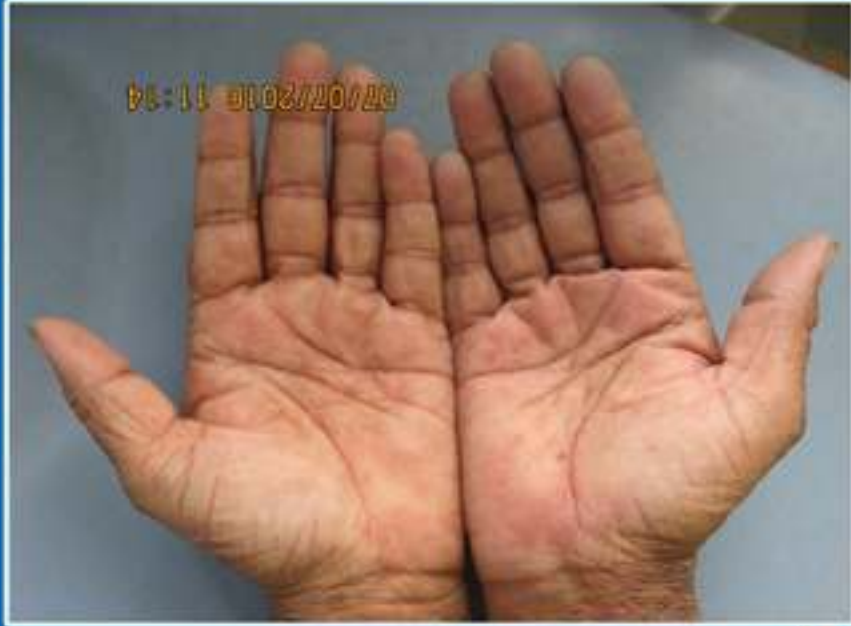*- Drug Induced*



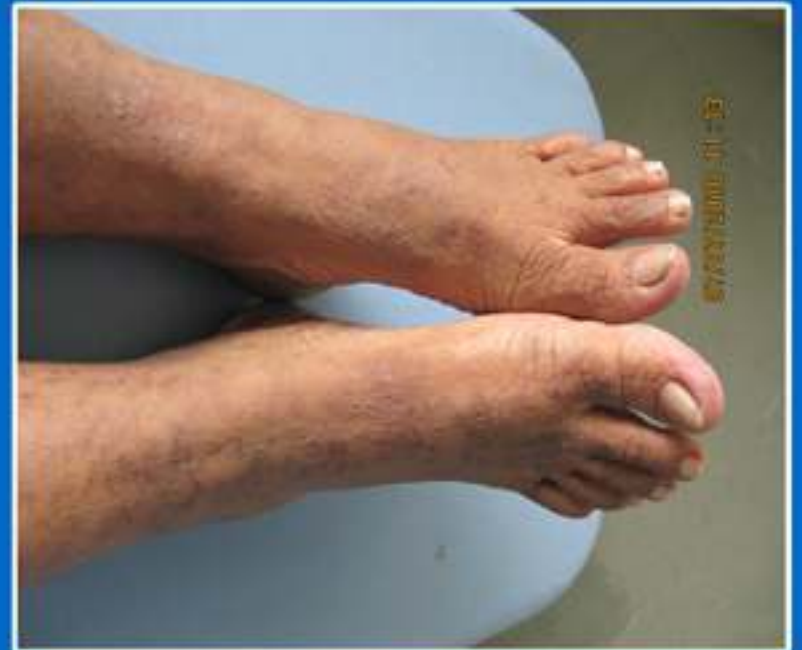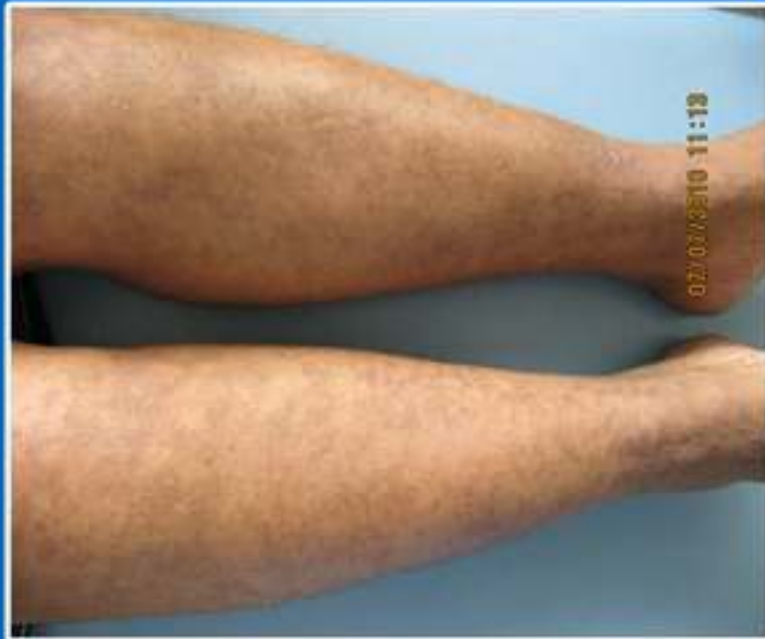*Maculopapular  
Rashes*

# *Erythema Multiforme*

*- Drug Induced*

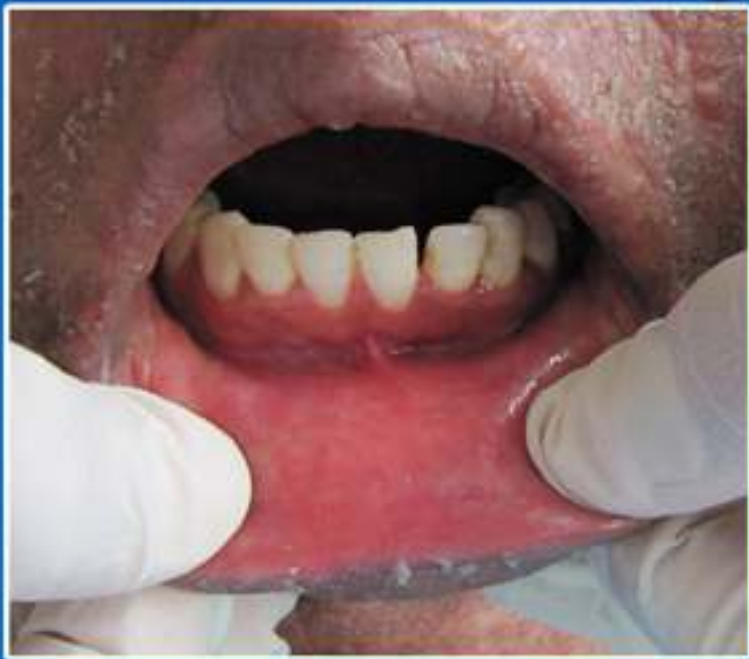

## *Post Treatment*

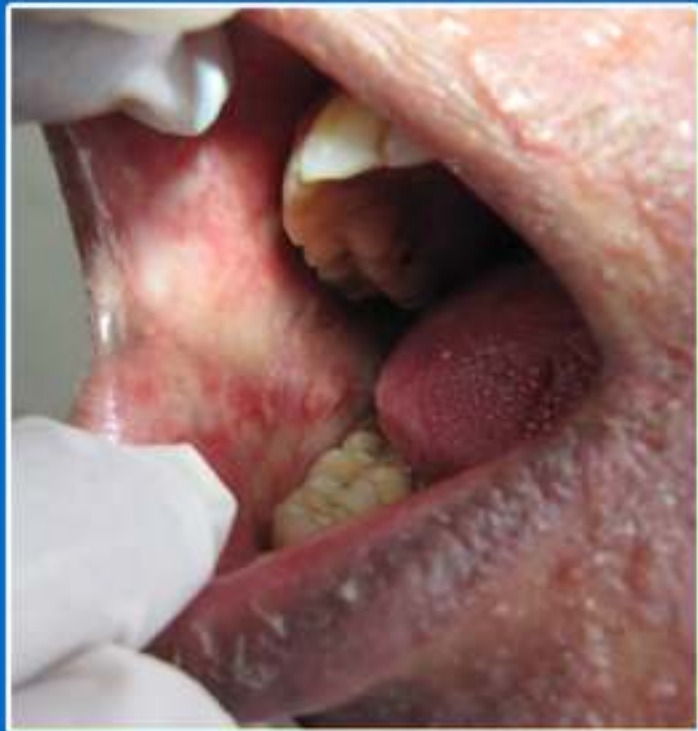
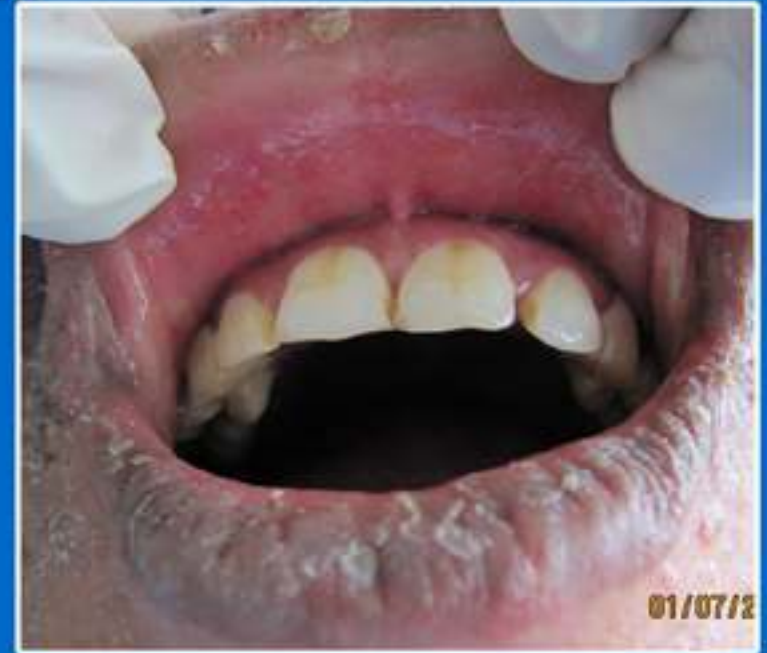
# *Erythema Multiforme*

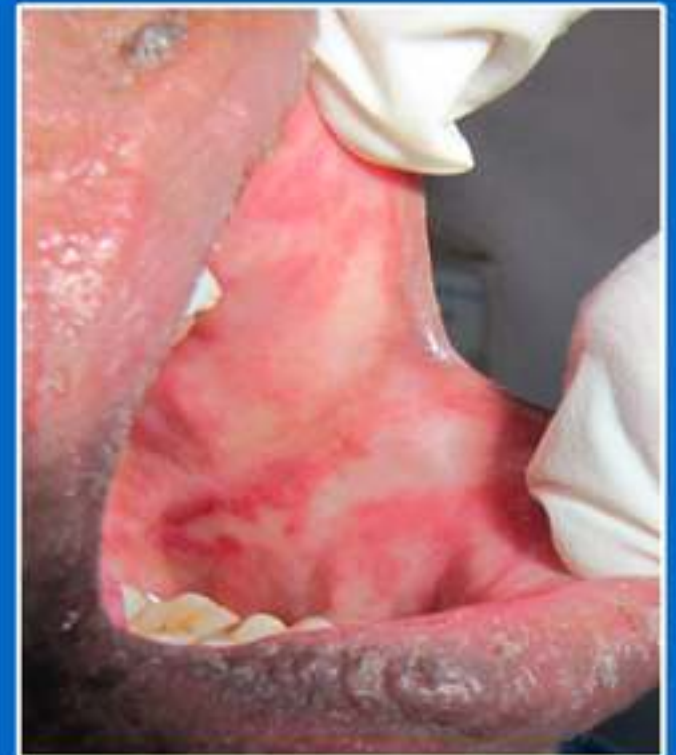*- Drug Induced*



*Labial Mucosa*



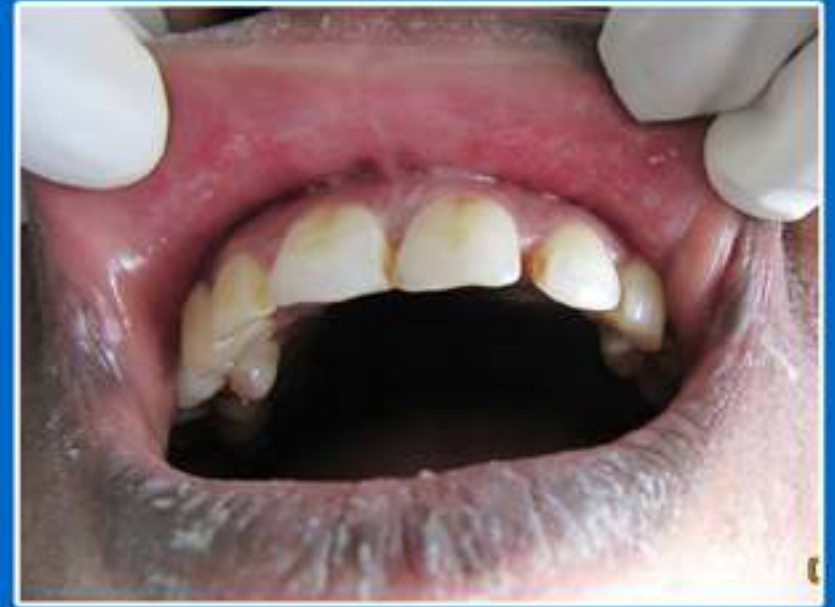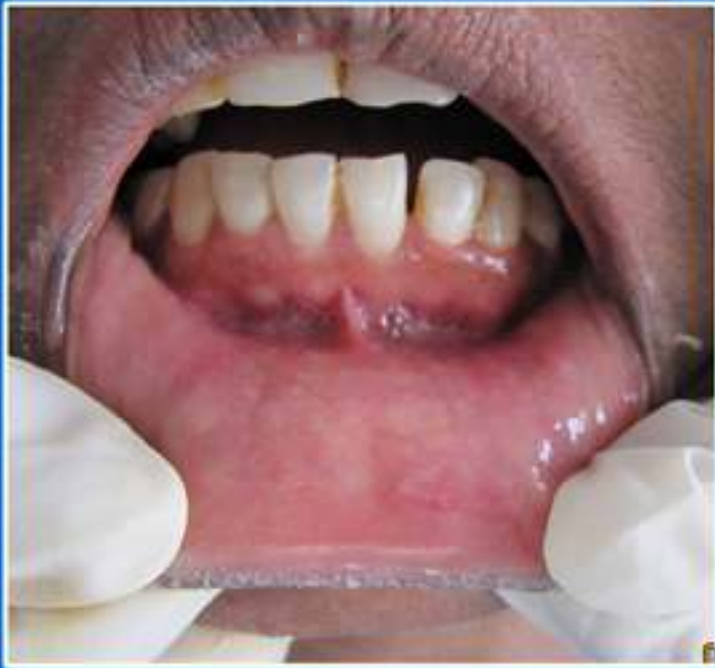*Buccal Mucosa*



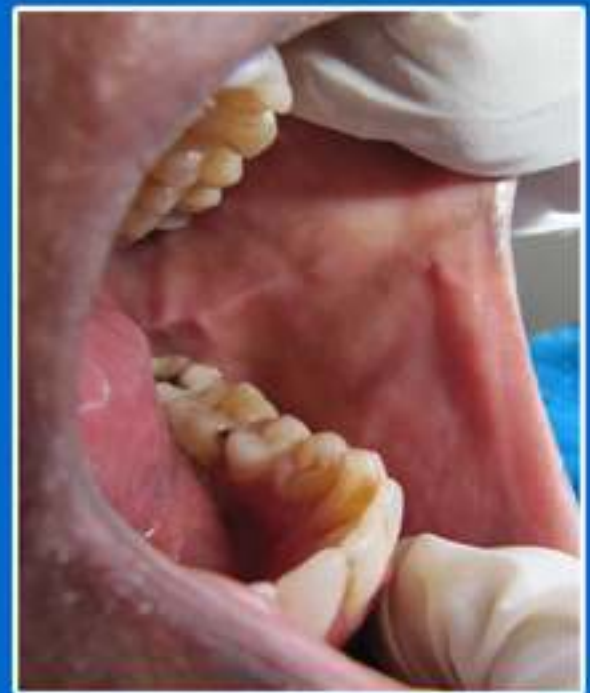
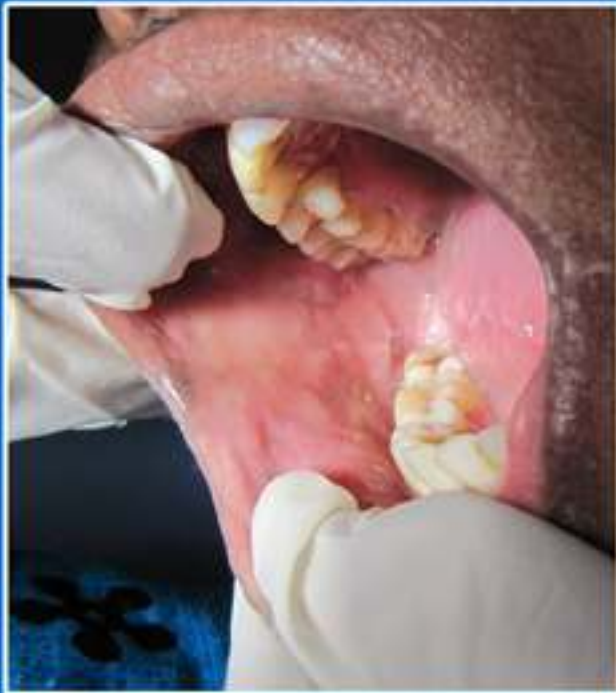
# *Erythema Multiforme*

*- Drug Induced*

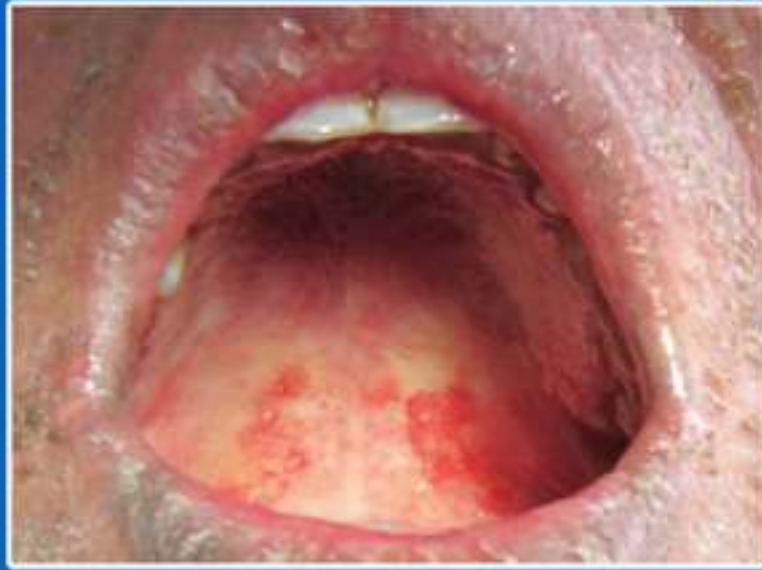

*Post Treatment*

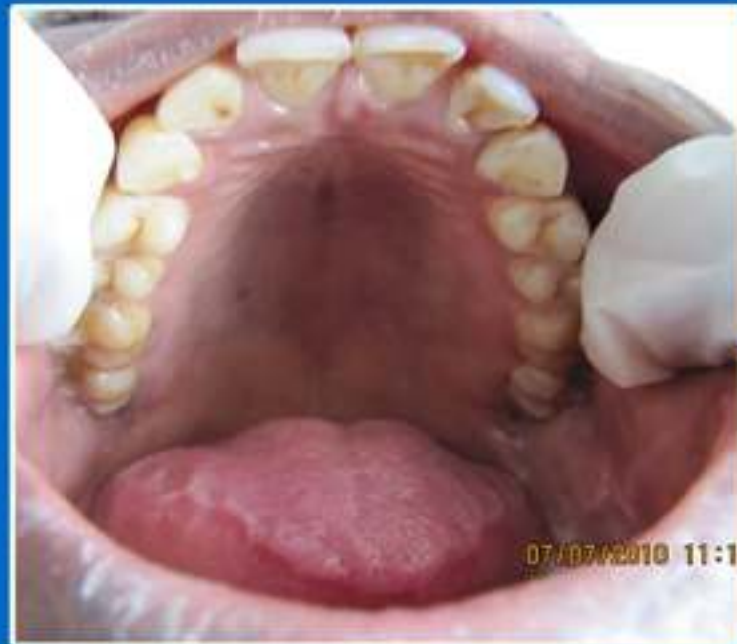
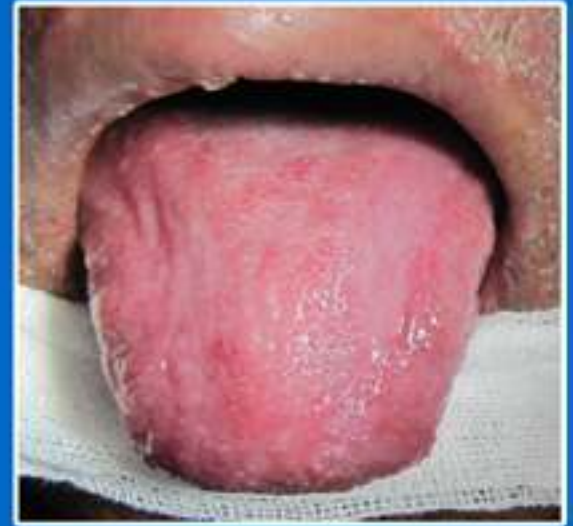
# *Erythema Multiforme*

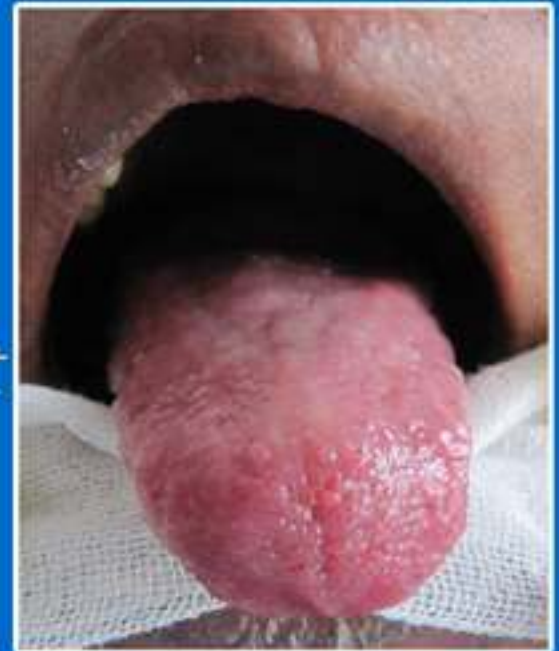*- Drug Induced*



*Pre Treatment*



*Post Treatment*



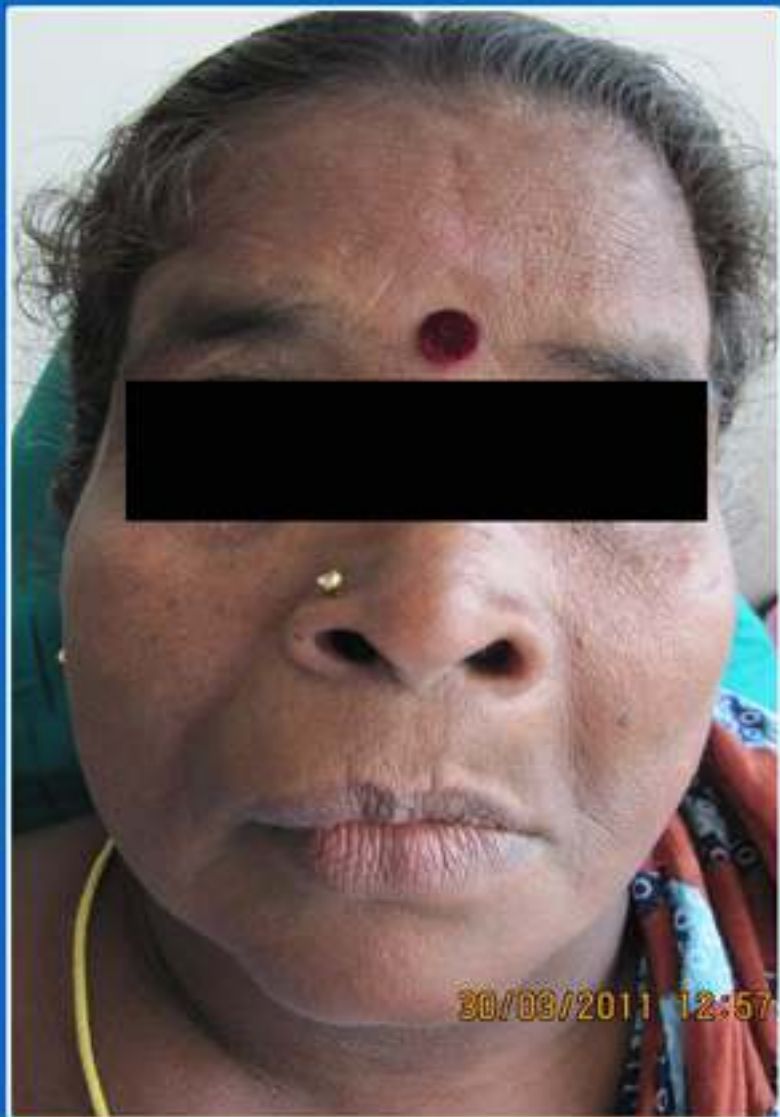*Patient Name: Mrs.Sagunthala*

*Age/sex: 55y/F*

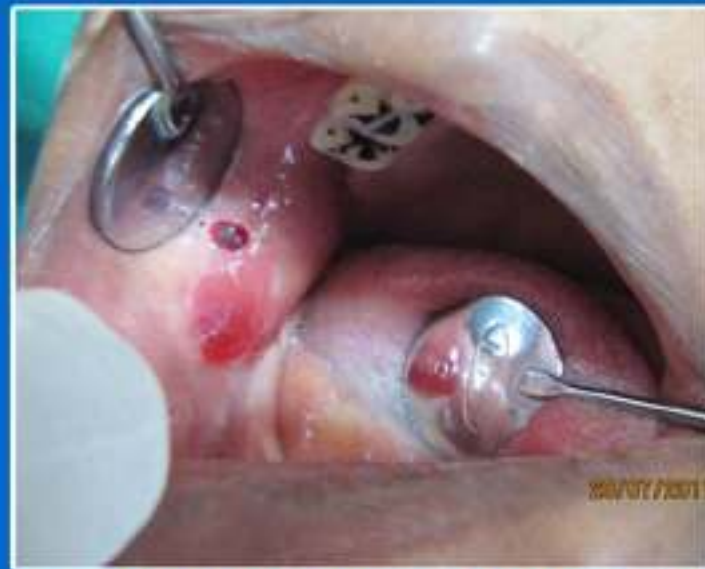*OP No: 201103300033*

*Diagnosis: Angina Hemorrhagica Bullosa*

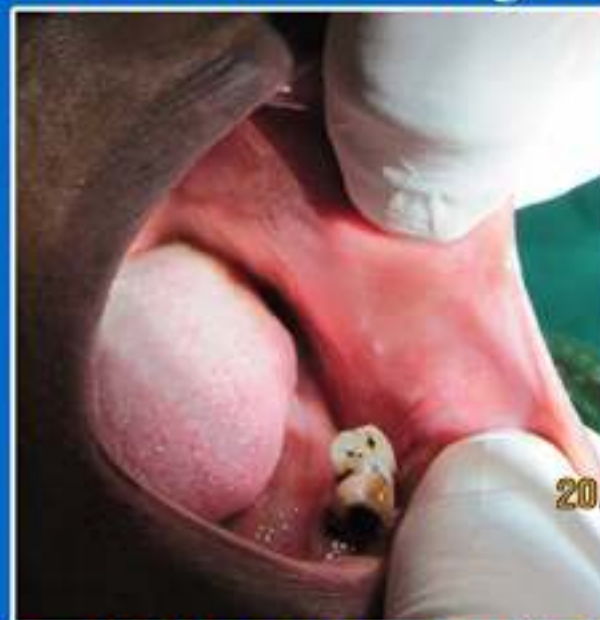# *Angina Hemorrhagica Bullosa*



*Profile*

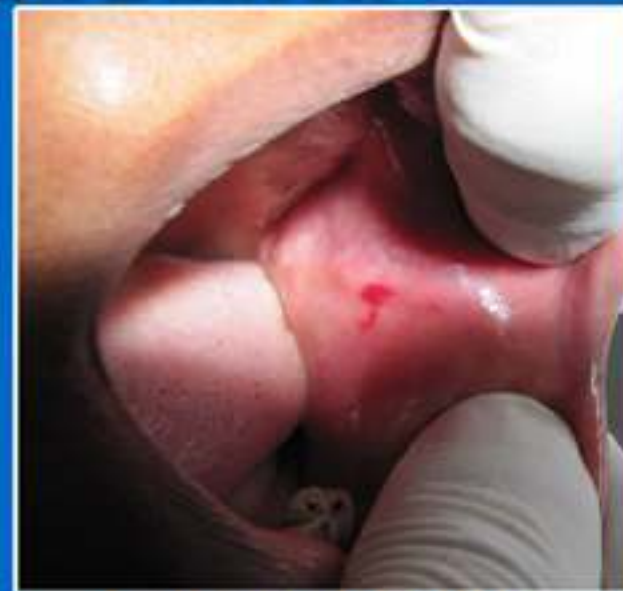
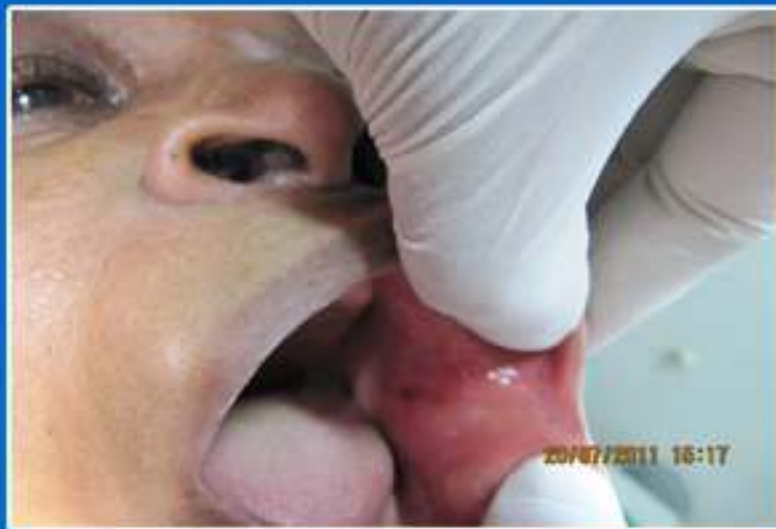
*Buccal Mucosa - Right Side*

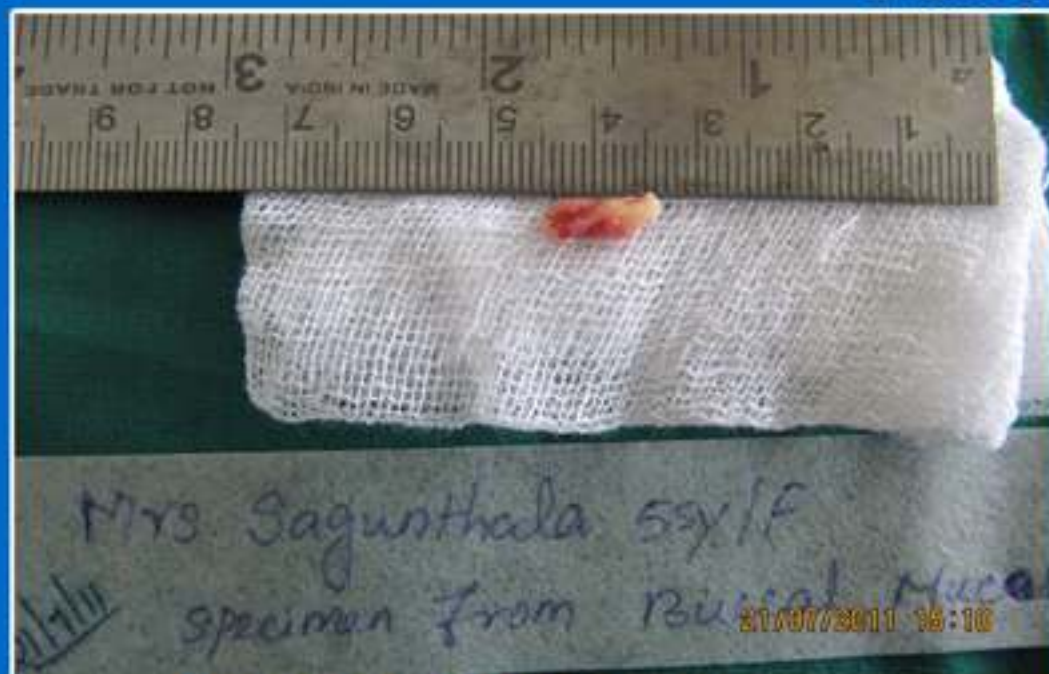

*Buccal Mucosa - Left Side*

# Angina Hemorrhagica Bullosa



*Induced Bulla*



Mrs. Sagunthala 55y/F  
specimen from Buccal Mucosa

*Surgical Specimen*

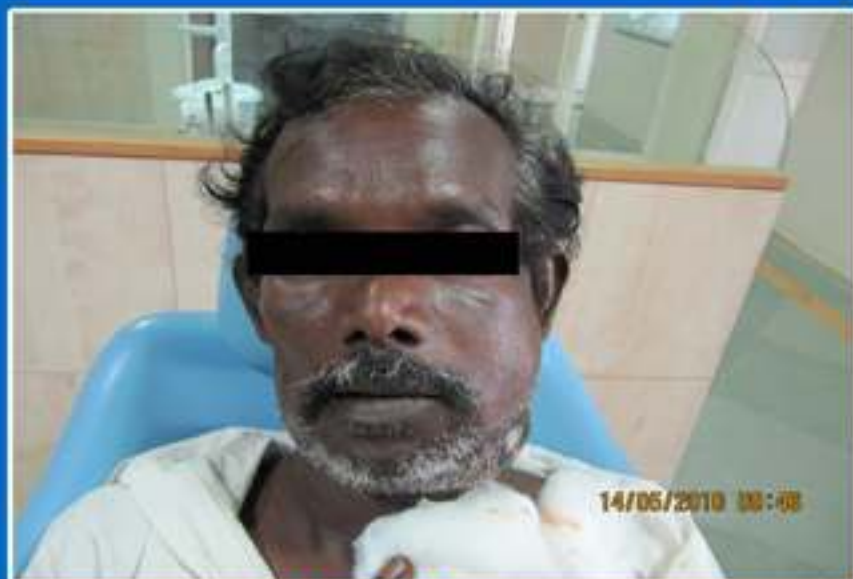*Patient Name: Mr.Karunakaran*

*Age/sex: 47y/M*

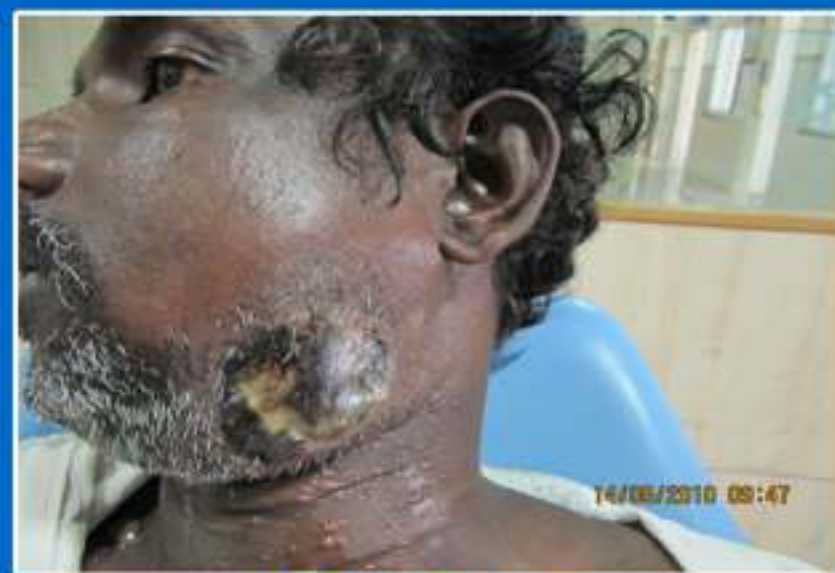*OP No: 201005140001*

*Diagnosis: Cervicofacial Actinomycosis*

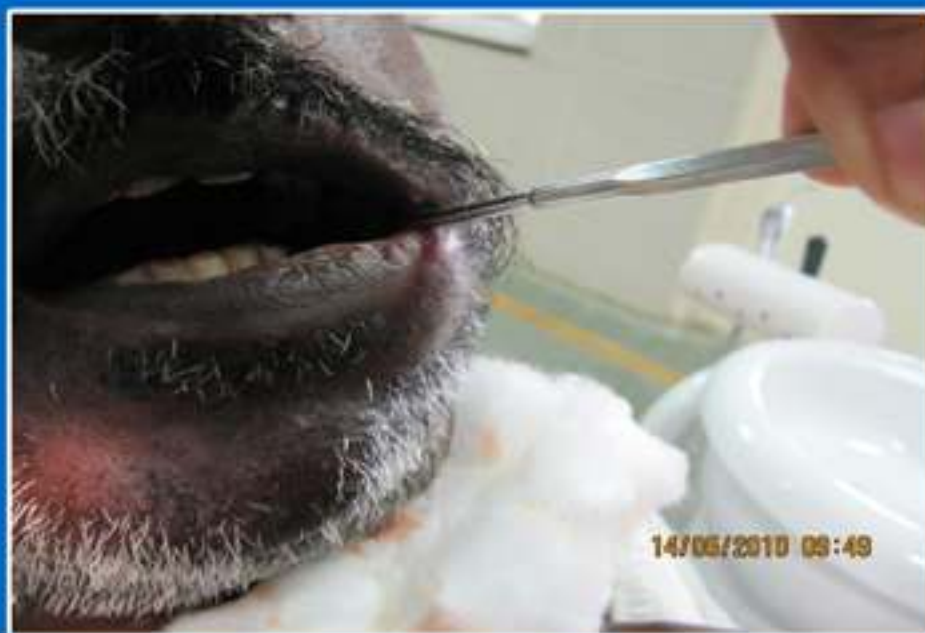# *Cervicofacial Actinomycosis*



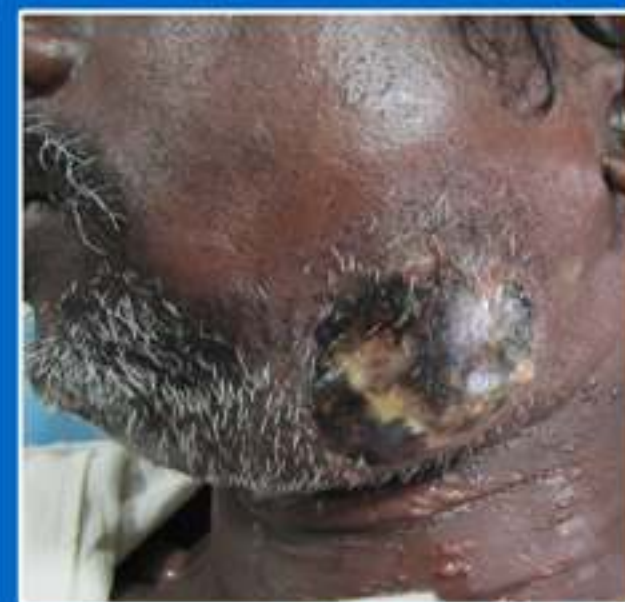*Profile*



*Extra Oral*



*Intra Oral-Restricted Mouth Opening*



*Ulceration with Multiple Sinus*

*Patient Name: Mrs.Rajathi*

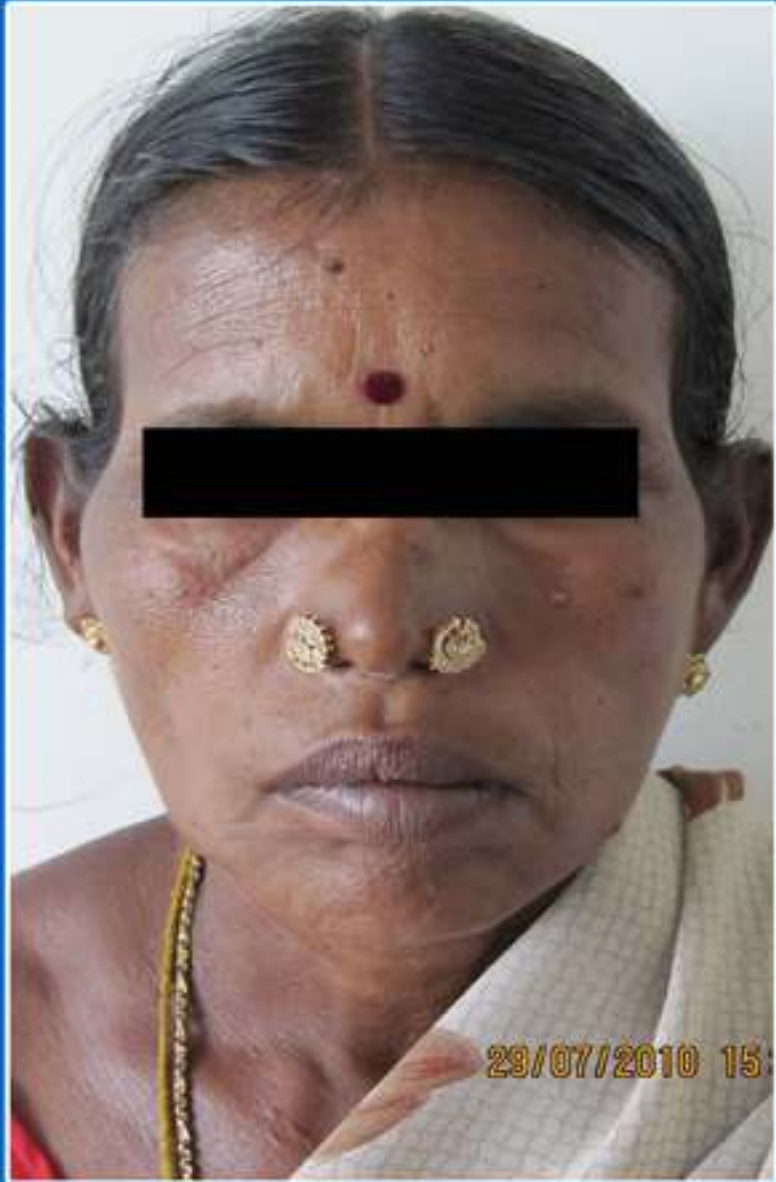*Age/sex: 42y/F*

*OP No: 201007290042*

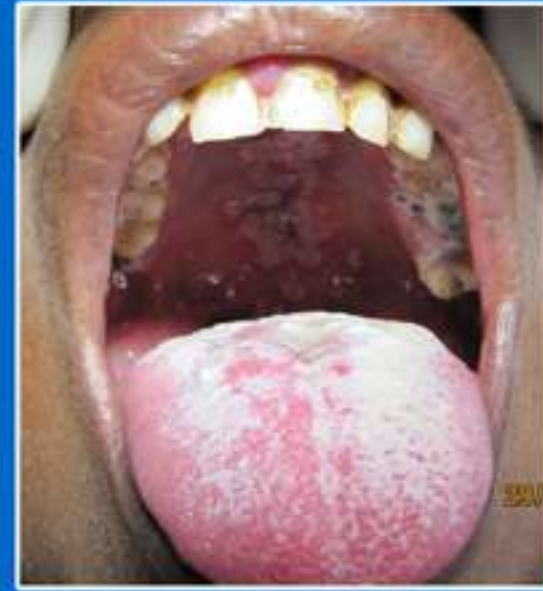*Diagnosis: Oral Candidiasis*



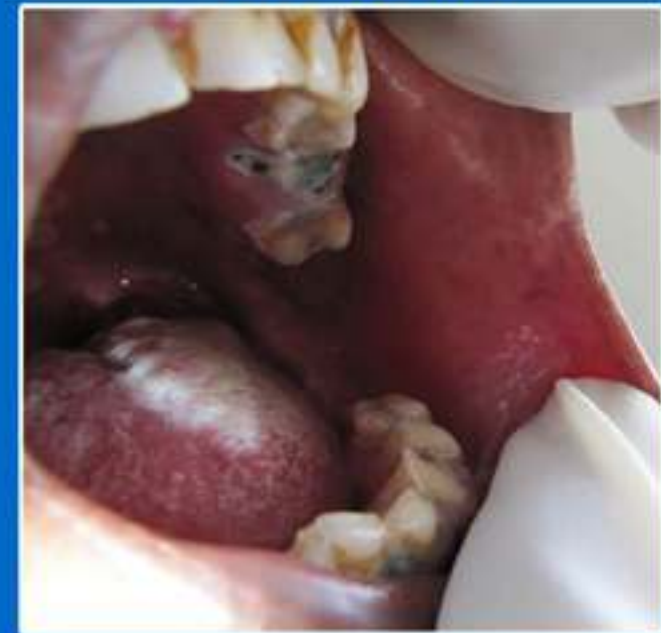# *Oral Candidiasis*



*Profile*

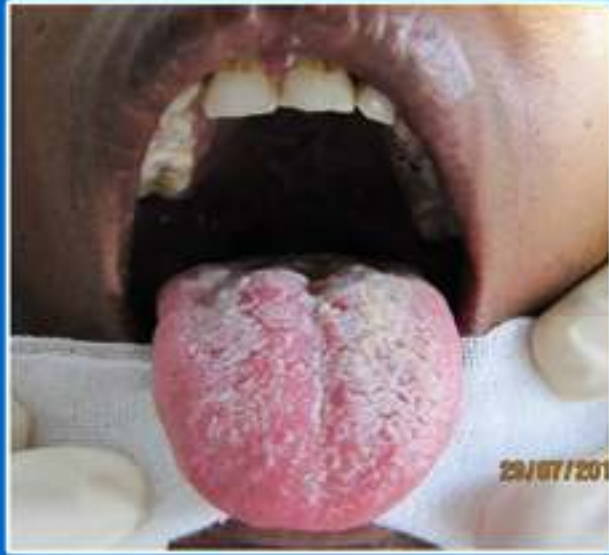

*Intra Oral*

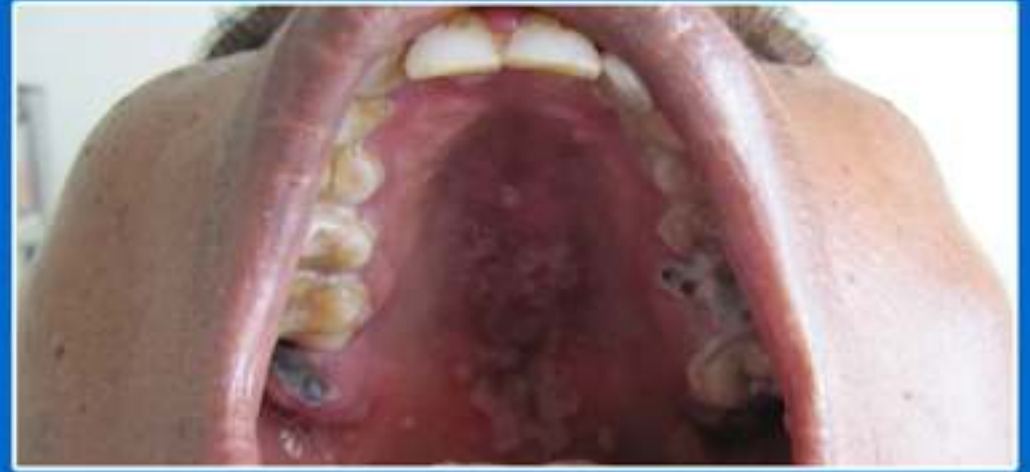

*Buccal Mucosa*

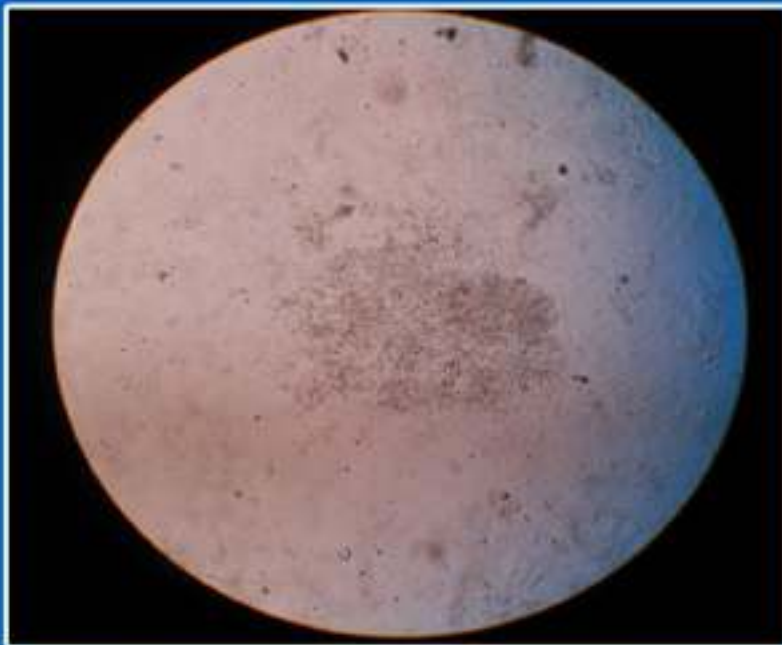
# *Oral Candidiasis*



*Tongue*



*Palate*



*Cytology*

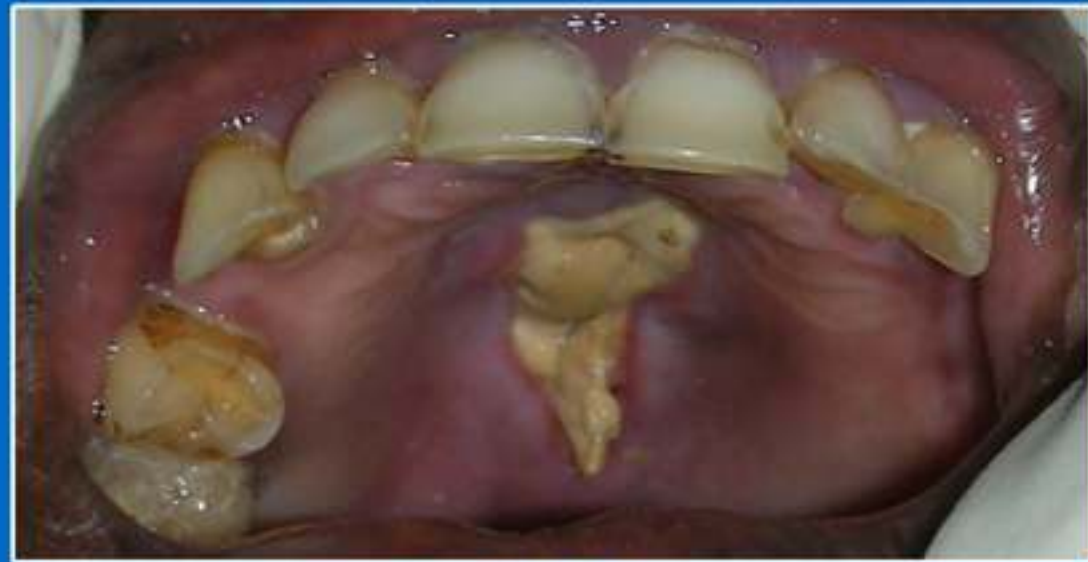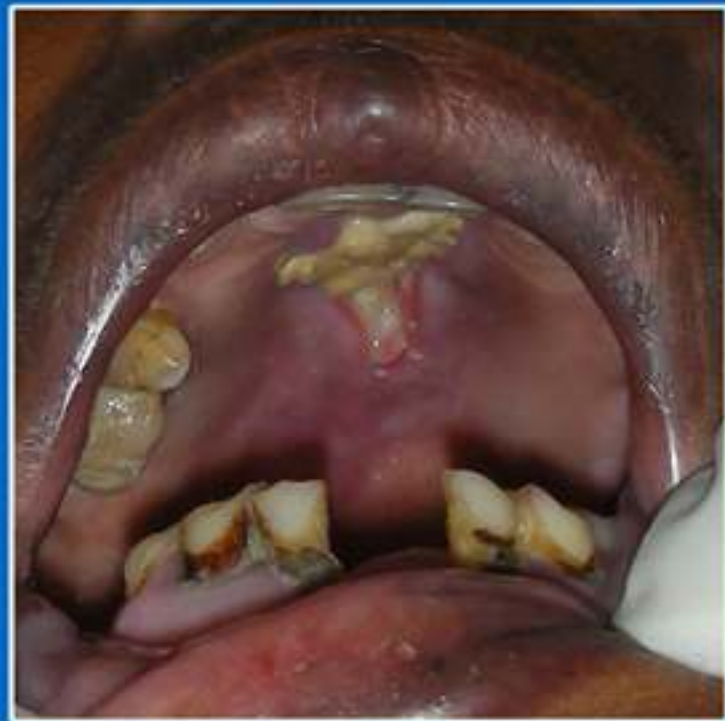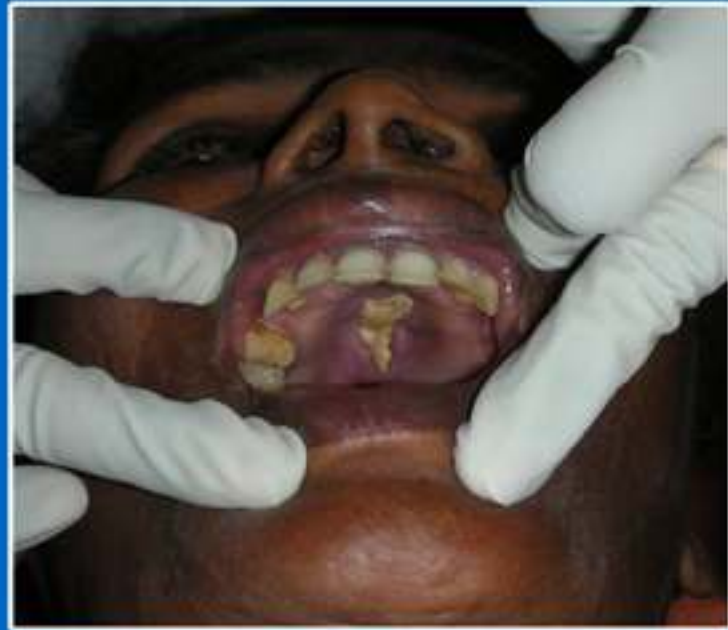*Patient Name: Mrs.Kanchana*

*Age/sex: 58y/F*

*OP No: 201003310042*

*Diagnosis: Mucormycosis of Palate*

# *Mucormycosis of Palate*



*Palatal Ulcer*

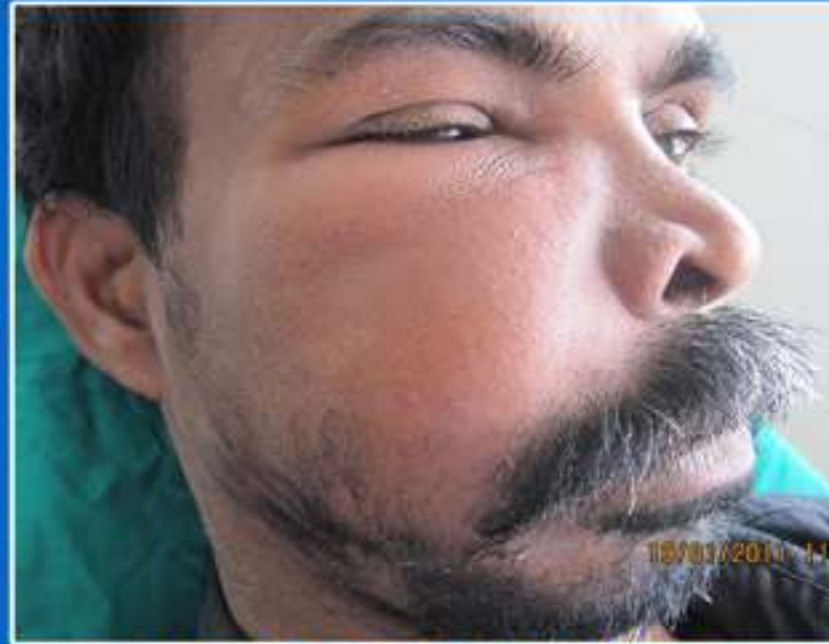*Patient Name: Mr. Anandhan*

*Age/sex: 41y/M*

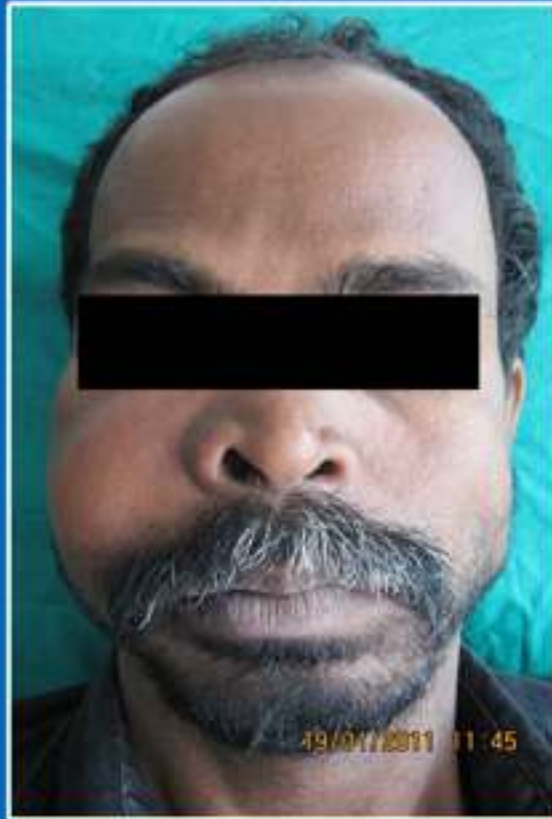*OP No: 201101180032*

*Diagnosis: Infected Radicular Cyst*

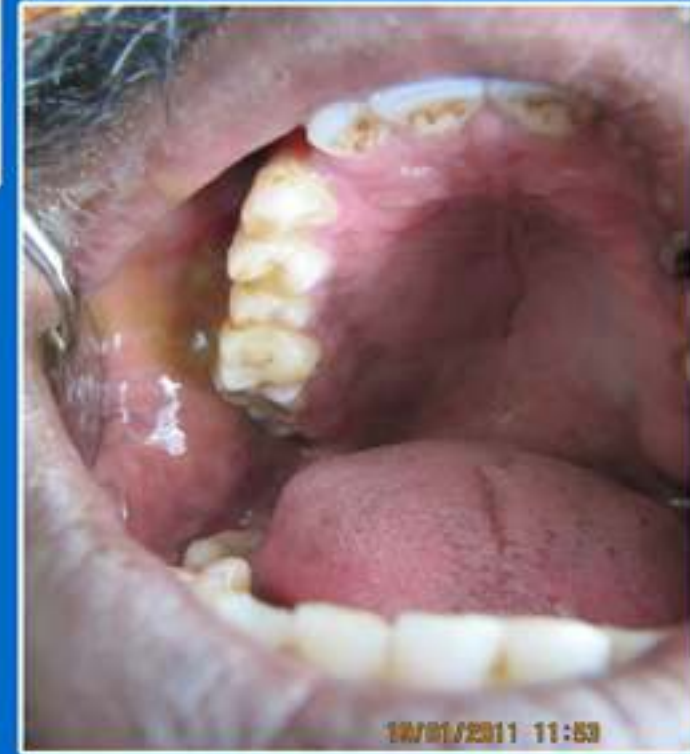# *Infected Radicular Cyst*



*Extra Oral Swelling*

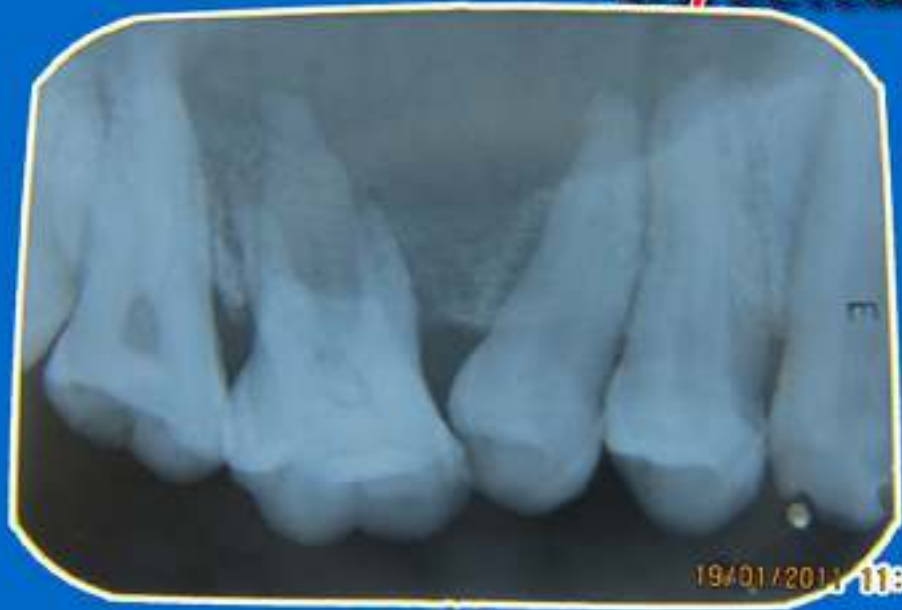

*Profile*

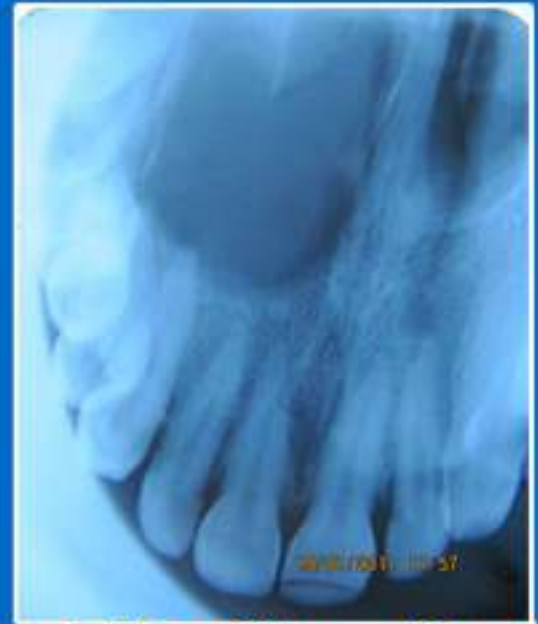


*Intra Oral - Pus Discharge*

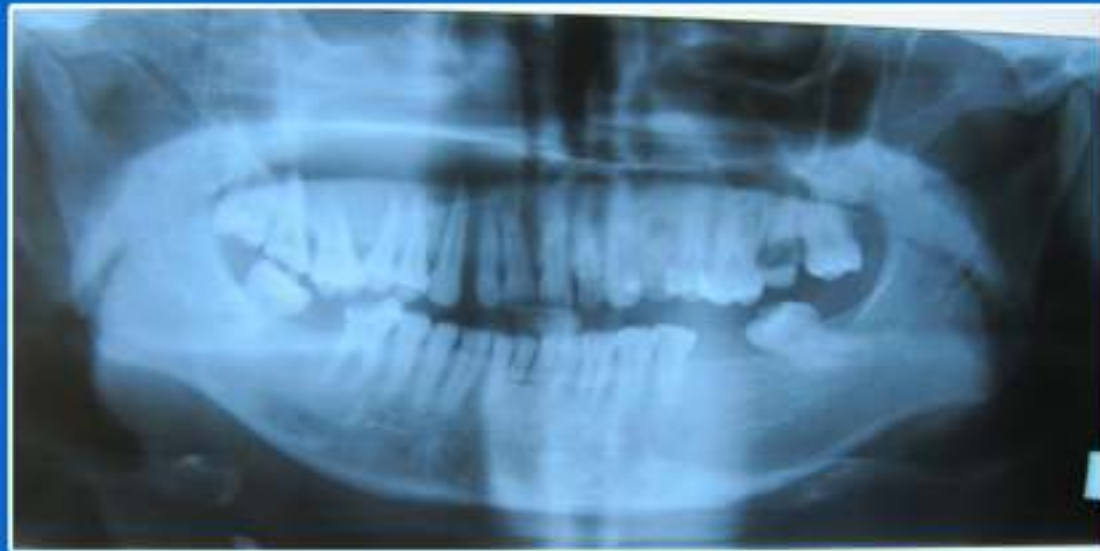# *Infected Radicular Cyst*



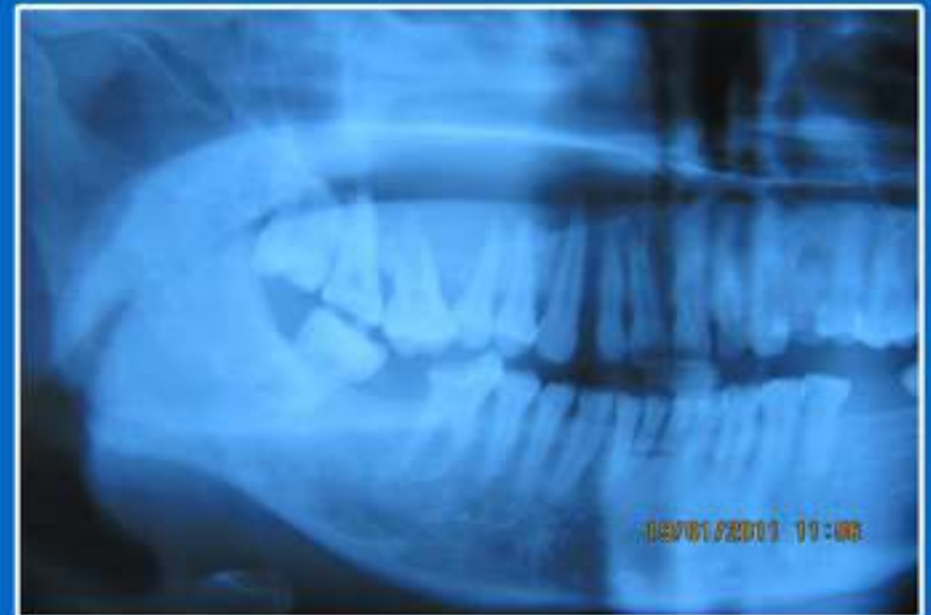*IOPA*



*Lateral Maxillary Occlusal*



*Orthopantomogram*



*OPT - Right Side*

*Patient Name: Mr.Praveen Kumar*

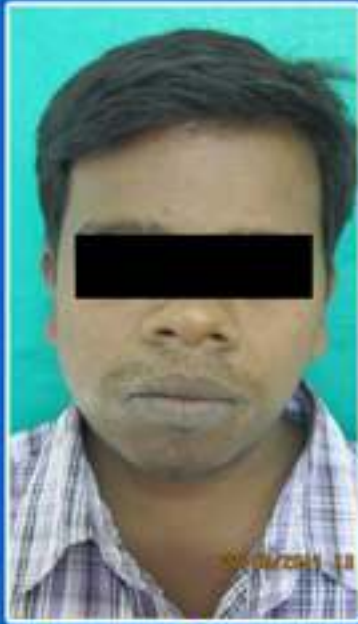*Age/sex: 22y/M*

*OP No: 201106270021*

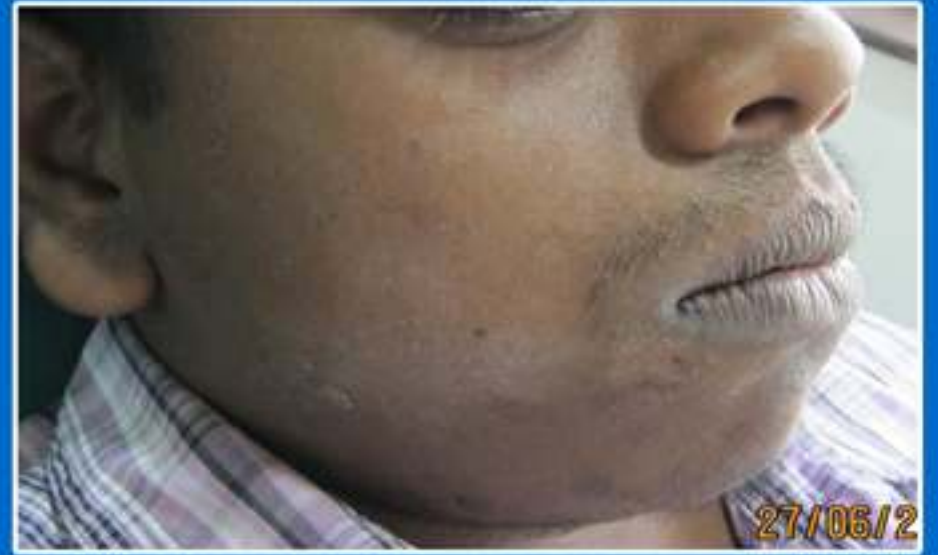*Diagnosis: Dentigerous Cyst*



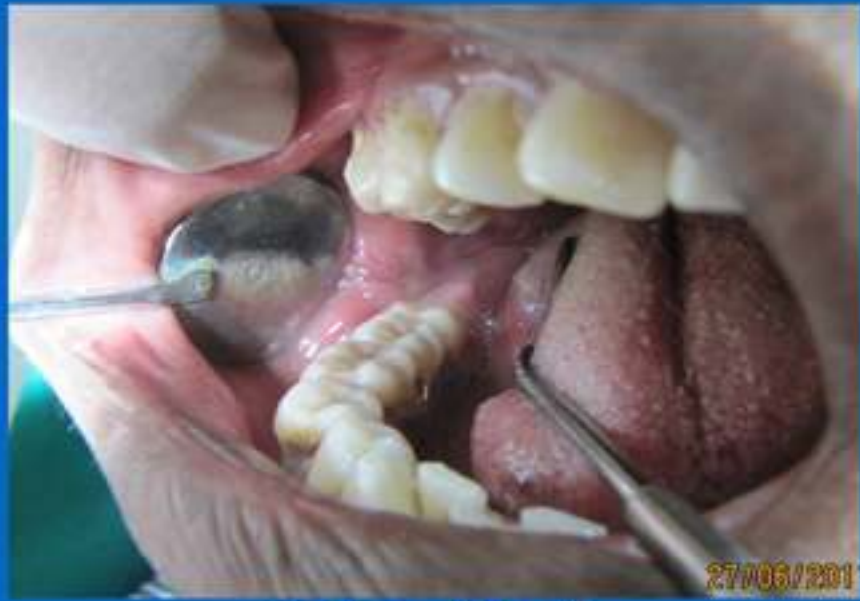# *Dentigerous Cyst*



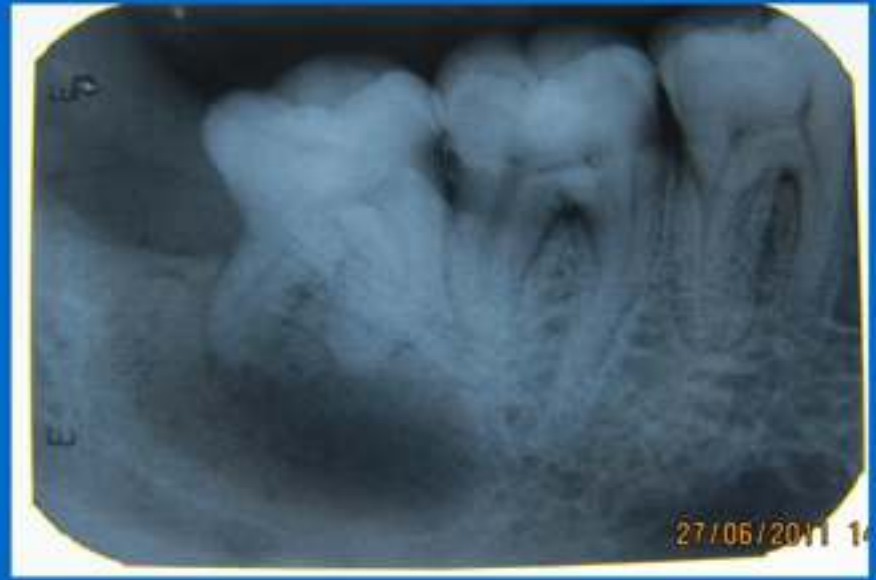*Profile*



*Extra Oral Swelling*

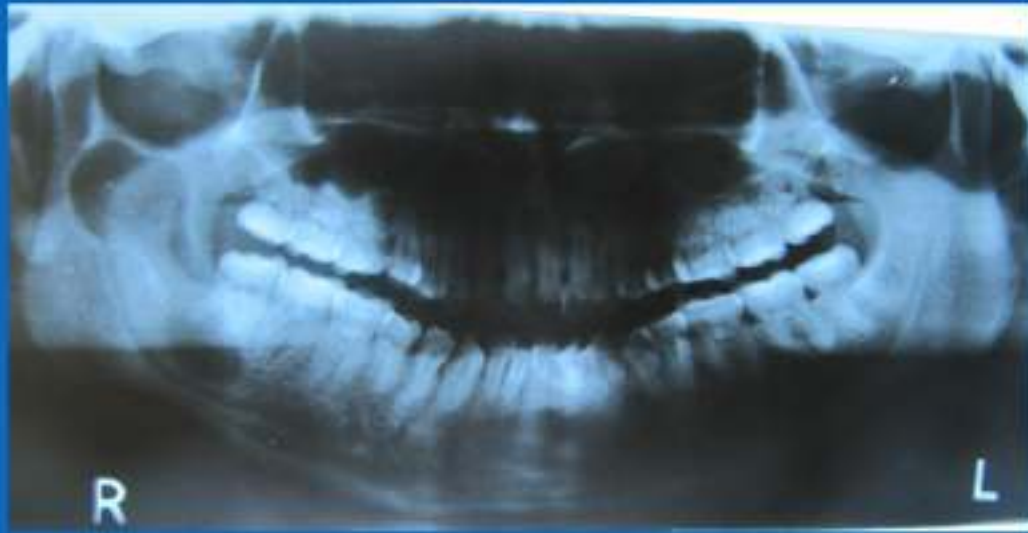


*Intra Oral*

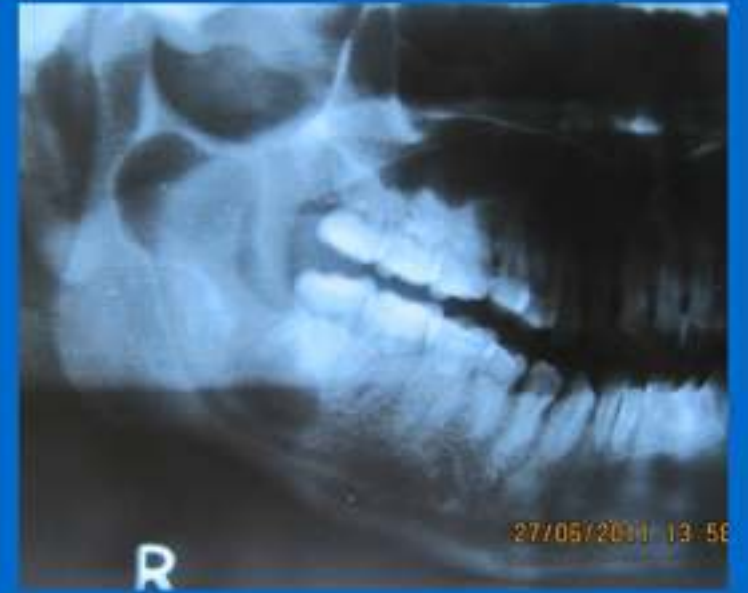

*IOPA*

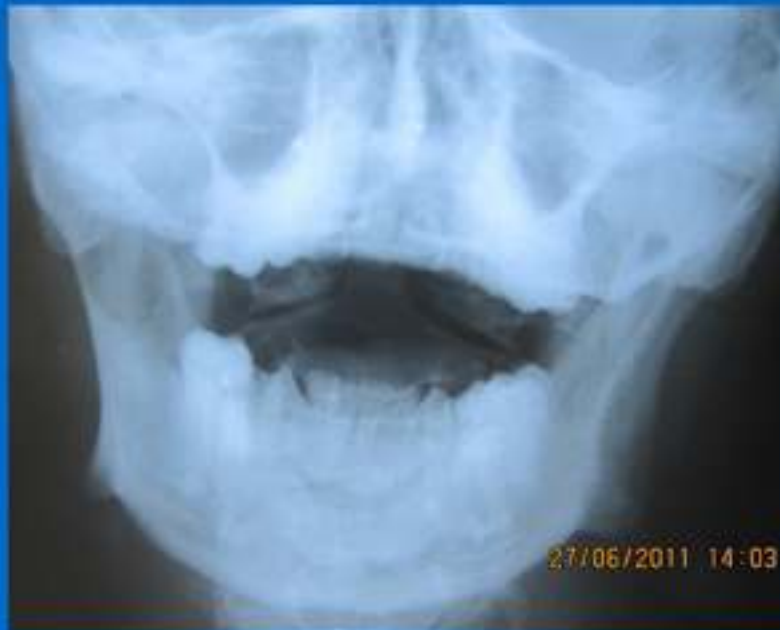# *Dentigerous Cyst*



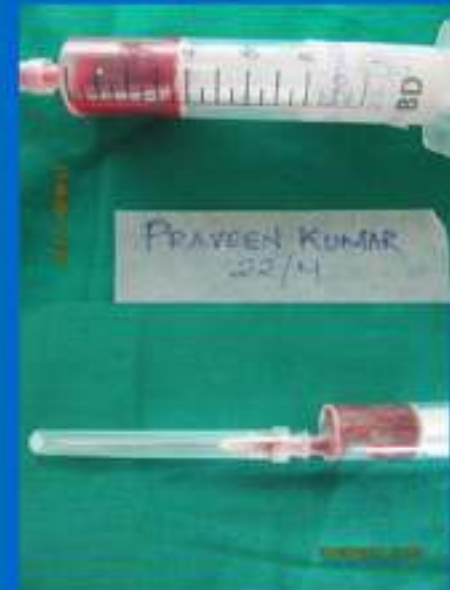*Orthopantomogram*



*Right Side*



*PA Mandible*



*Aspirate*

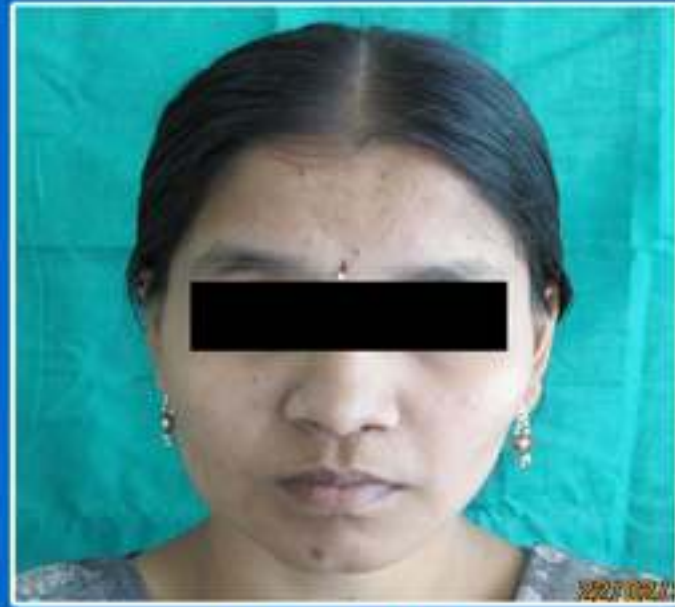*Patient Name: Ms.Rekha*

*Age/sex: 21y/F*

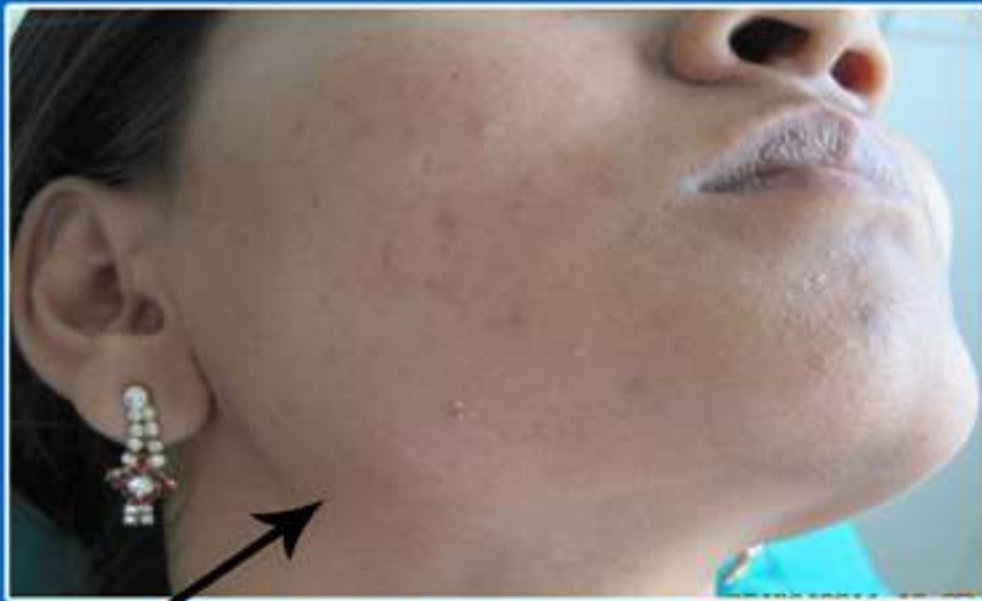*OP No: 201102220010*

*Diagnosis: Garre's Osteomyelitis*

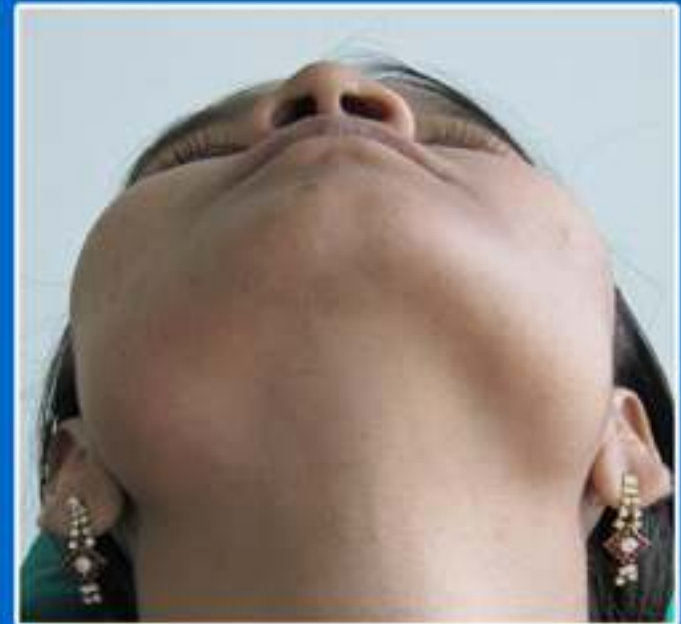# *Garre's Osteomyelitis*



*Profile*

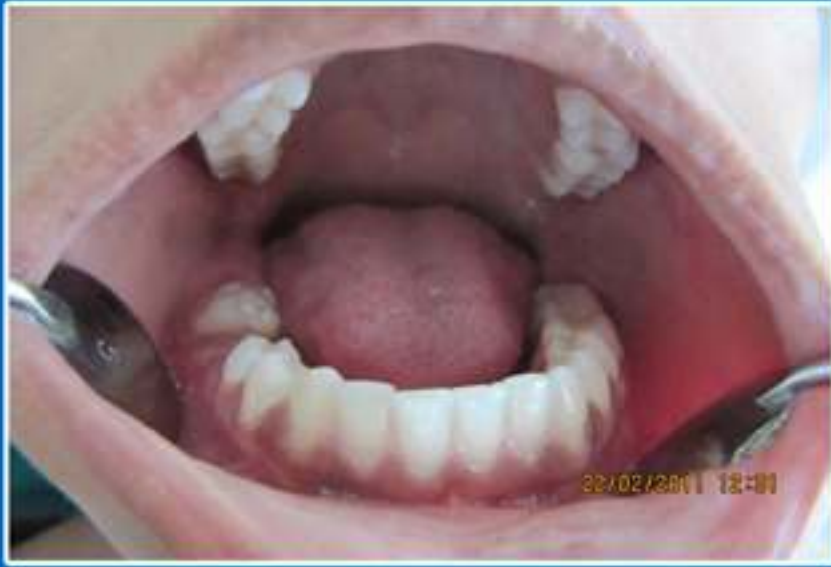

*Extra Oral Swelling*

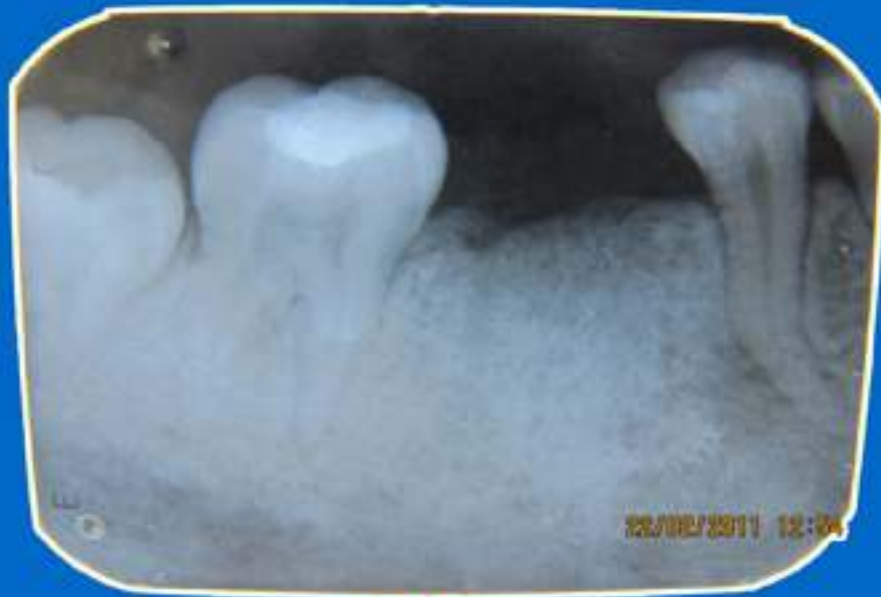
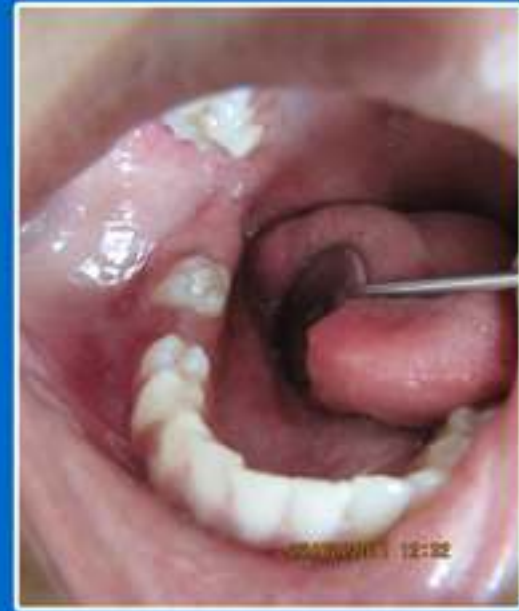
*Facial Asymmetry*

# *Garre's Osteomyelitis*

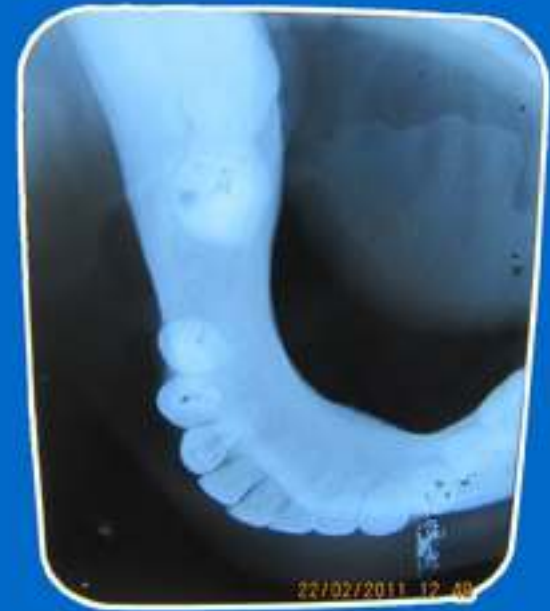

*Intra Oral*



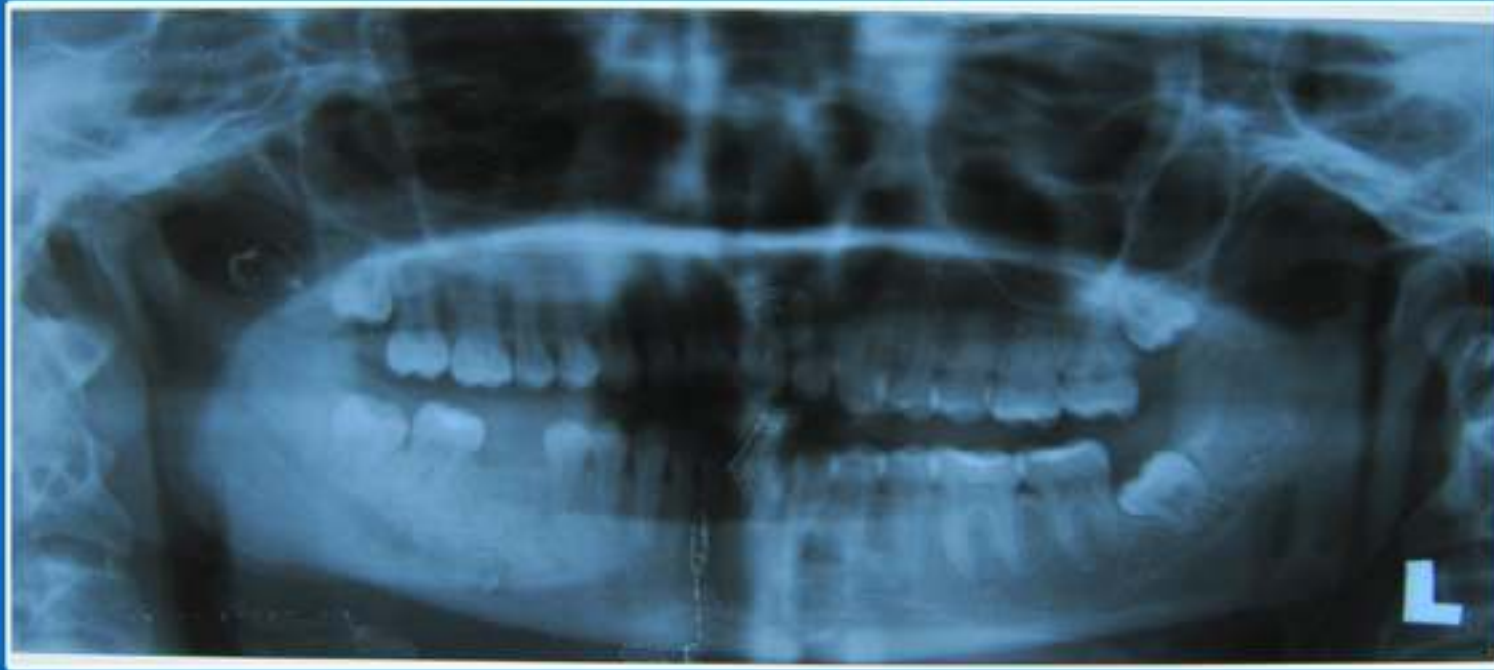
*IOPA*

*Intra Oral  
Radiographs*

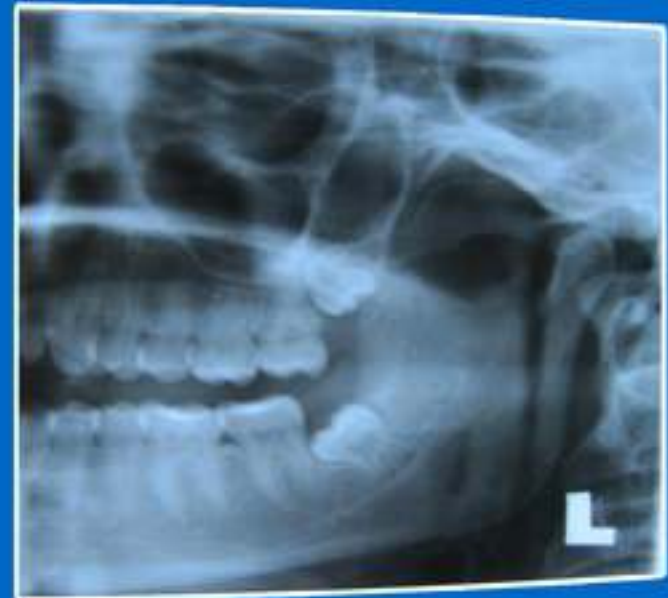
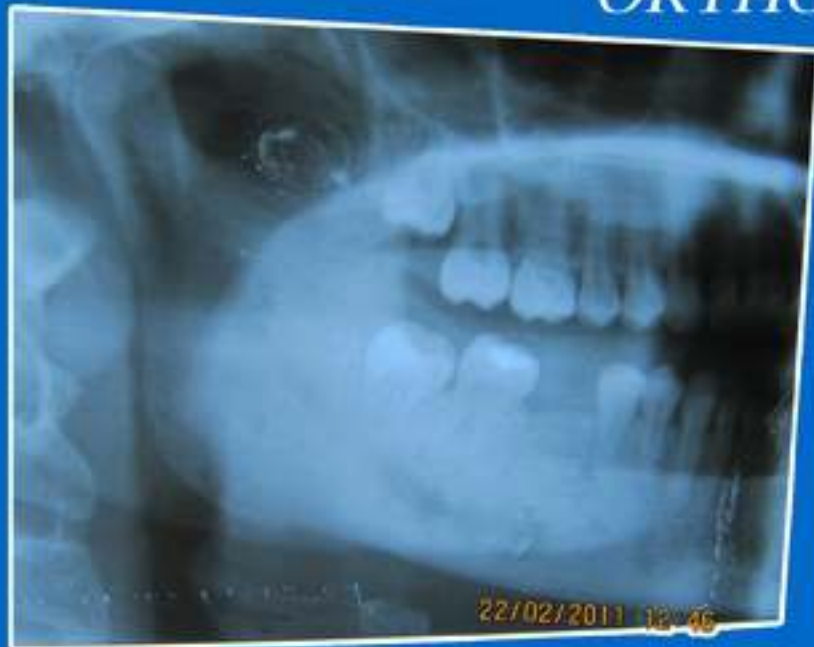
*Right Lateral Mandibular Occlusal*

# *Garre's Osteomyelitis*



*ORTHOPANTOMOGRAM*



*Patient Name: Mrs.Muniyammal*

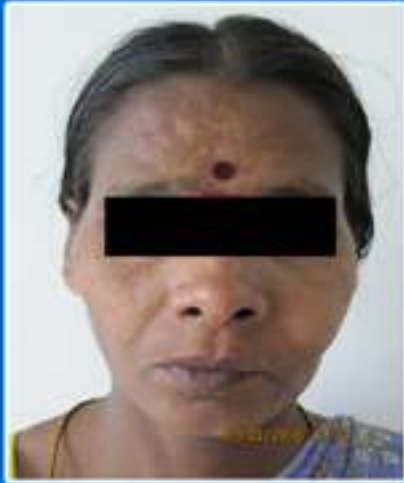*Age/sex: 40y/F*

*OP No: 201008030001*

*Diagnosis: Malignant Neoplasm  
- Left Side Maxilla (S.C.C)*

# *Malignant Neoplasm*

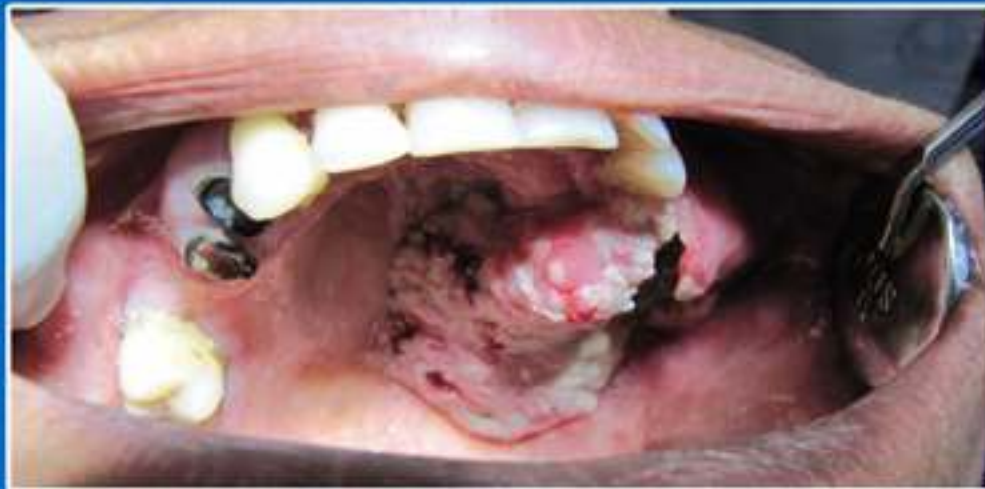## *- Left Side Maxilla (S.C.C)*



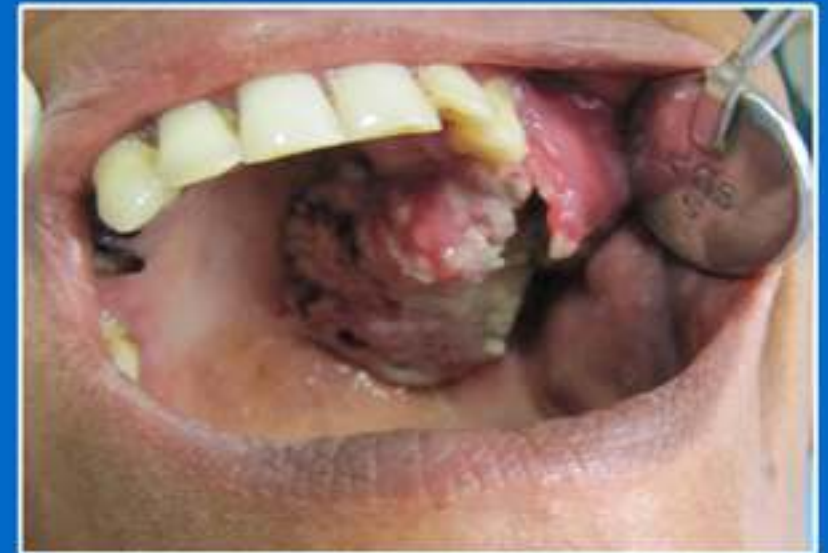*Profile*



*Extra Oral Swelling*



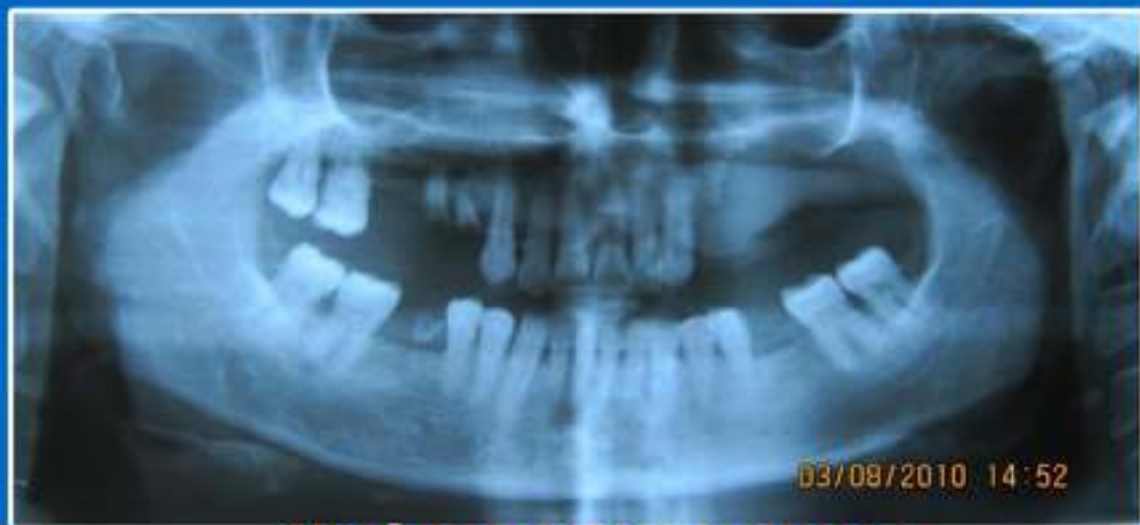*Intra Oral*



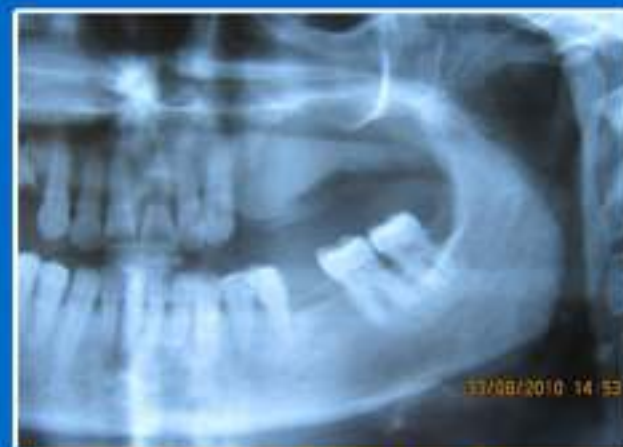*Ulceroproliferative Growth*



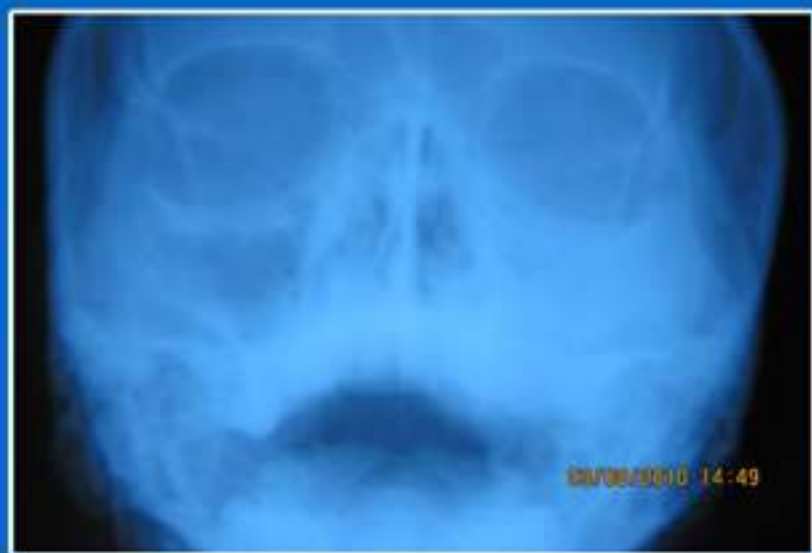## *Conventional Radiographs*



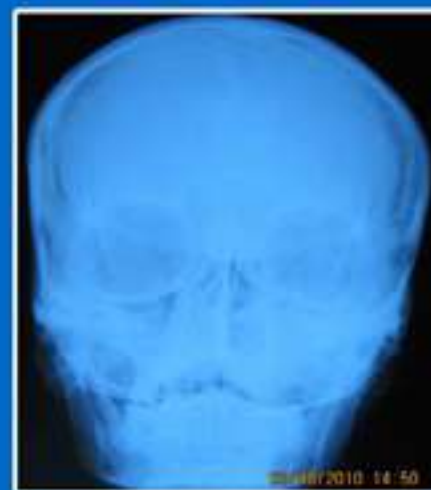*Orthopantomogram*



*OPT-Left Side*

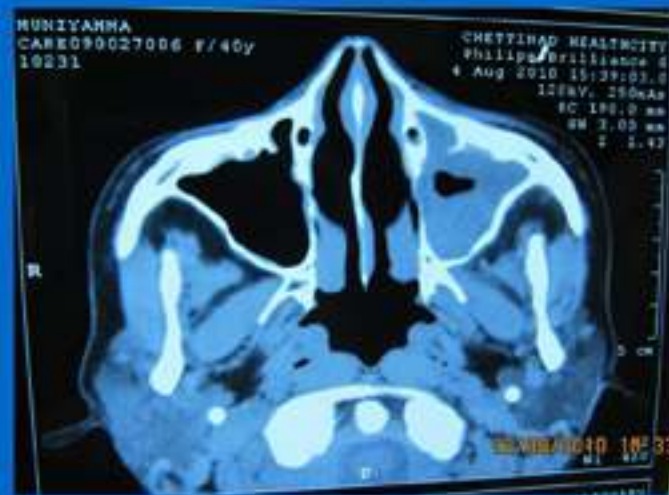
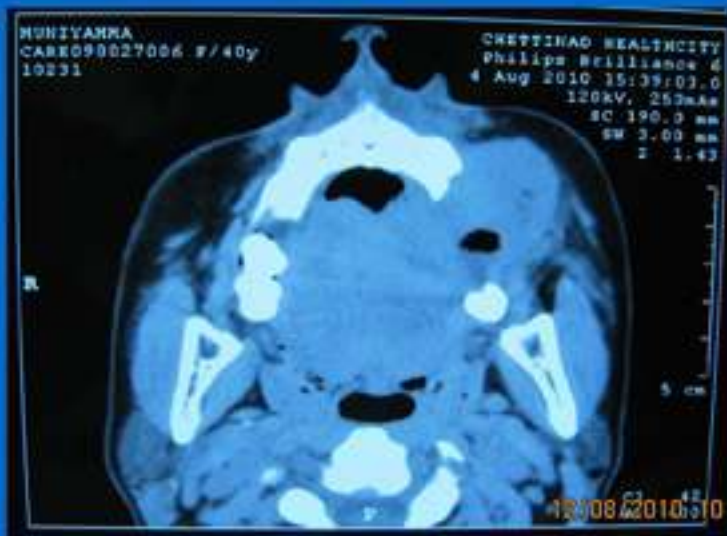
*PNS View*

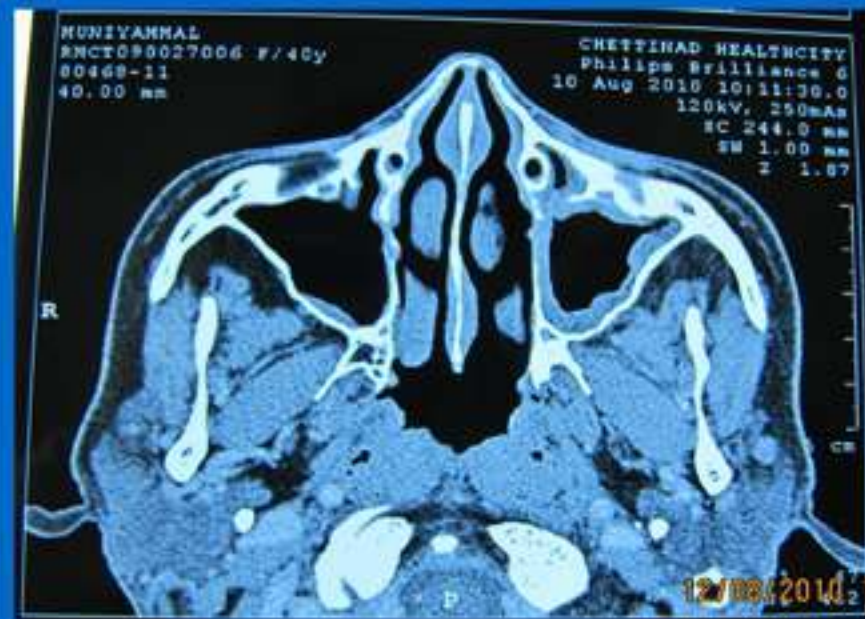
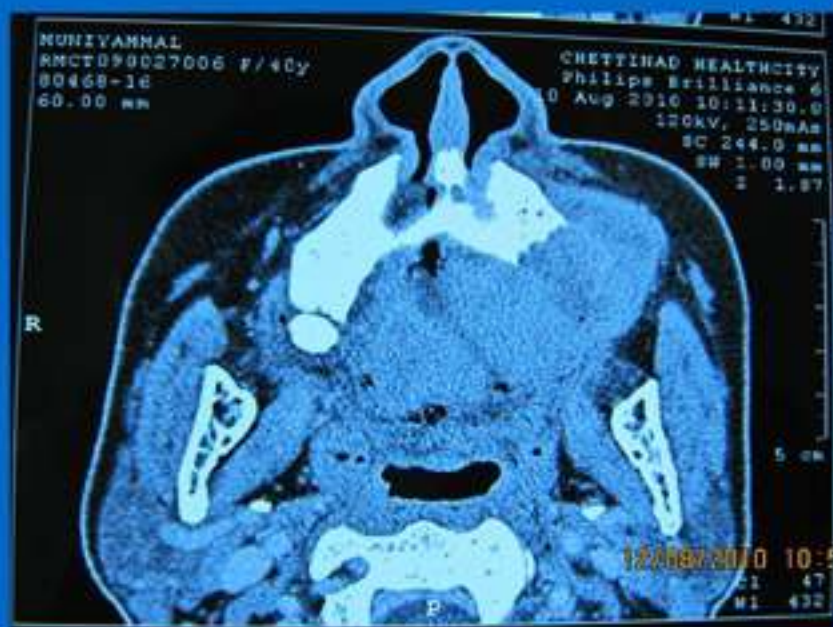
*PA - Skull*

# Computerised Tomography (CT)

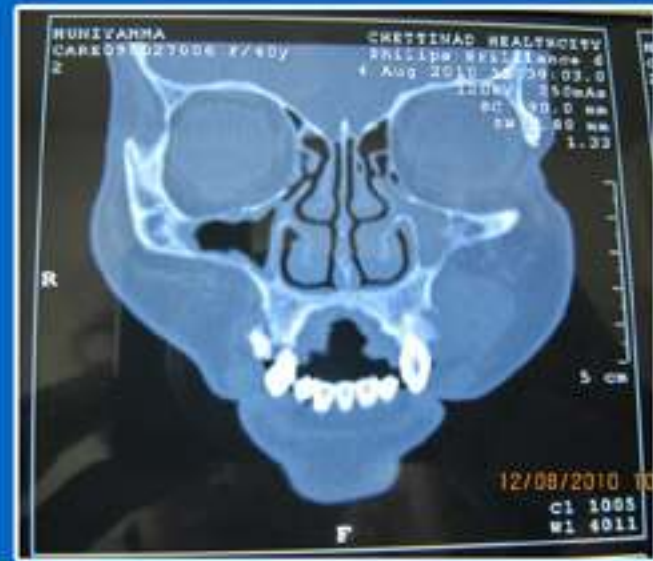
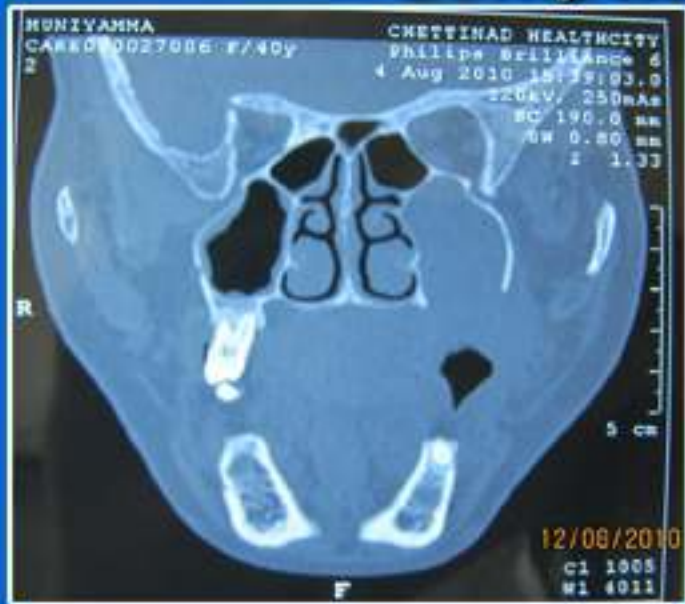
*Axial Section*

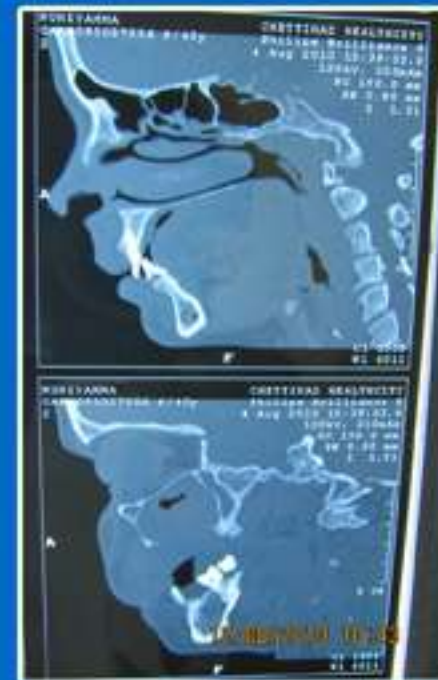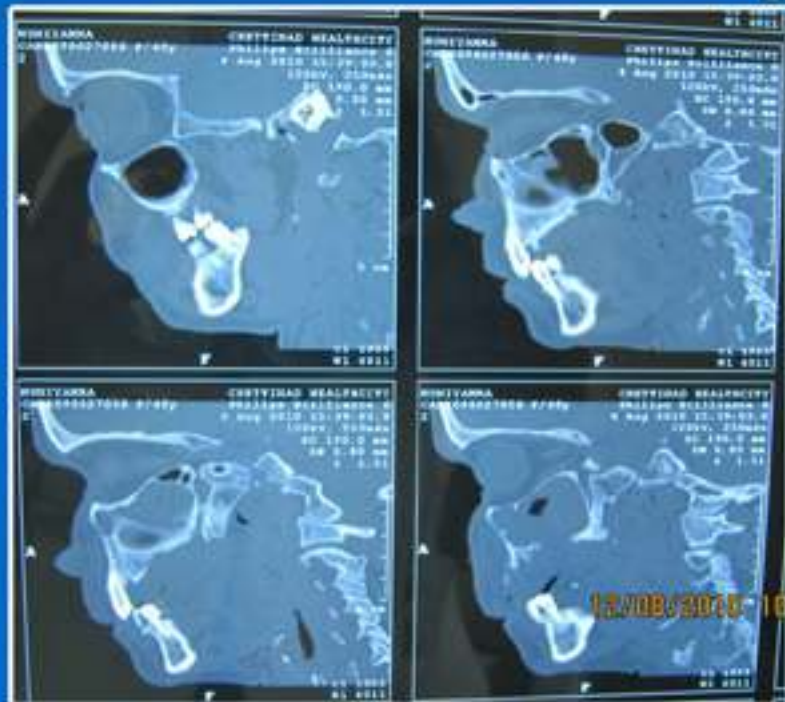


*Contrast CT*

# Computerised Tomography (CT)

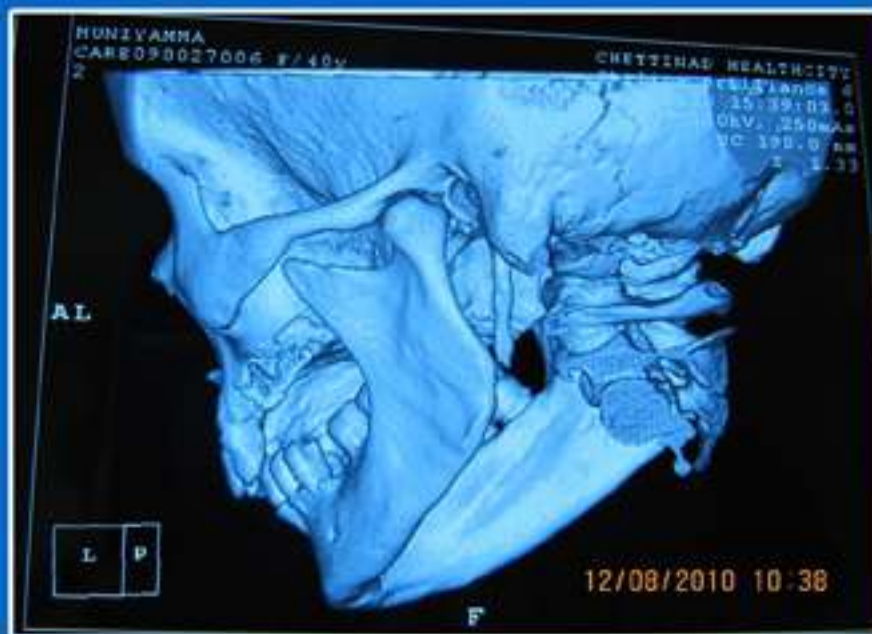
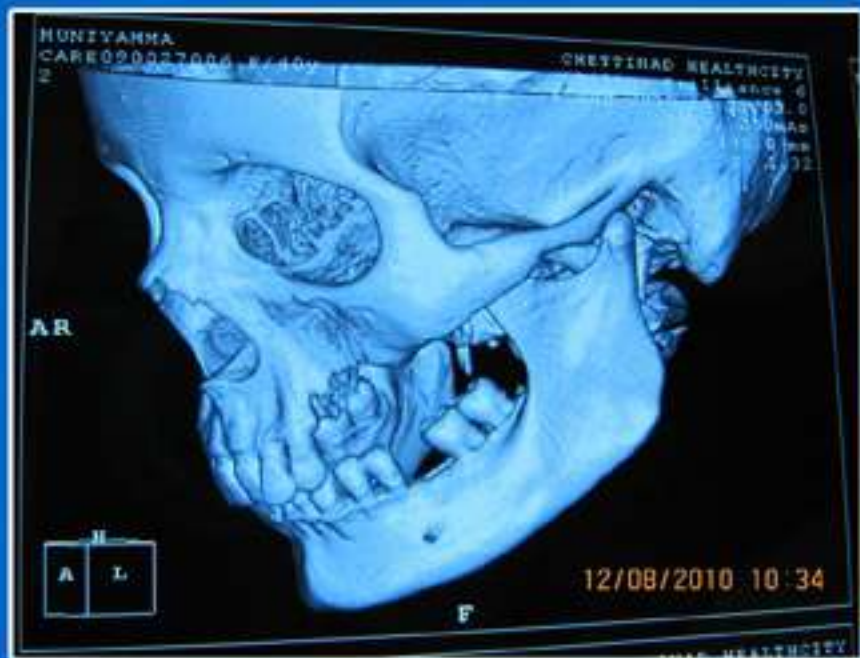
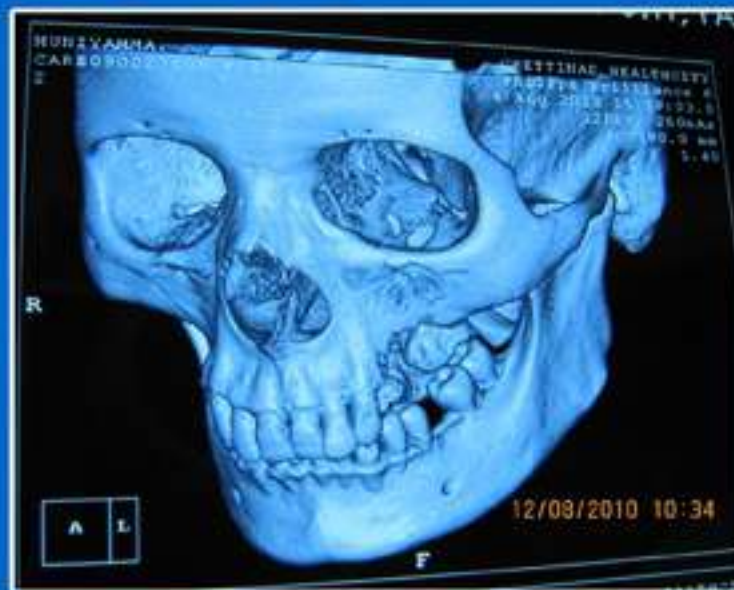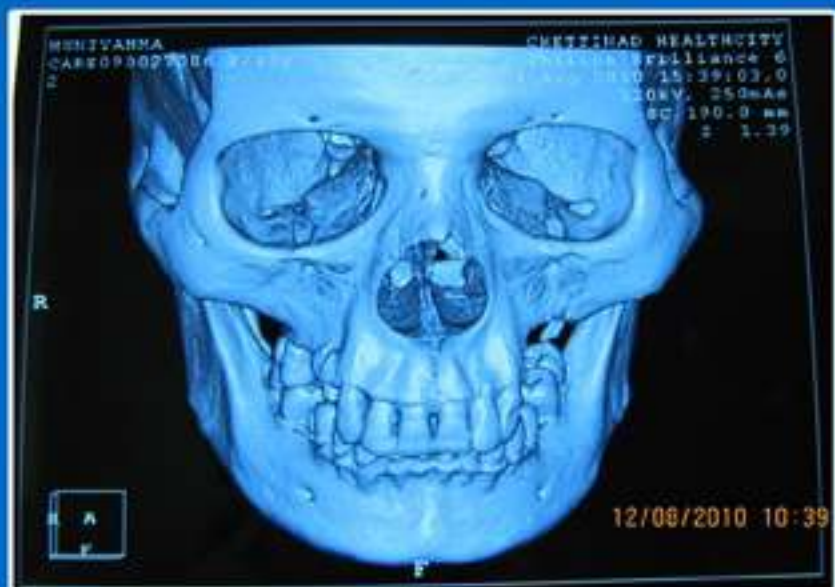Coronal Section



Sagittal Section

# 3D Computerised Tomography



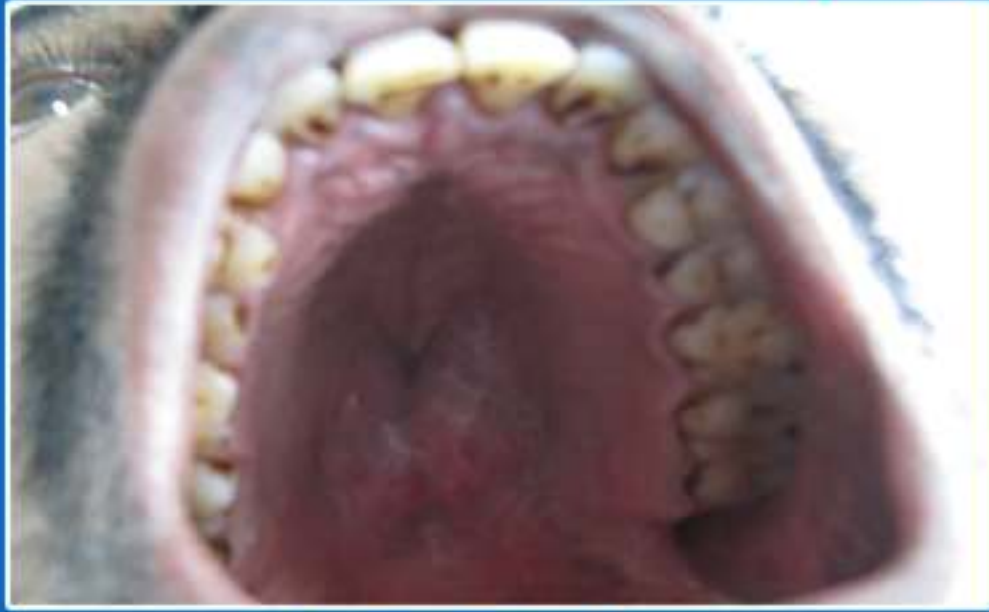*Patient Name: Mr. Thrinath Dhalan*

*Age/sex: 35y/M*

*OP No: 201102070023*

*Diagnosis: Mucoepidermoid Carcinoma*

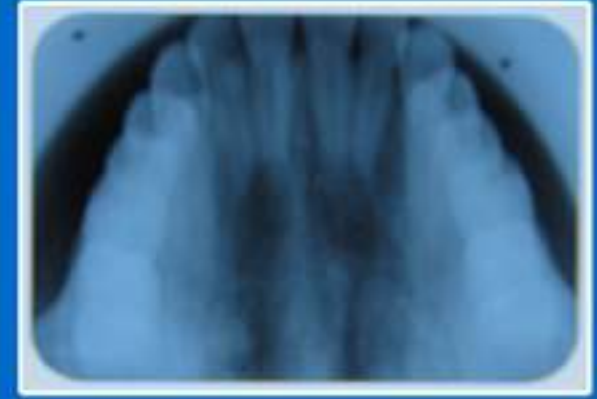
# *Mucoepidermoid Carcinoma*



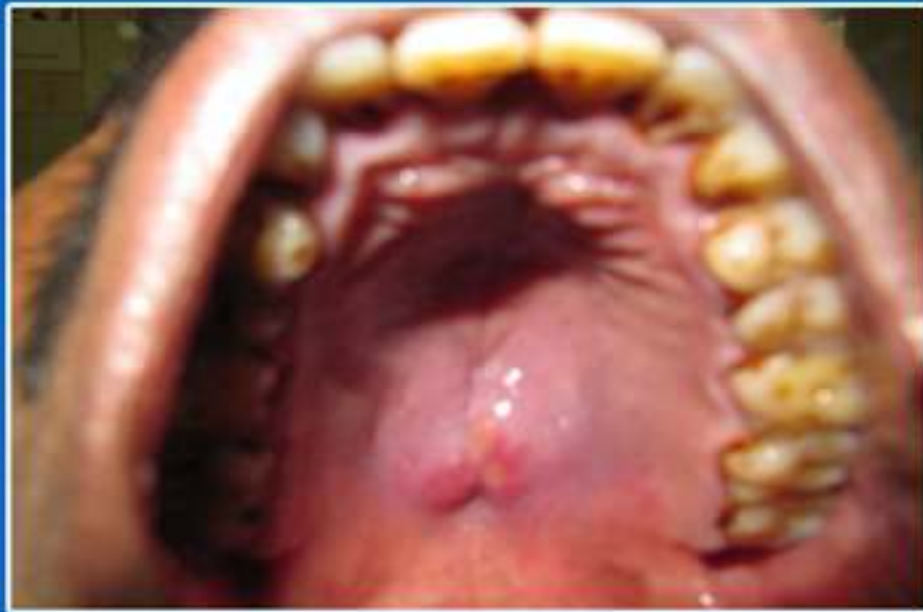*Intra Oral*



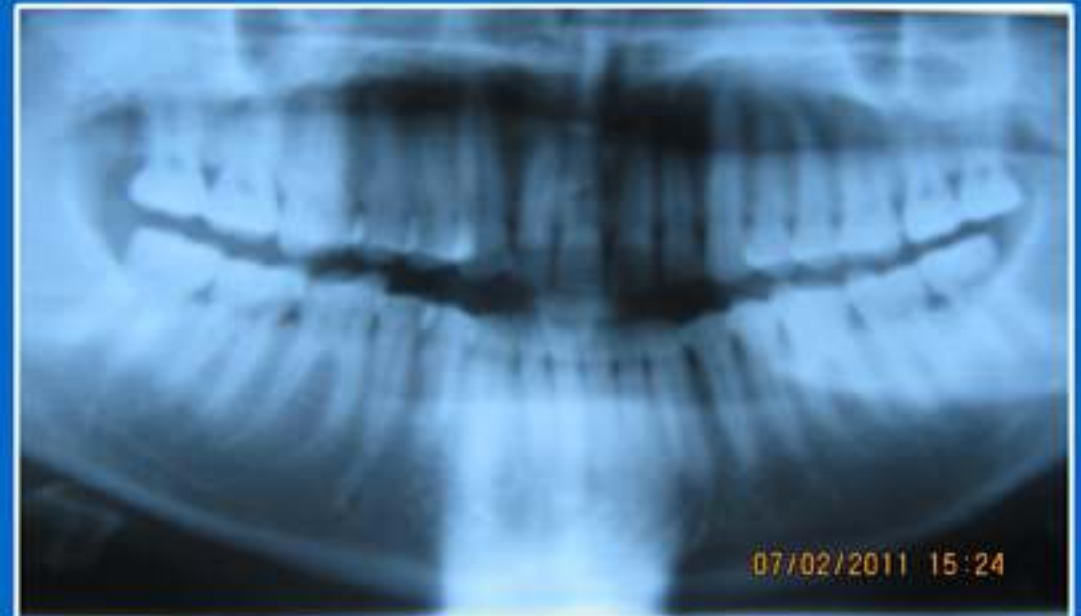*Profile*



*Maxillary Occlusal*



*Palatal Swelling*



*Orthopantomogram*

07/02/2011 15:24

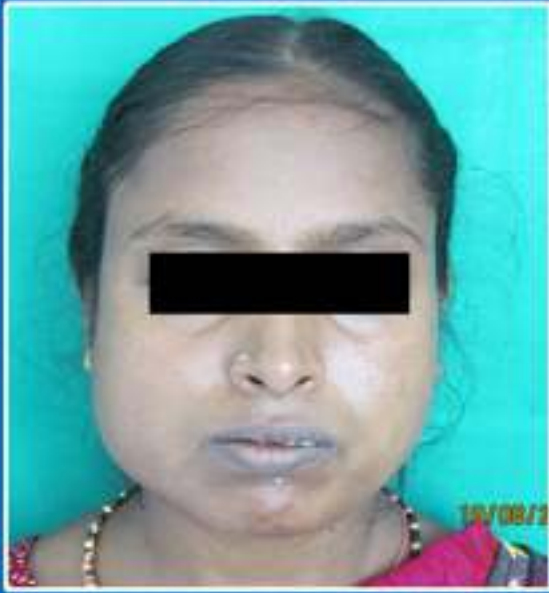*Patient Name: Mrs.Kairunisha*

*Age/sex: 38y/F*

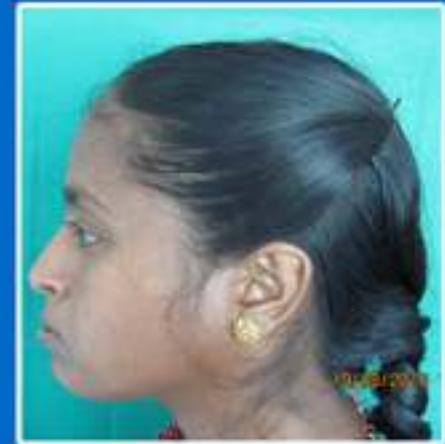*OP No: 201008120021*

*Diagnosis: Masseteric Hypertrophy  
- Right Side*

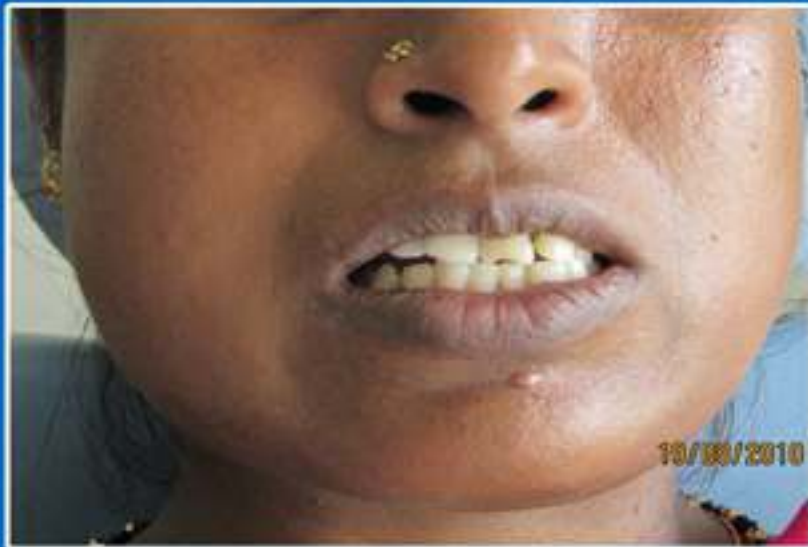# *Masseteric Hypertrophy - Right Side*



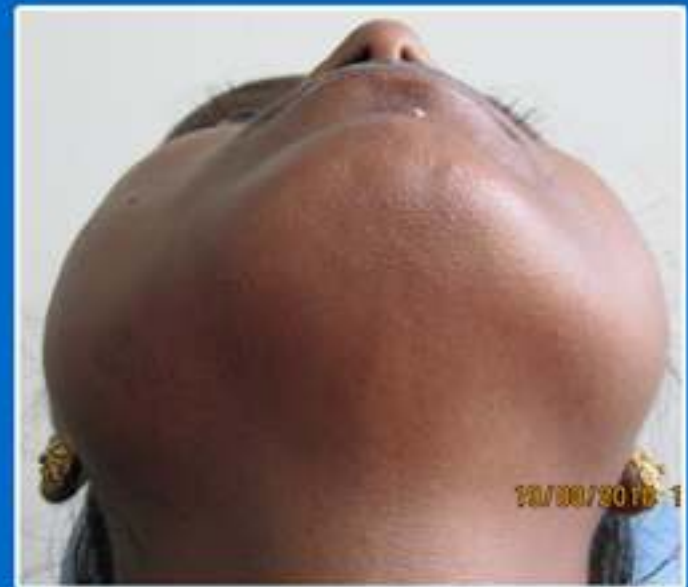*Profile*



*Lateral Profile*



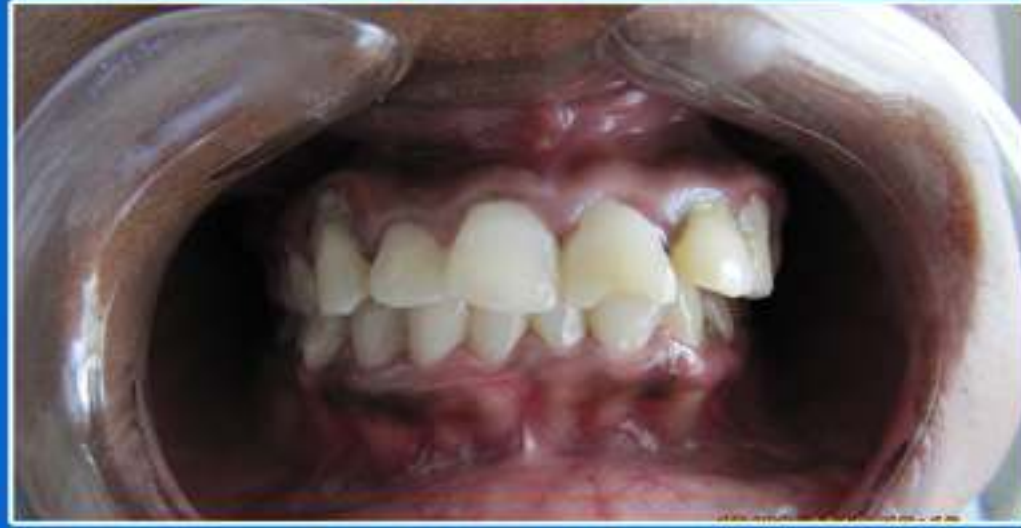*Masseteric Prominence  
on Clenching*



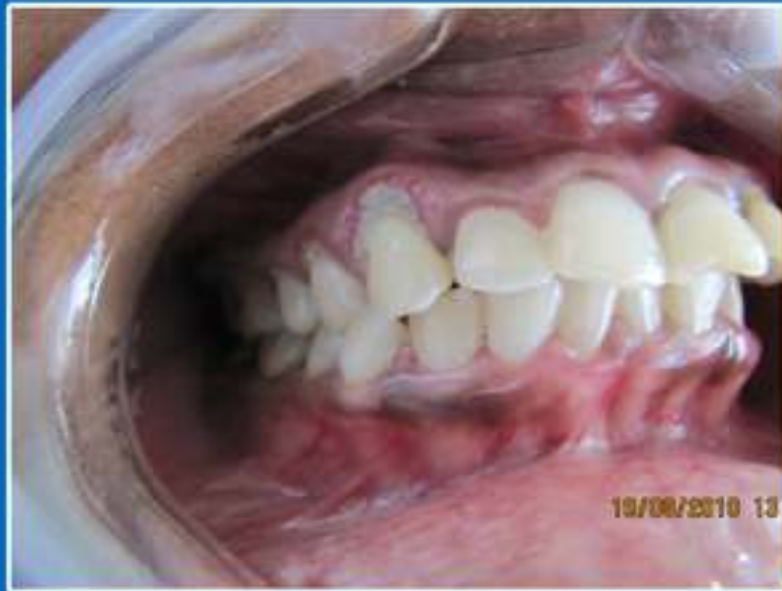*Facial Asymmetry*



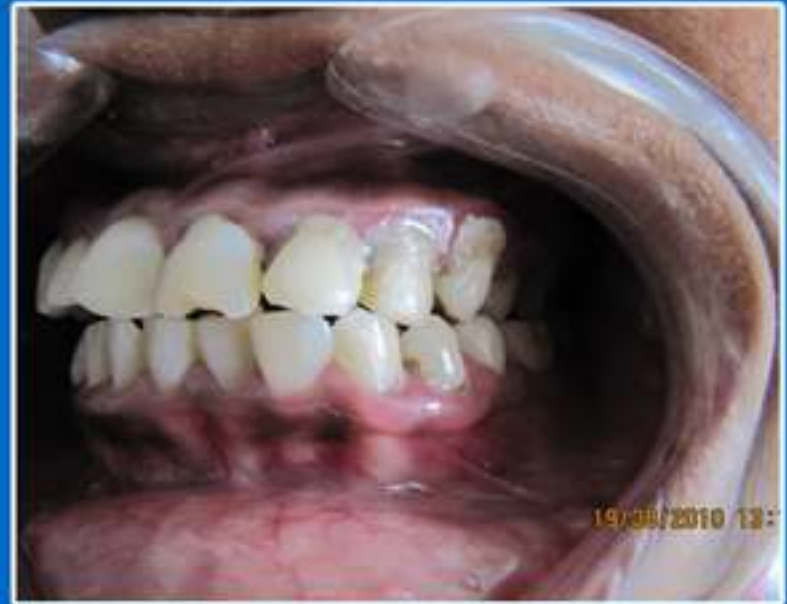# *Masseteric Hypertrophy - Right Side*



*Intra Oral*

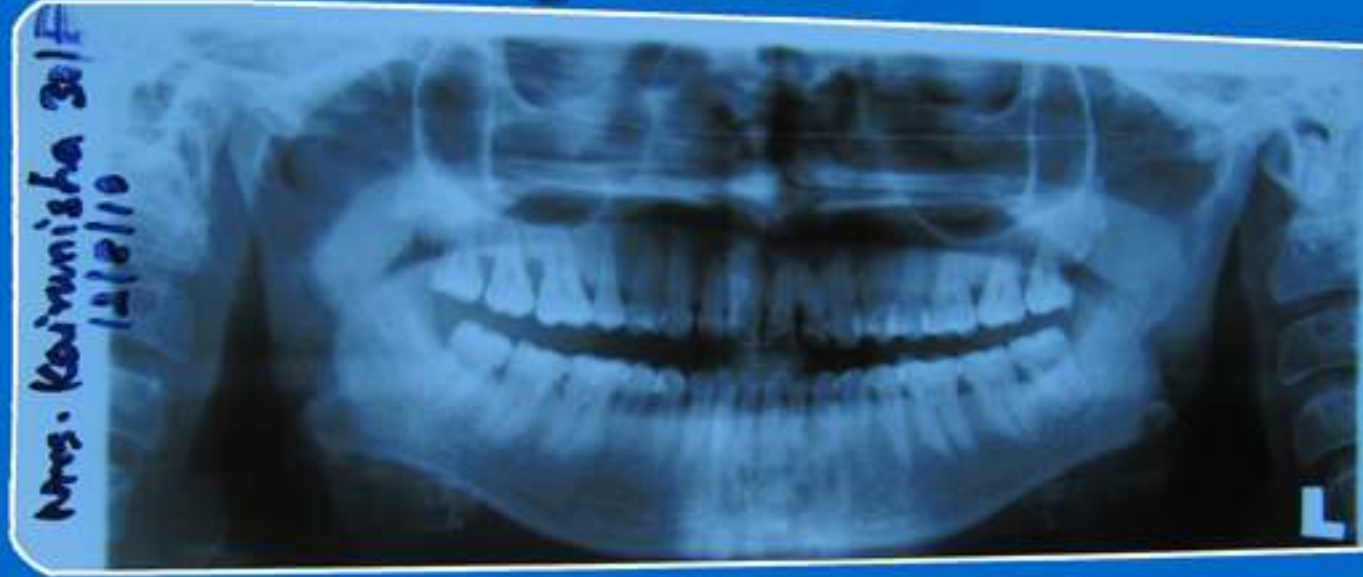

*Right*

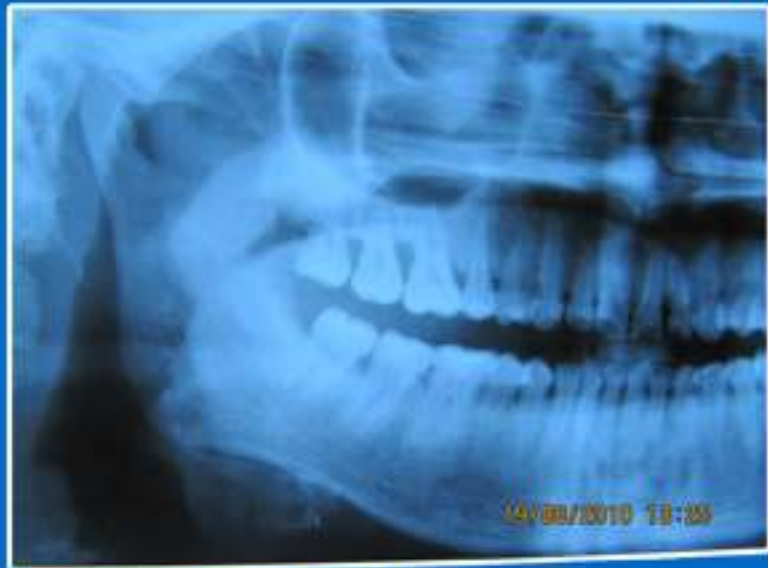

*Left*

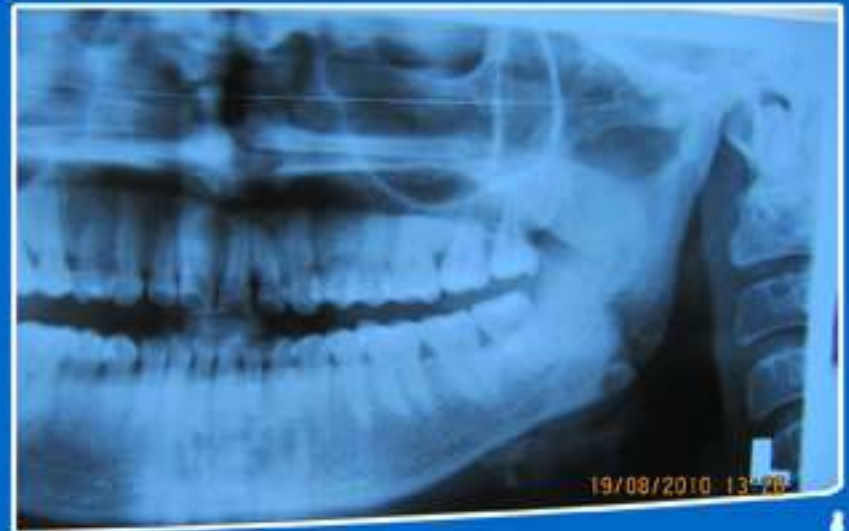# Masseteric Hypertrophy - Right Side



Orthopantomogram

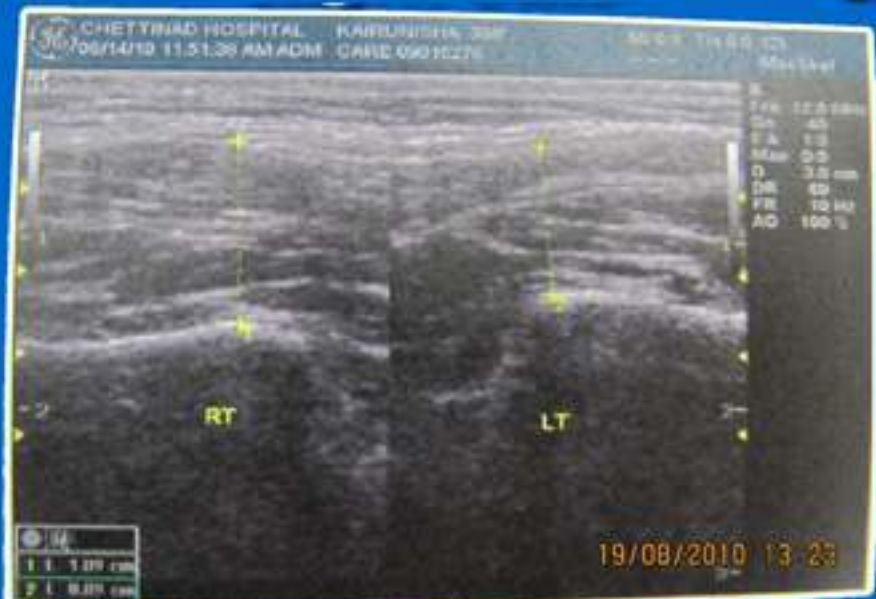


Right



Left

# Masseteric Hypertrophy - Right Side





**Chettinad**  
 Hospital & Research Institute  
 Raja Gandhi Salai, Kelambakkam,  
 Kanchipuram Dist. - 605 006

**DEPARTMENT OF RADIOLOGY & IMAGING SCIENCES**

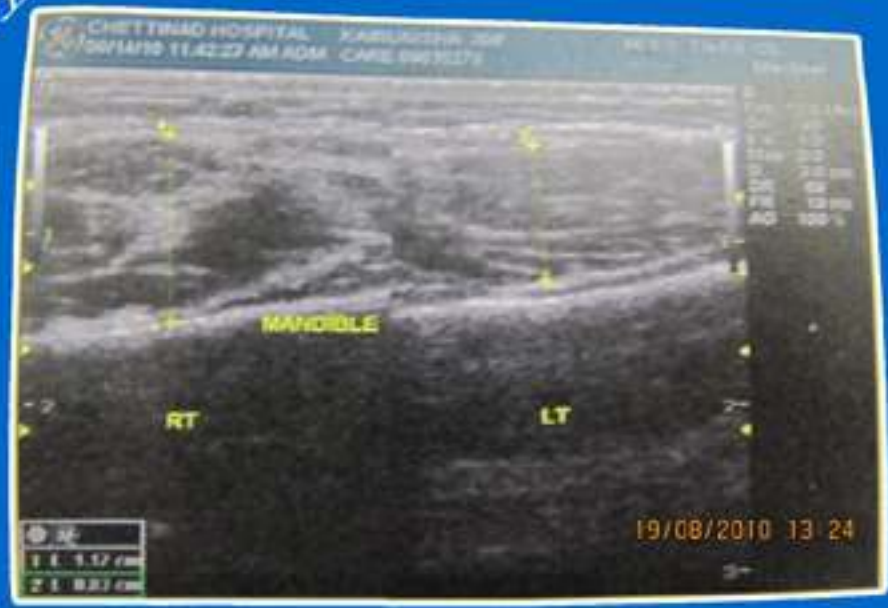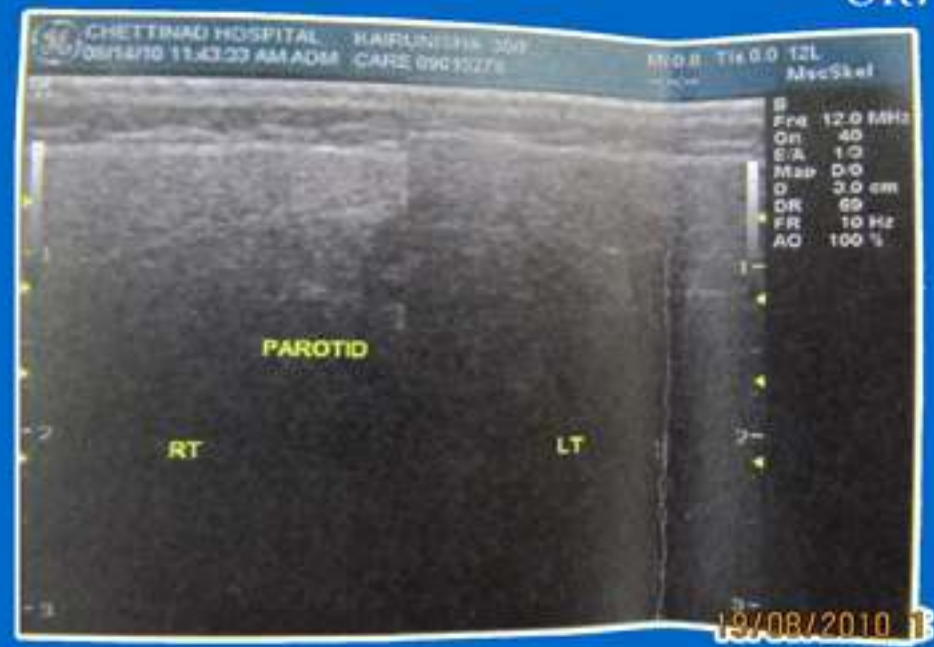Name: Mrs. Kairavisha      Age/ Sex: 30/F      Date: 14.08.2010  
 Hosp. No: CARE090215278  
 Ref by: Consultant Physician

ULTRASONOGRAPHY OF BILATERAL MASSETER MUSCLE

Right masseter more prominent than left.  
 Bilateral parotid appears normal.  
 No evidence of any focal lesion in the proximity.

  
 DR. EINSTIEN, MD, RD

## Ultra Sonography



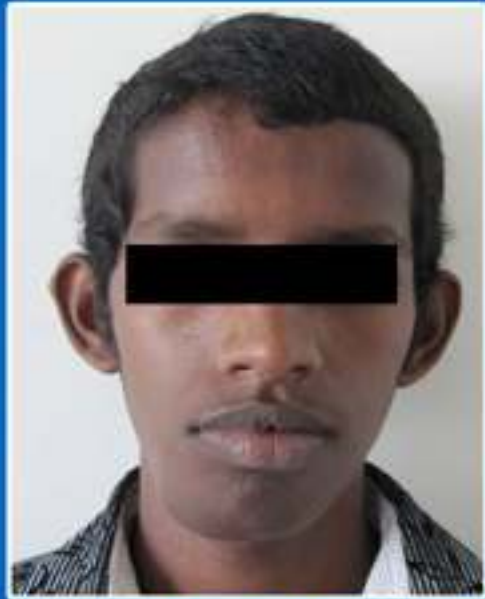*Patient Name: Mr.Manikandan*

*Age/sex: 17y/M*

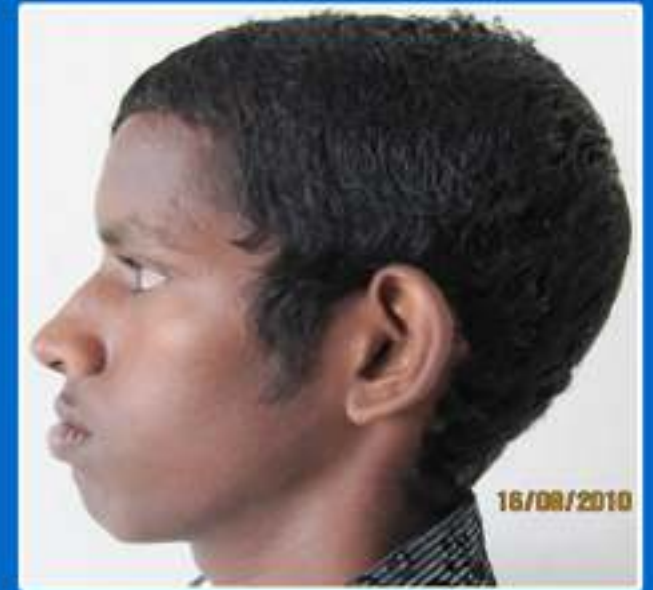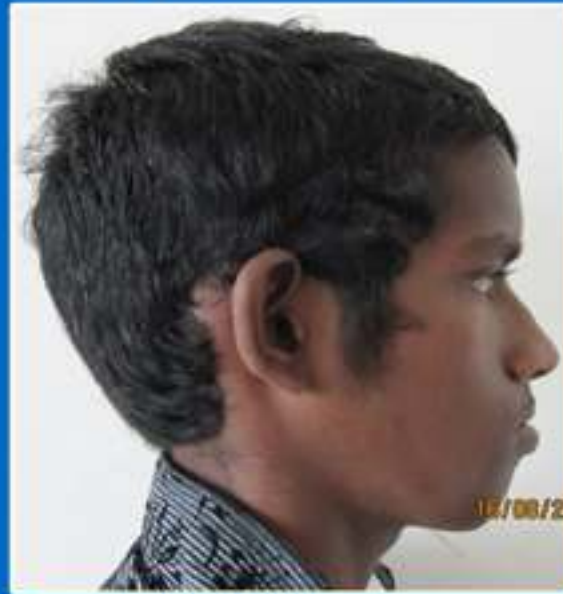*OP No: 201008160020*

*Diagnosis: Mono-Ostotic Fibrous Dysplasia*

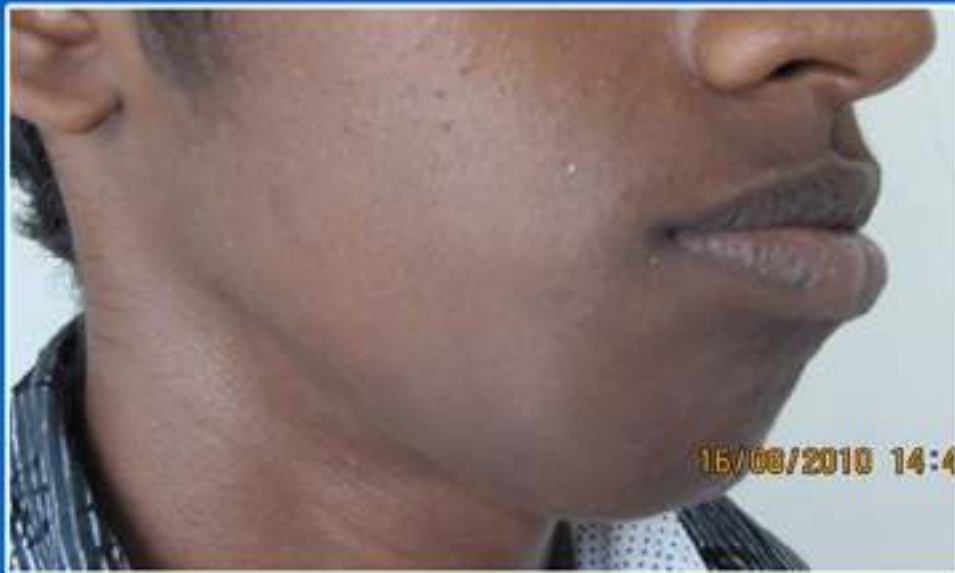# *Mono-Ostotic Fibrous Dysplasia*



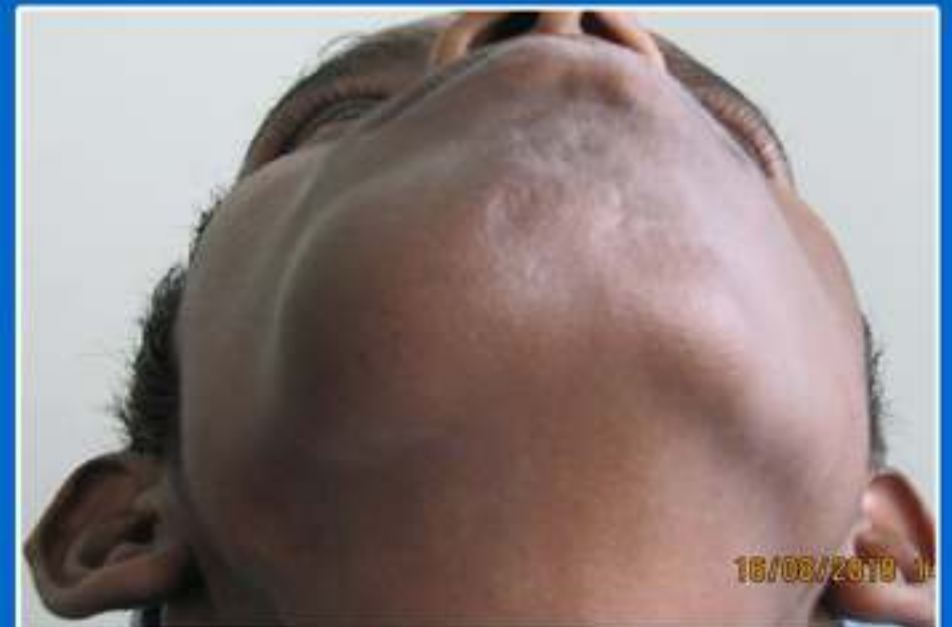*Profile*



*Lateral Profile*

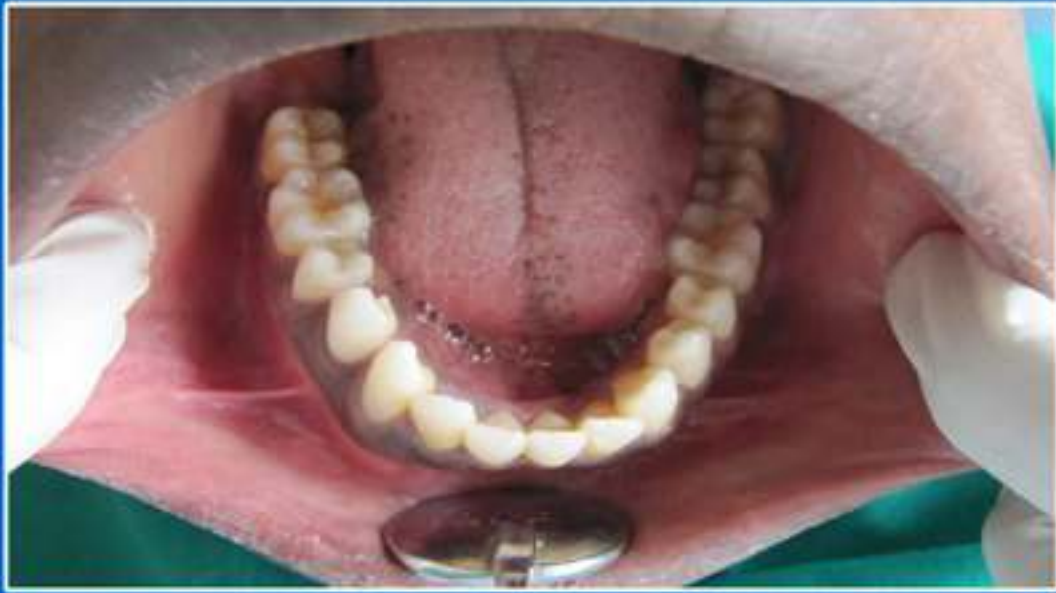

*Extra Oral Bony Swelling*

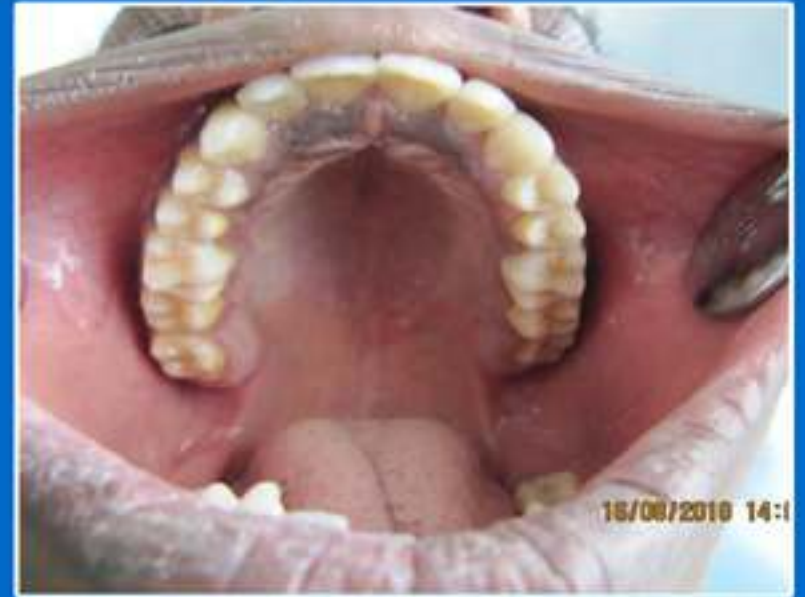

*Facial Asymmetry*

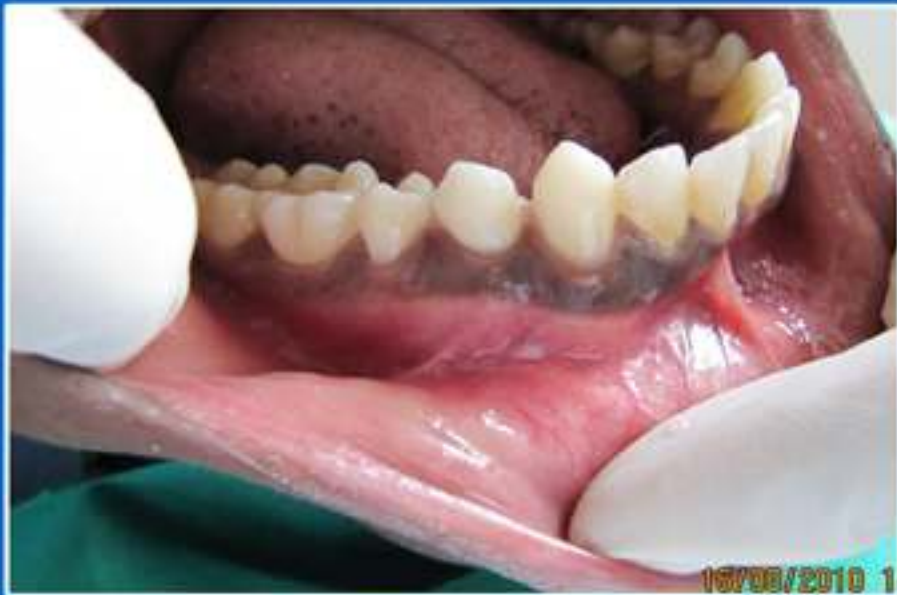# *Mono-Ostotic Fibrous Dysplasia*



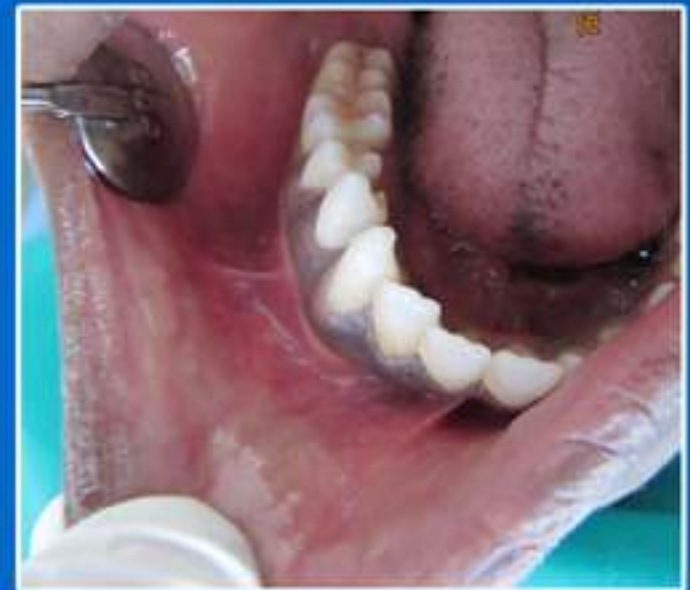*Mandibular Arch*



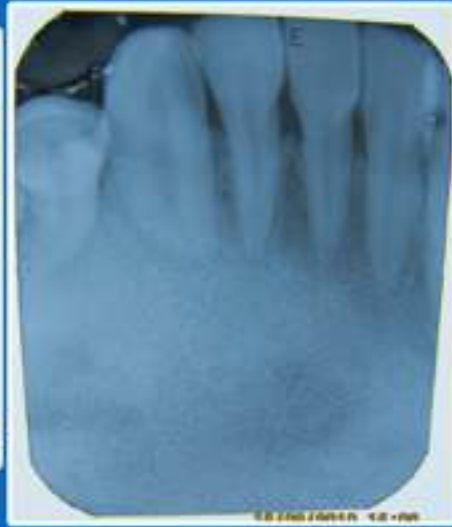
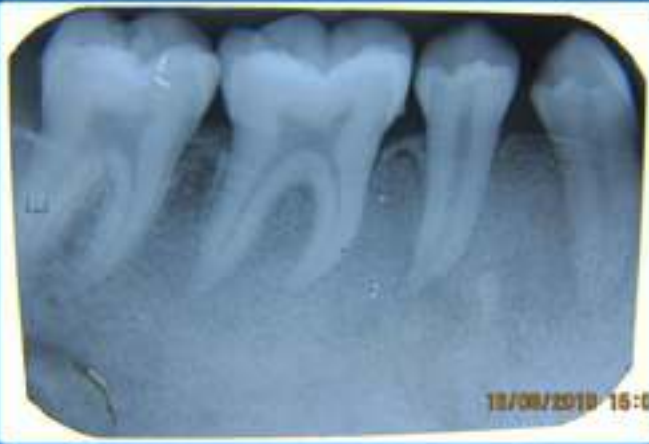*Maxillary Arch*



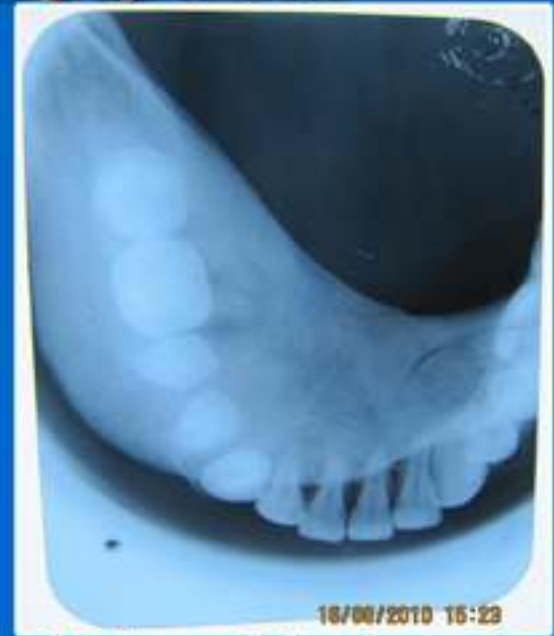
*Intra Oral Bony Swelling*



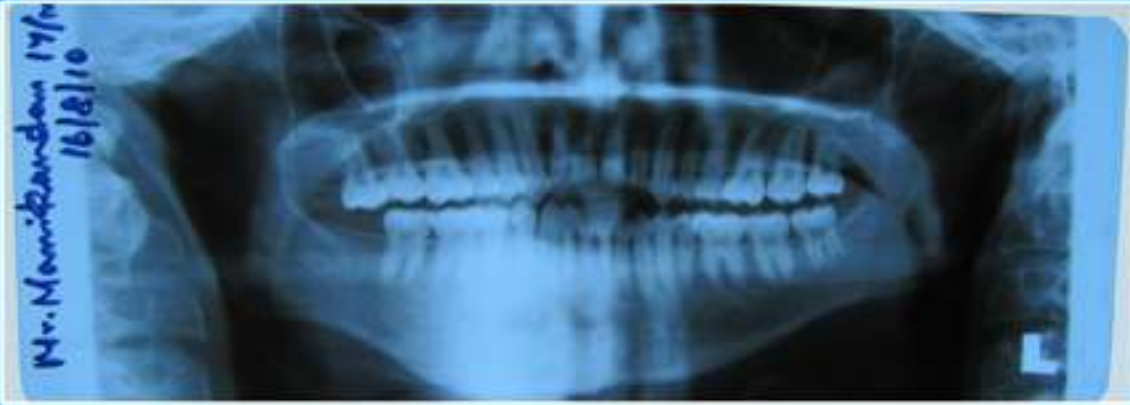
# *Mono-Ostotic Fibrous Dysplasia*



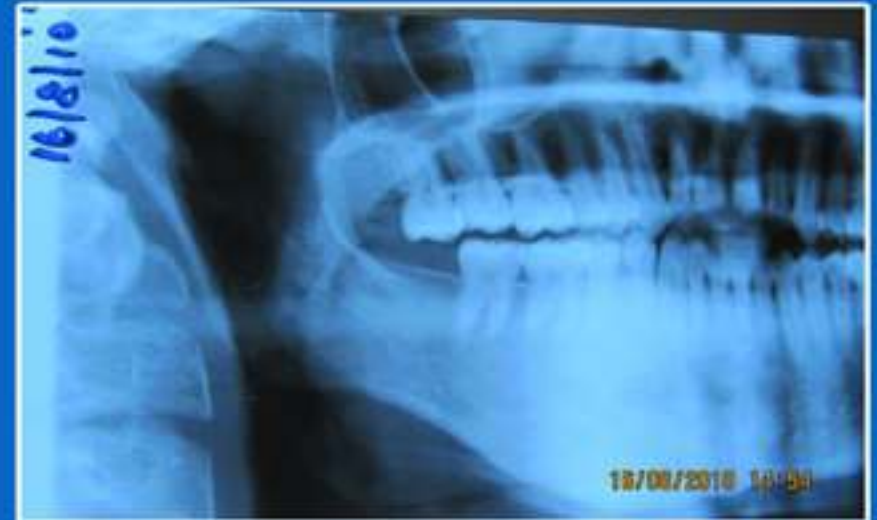*IOPA*



*Lateral Mandibular Occlusal*



*Orthopantomogram*



*OPT - Right Side*

*Patient Name: Mr.Rajendran*

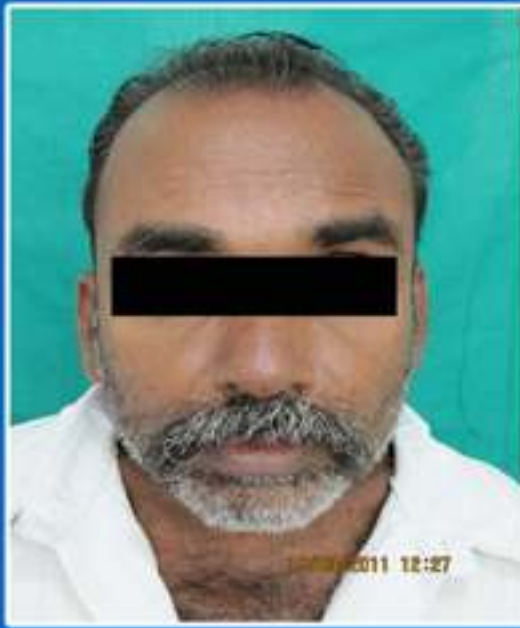*Age/sex: 55y/M*

*OP No: 201103150011*

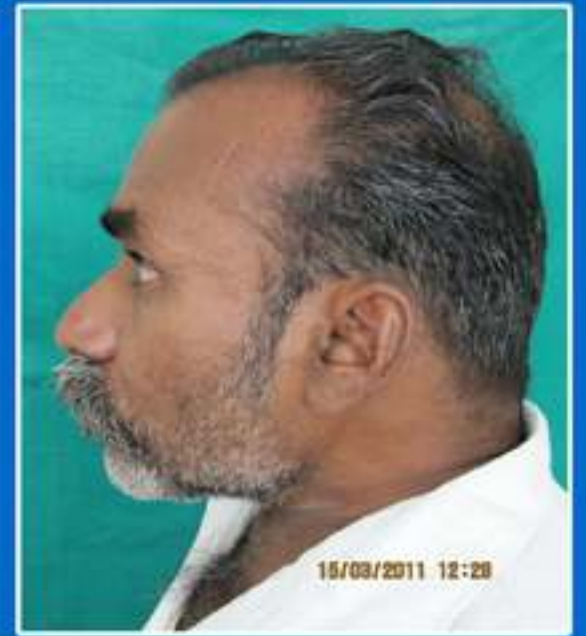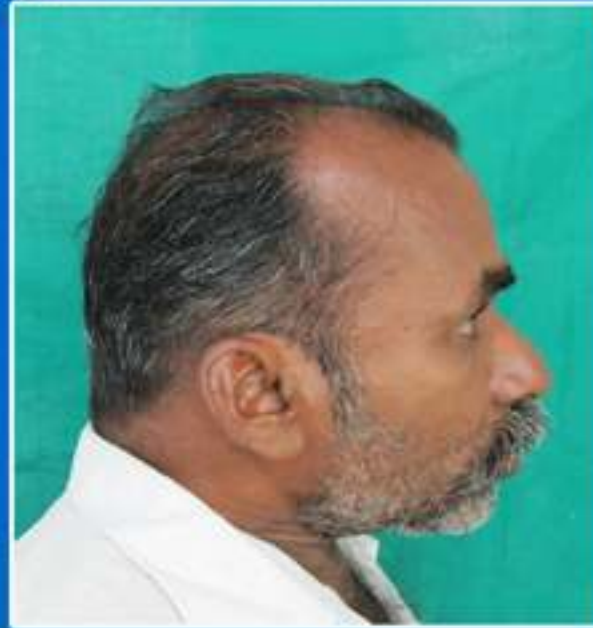*Diagnosis: Paget's Disease*



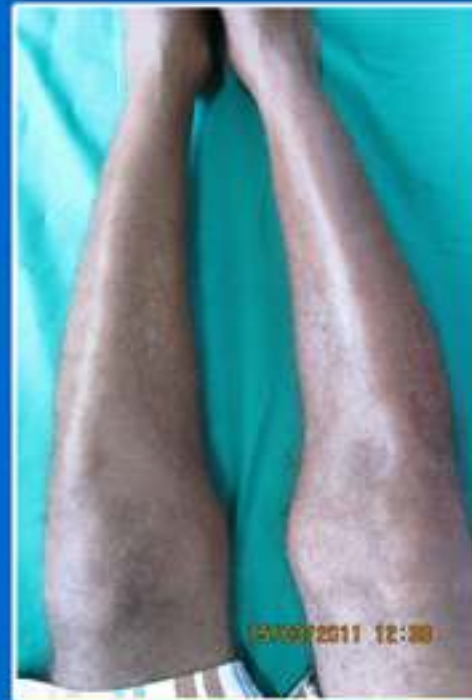# *Paget's Disease*



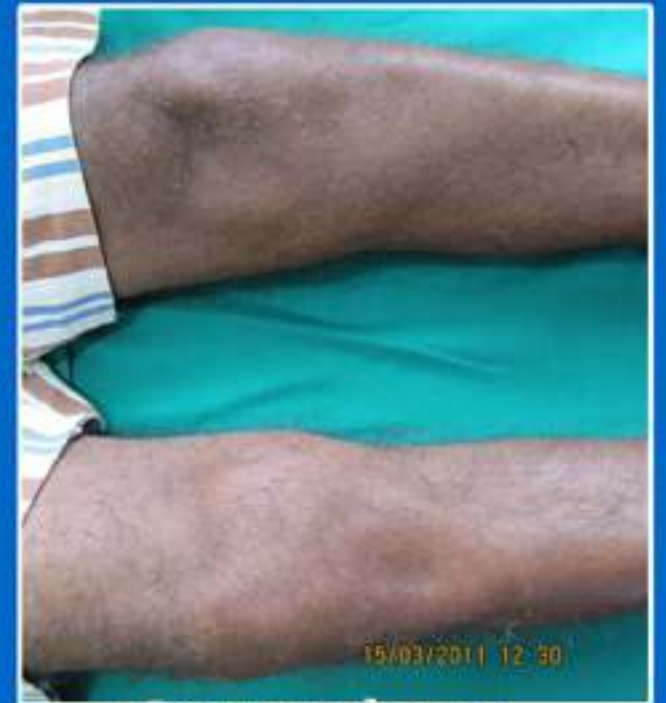*Profile*



*Stature*

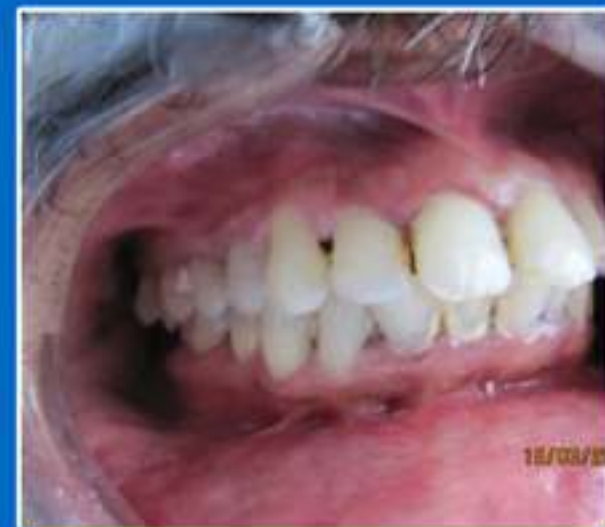
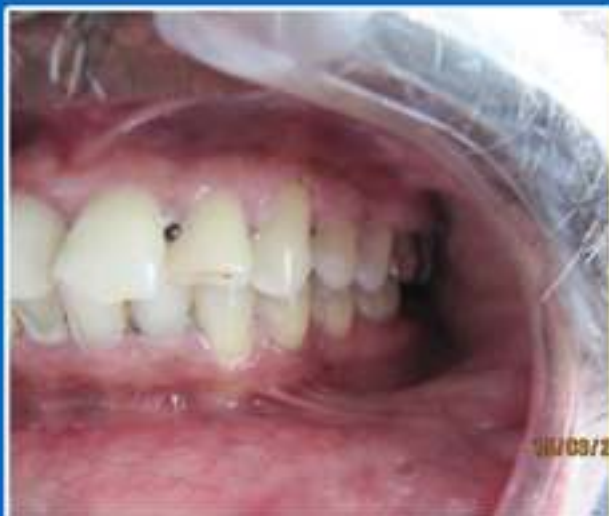
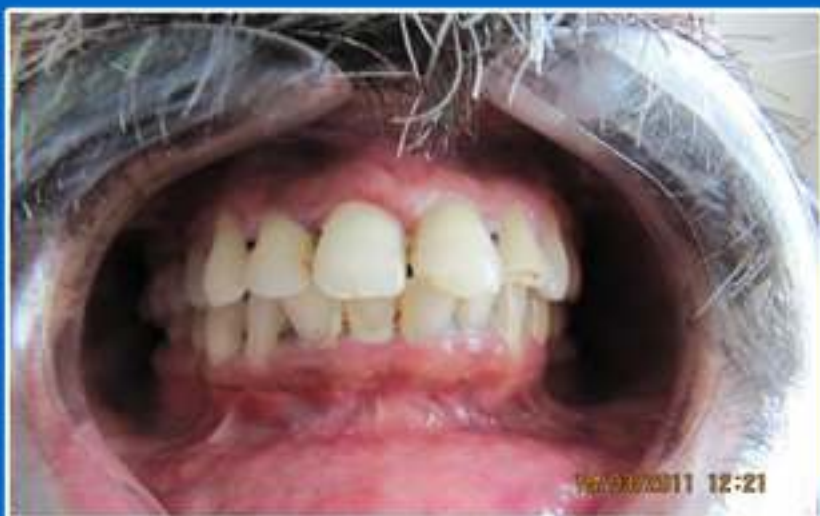*Bow Legs*

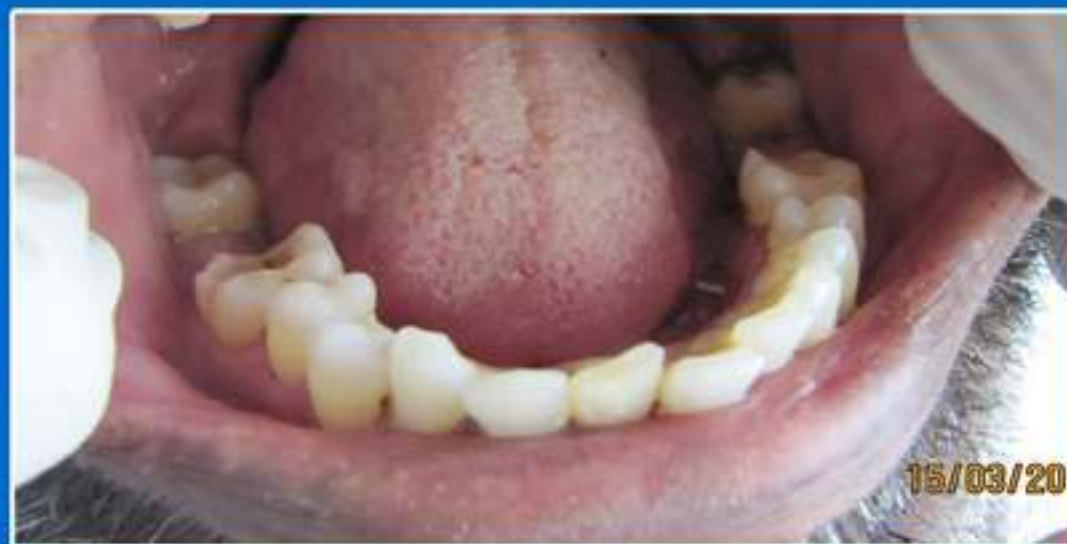
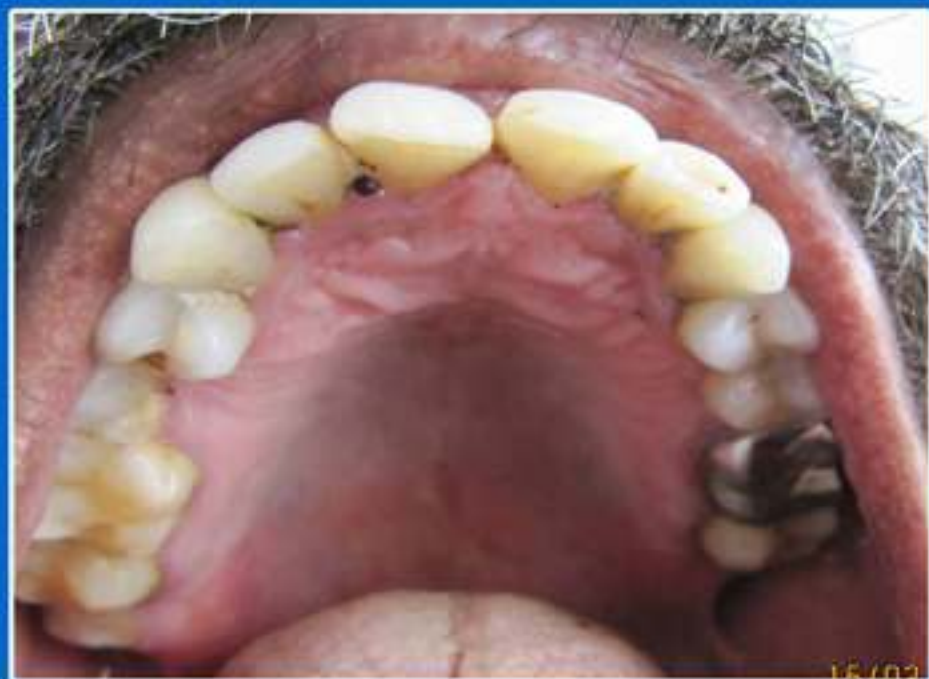
*Genu valgum*

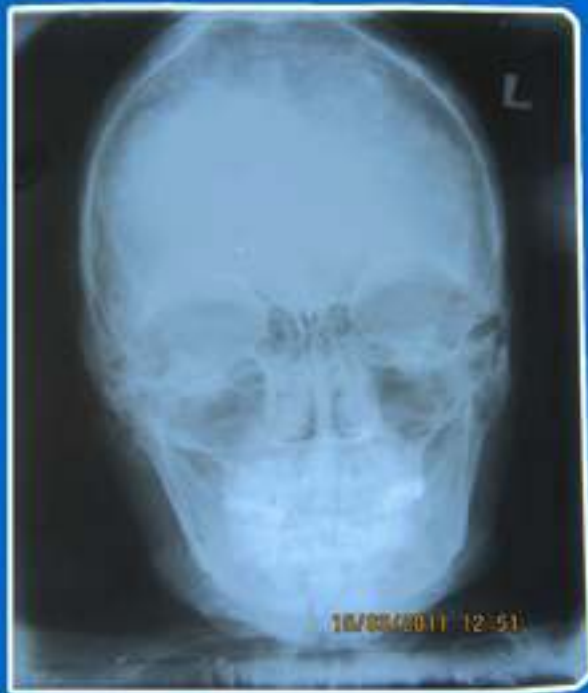## *Paget's Disease*



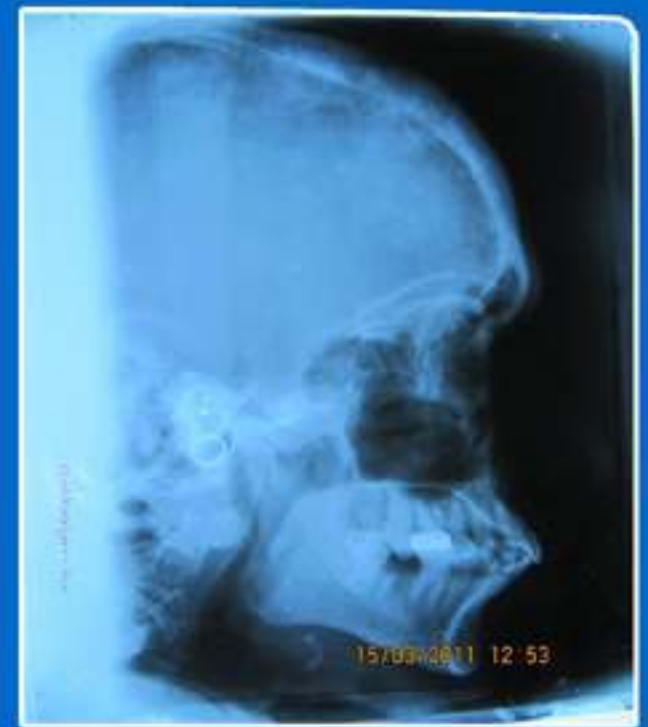*Intra Oral - No Bony Abnormality*



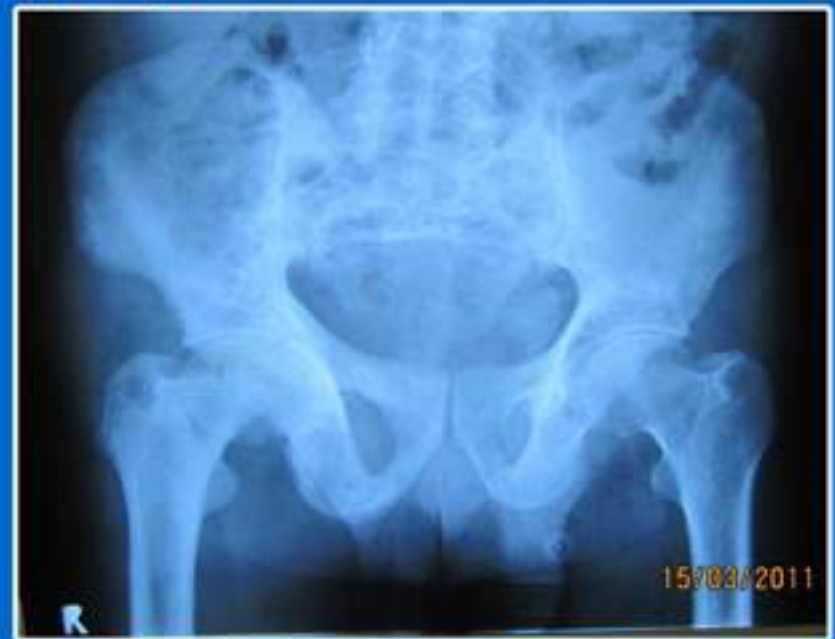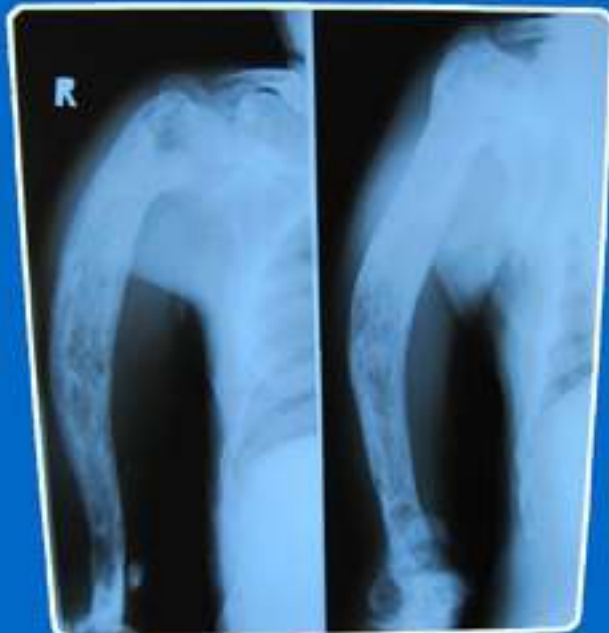# *Paget's Disease*



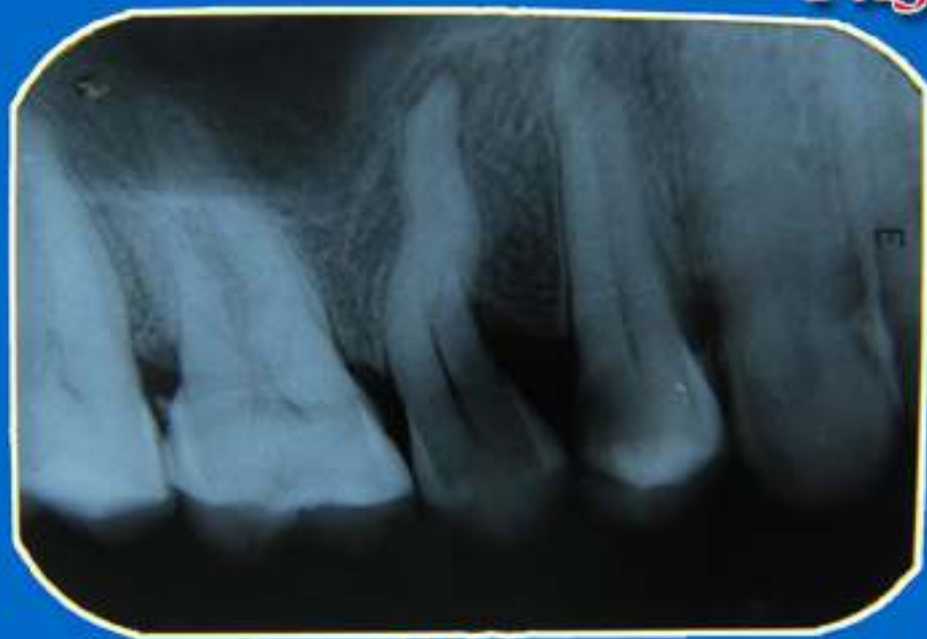*Cotton wool Appearance  
of Skull*



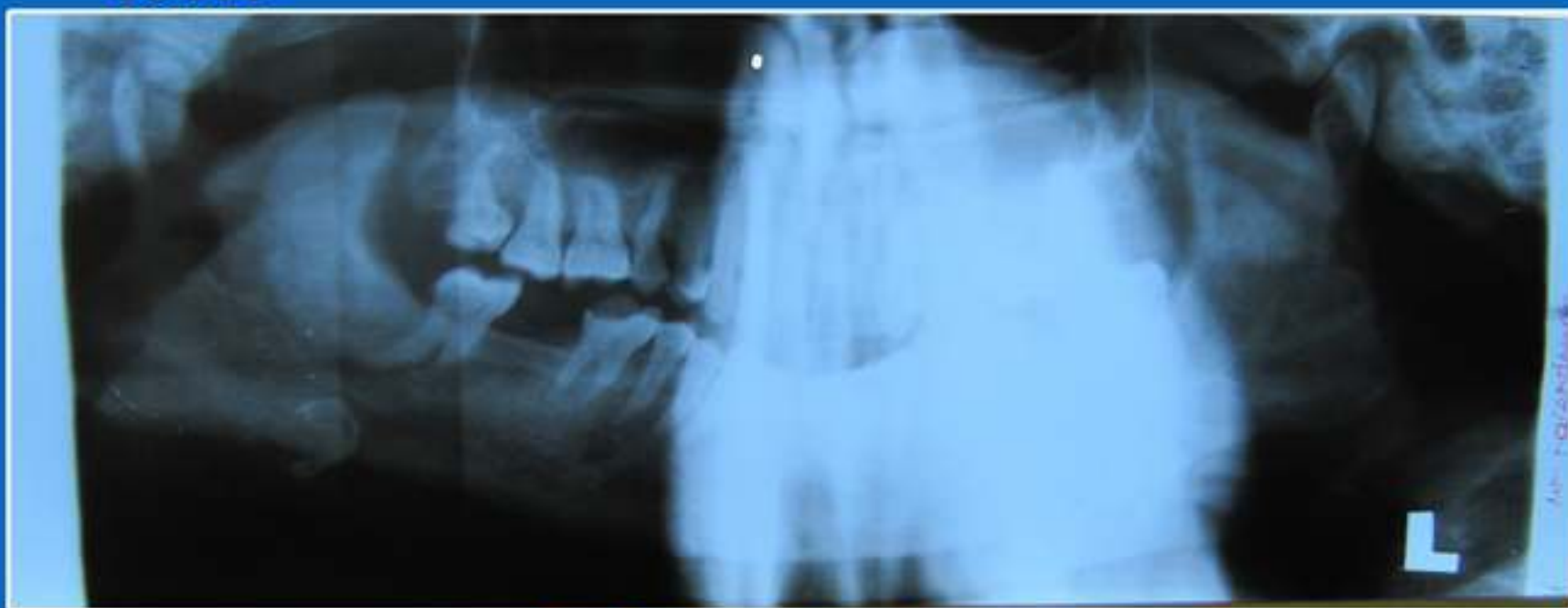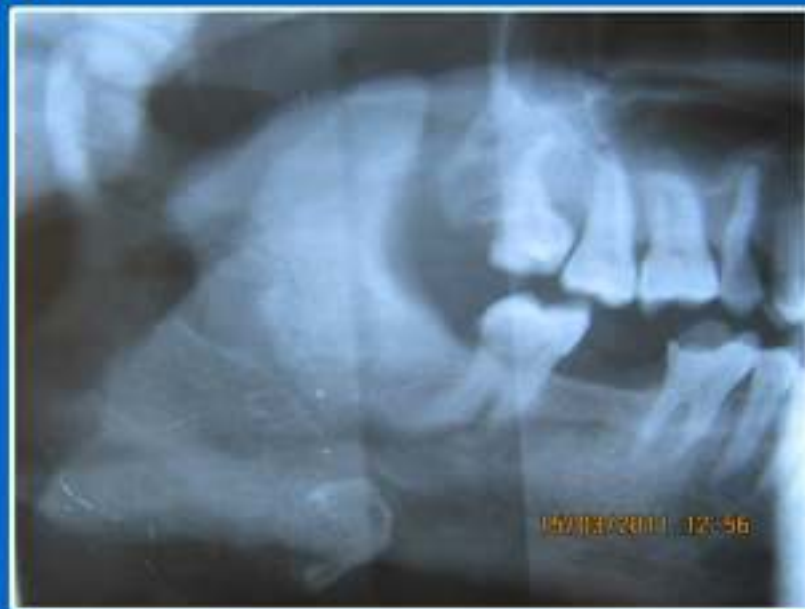*Extra Oral Radiographs*



# *Paget's Disease*



*IOPA*



*Orthopantomogram*

# Paget's Disease

**CHETTINAD HOSPITAL & RESEARCH INSTITUTE (A UNIT OF CARE)**  
Rajiv Gandhi Salai, Kelambakkam, Kanchipuram District  
Chennai-603103. Phone No. 044-47411000

**CLINICAL LABORATORY - BIOCHEMISTRY**

Cart. No. M - 0204

Name: RAJENDRAN  
Referred By: VENKATARAMAN M  
Age: 58 Years  
Sex: Male  
Source: Out Patient

WFO No.: CARE0001914  
Lab No.: ORD0000129152  
Order No.:  
Ward & Bed No.:

Sample No.	Test	Result	Units	Normal Range	Methodology	Collected Time/Date
21114	GLUCOSE (RANDOM)	82	mg/dl	80 - 140	Hexokinase	10:15 AM 30-Dec-10
21115	BLOOD UREA NITROGEN	12	mg/dl	7 - 14	Hexokinase	10:15 AM 30-Dec-10
21116	CREATININE	0.8	mg/dl	0.6 - 1.2	Jaffe Kinetic	
21117	BILIRUBIN	0.8	mg/dl	0.1 - 1.4	ISO	
21118	POTASSIUM	3.8	mg/dl	3.5 - 5	ISO	
21119	ALKALINE PHOSPHATASE	187	U/L	ADULT - 30 - 125 CHILDREN - 100 - 475 (UPTO 14 YRS)	PIPF	
21120	CALCIUM	8.2	mg/dl	8.8 - 10.2	OCPC method	

Confirmed by: AMAL/30-Dec-10 1:23:03PM  
Validated by: AMAL/30-Dec-10 1:40:03PM

Authorised signatory

10/100/0511 12:48

**CHETTINAD HOSPITAL & RESEARCH INSTITUTE (A UNIT OF CARE)**  
Rajiv Gandhi Salai, Kelambakkam, Kanchipuram District  
Chennai-603103. Phone No. 044-47411000

**CLINICAL LABORATORY - BIOCHEMISTRY**

Cart. No. M - 0204

Name: RAJENDRAN  
Age: 58 Years (8 Months) 15 Days  
Sex: Male  
Source: Out Patient

Referred By: VENKATARAMAN M  
Hospital No.: CARE00101914  
Order No.: ORD0000129101  
Ward Name:

Sample No.	Test	Result/Comment	Units	Normal	Methodology	Collected Time/Date
208435	ALKALINE PHOSPHATASE (ALP) ALKALINE PHOSPHATASE	942	U/L	ADULT - 60 - 120 CHILDREN - 150 - 475 (UPTO 14 YRS)	PIPF	30-Dec-10 11:54:30AM

Confirmed by: AMAL/30-Dec-10 1:23:03PM  
Validated by: AMAL/30-Dec-10 1:22:03PM

Authorised signatory

—End of Report—

## Biochemical Investigations

**CHETTINAD HOSPITAL & RESEARCH INSTITUTE (A UNIT OF CARE)**  
Rajiv Gandhi Salai, Kelambakkam, Kanchipuram District  
Chennai-603103. Phone No. 044-47411000

**CLINICAL LABORATORY - BIOCHEMISTRY**

Cart. No. M - 0204

Name: RAJENDRAN  
Age: 58 Years (8 Months) 15 Days  
Sex: Male  
Source: Out Patient

Referred By: VENKATARAMAN M  
Hospital No.: CARE00101914  
Order No.: ORD0000129052  
Ward Name:

Sample No.	Test	Result/Comment	Units	Normal	Methodology	Collected Time/Date
208434	CALCIUM CALCIUM (Ca)	8.1	mg/dl	8.8 - 10.2	OCPC method	30-Dec-10 11:54:02AM

Confirmed by: AMAL/30-Dec-10 1:23:03PM  
Validated by: AMAL/30-Dec-10 1:23:05PM

Authorised signatory

—End of Report—

32321

**CHETTINAD HOSPITAL & RESEARCH INSTITUTE (A UNIT OF CARE)**  
Rajiv Gandhi Salai, Kelambakkam, Kanchipuram District  
Chennai-603103. Phone No. 044-47411000

**CLINICAL LABORATORY - BIOCHEMISTRY**

Cart. No. M - 0204

Name: RAJENDRAN  
Age: 58 Years (8 Months) 15 Days  
Sex: Male  
Source: Out Patient

Referred By: VENKATARAMAN M  
Hospital No.: CARE00101914  
Order No.: ORD0000129052  
Ward Name:

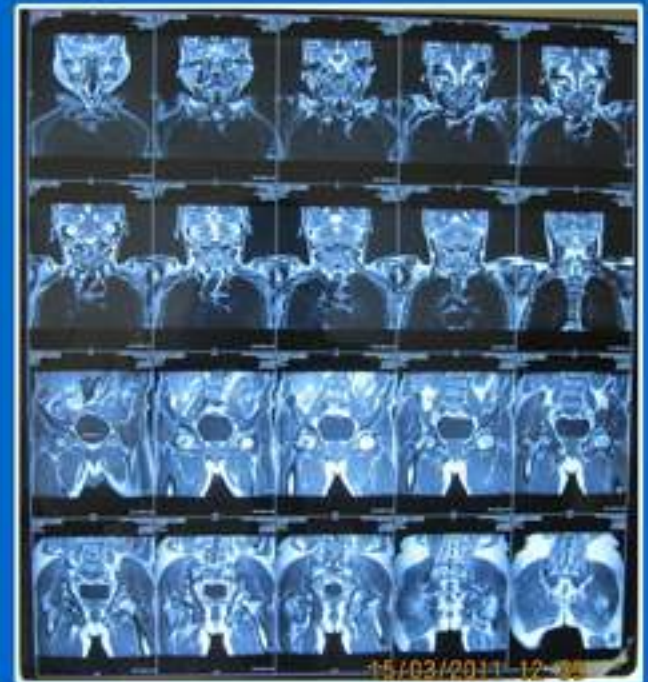
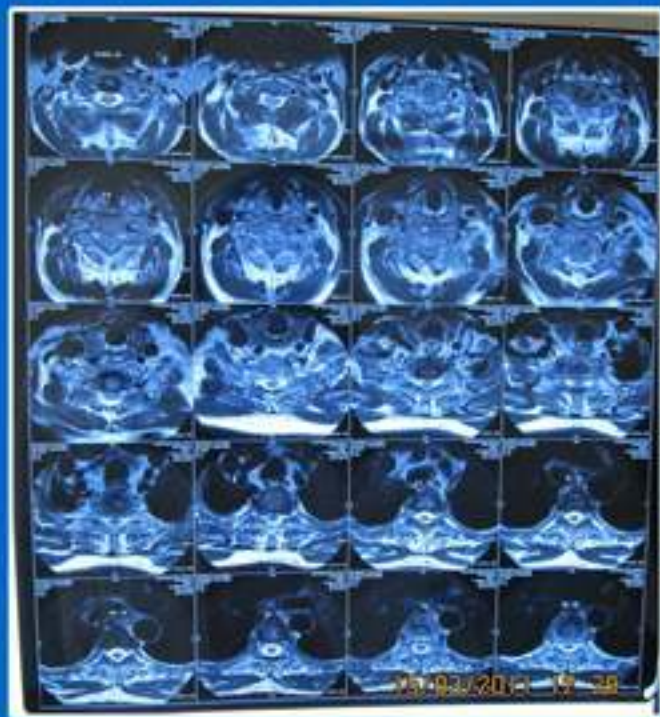
Sample No.	Test	Result/Comment	Units	Normal	Methodology	Collected Time/Date
208433	PHOSPHORUS	3.5	mg/dl	2.1 - 3.0	UV Endpoint	30-Dec-10 11:54:02AM

Confirmed by: AMAL/30-Dec-10 1:23:03PM  
Validated by: AMAL/30-Dec-10 1:23:05PM

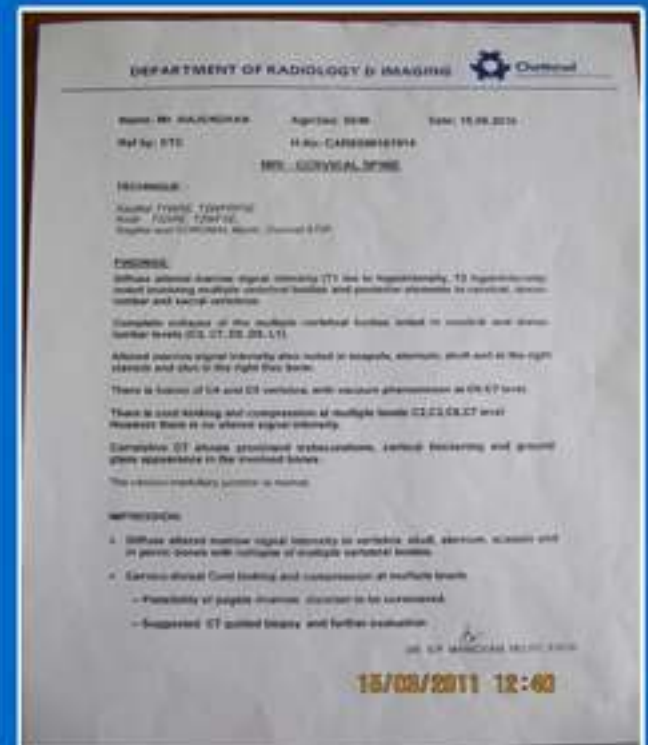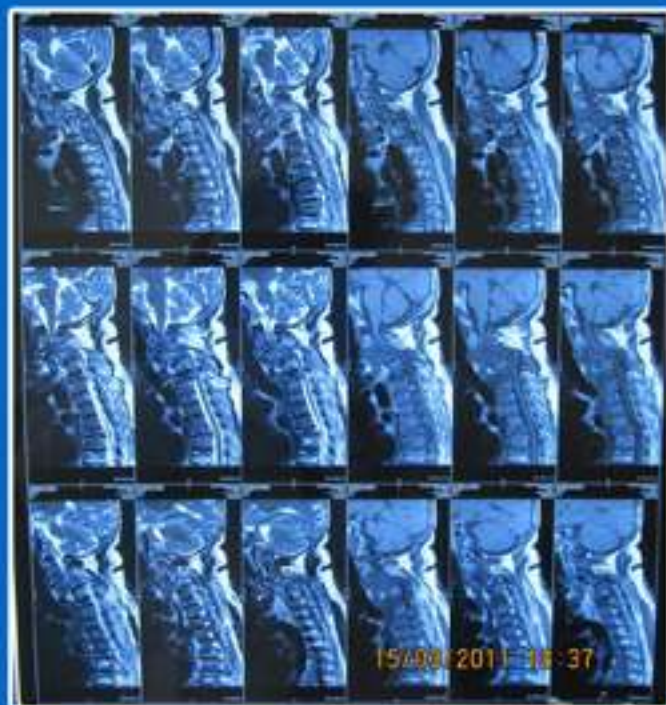
Authorised signatory

—End of Report—

# Paget's Disease



MRI Scan



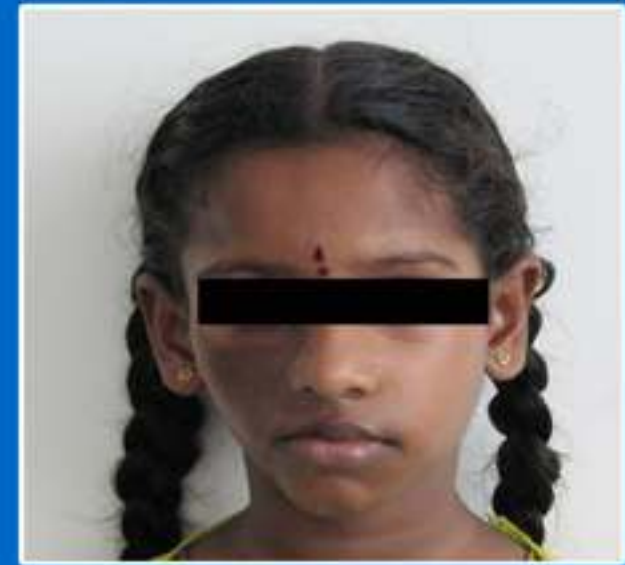*Patient Name: Ms.Sathya*

*Age/sex: 9y/F*

*OP No: 201006140016*

*Diagnosis: Parry Romberg Syndrome*

# *Parry Romberg Syndrome*

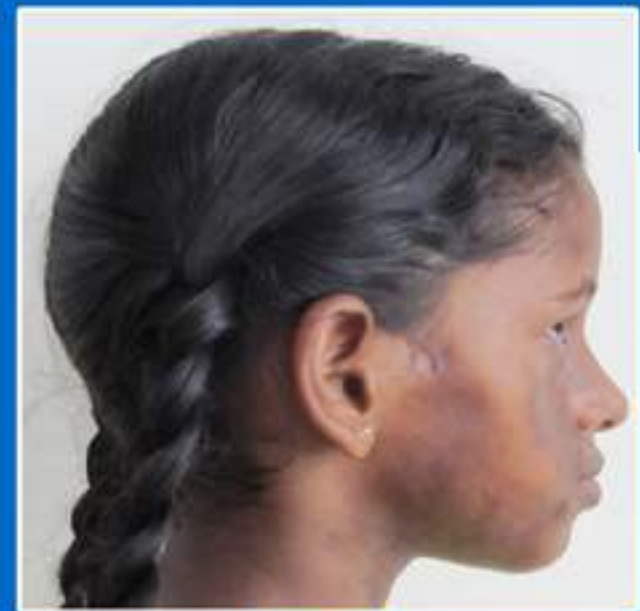

*Profile*



*Left*

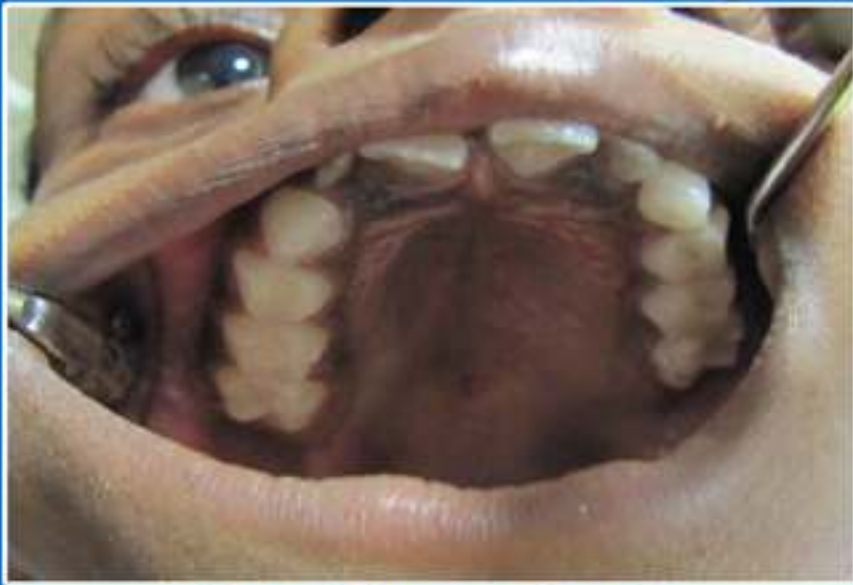*Lateral Profile*



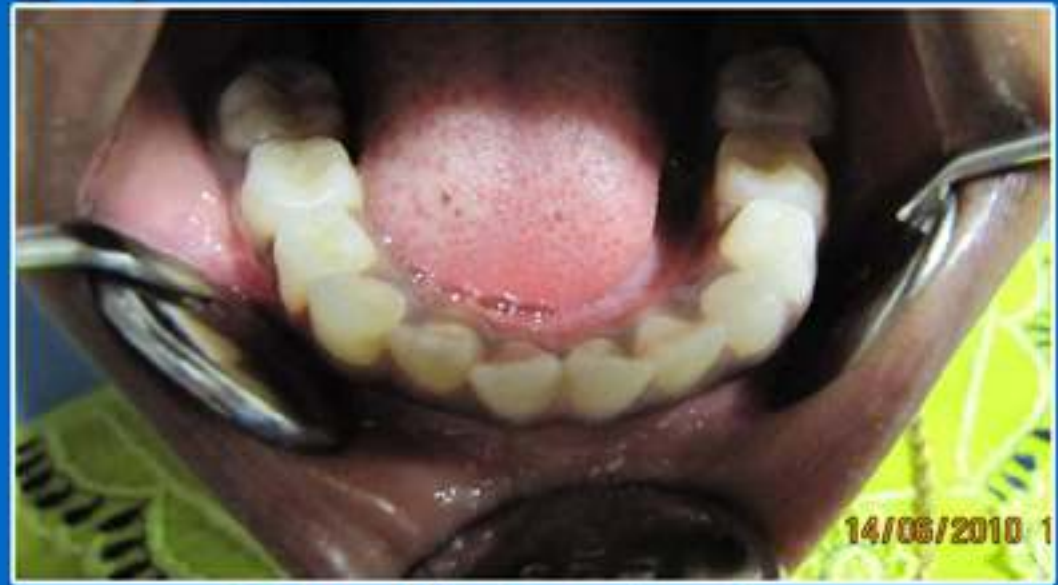*Right*



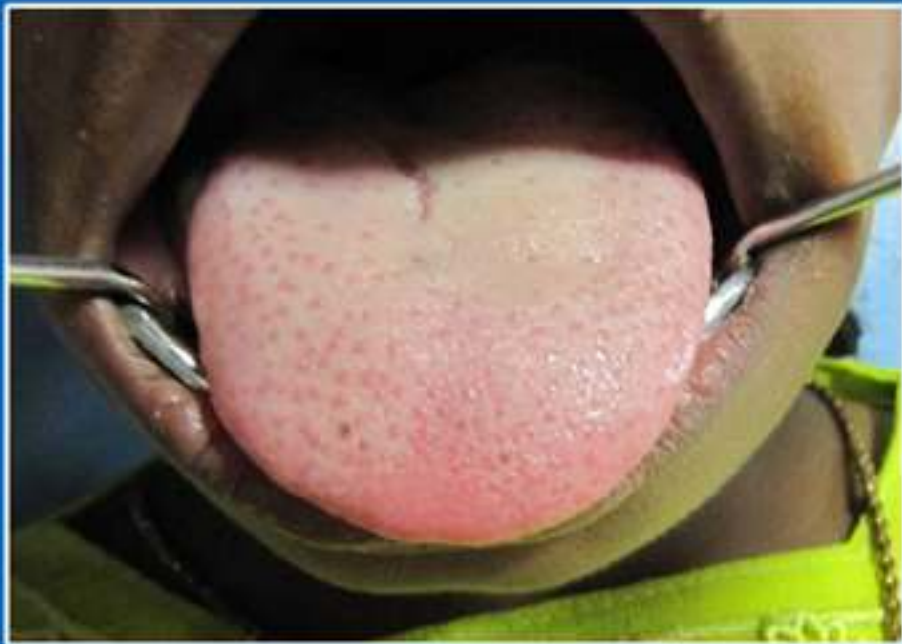# *Parry Romberg Syndrome*



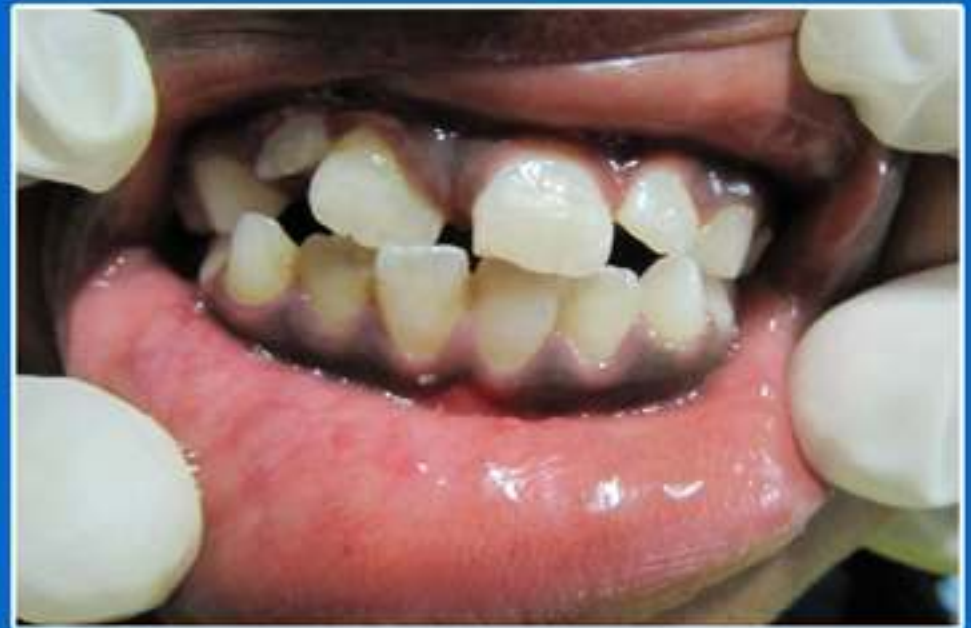*Maxillary Arch*



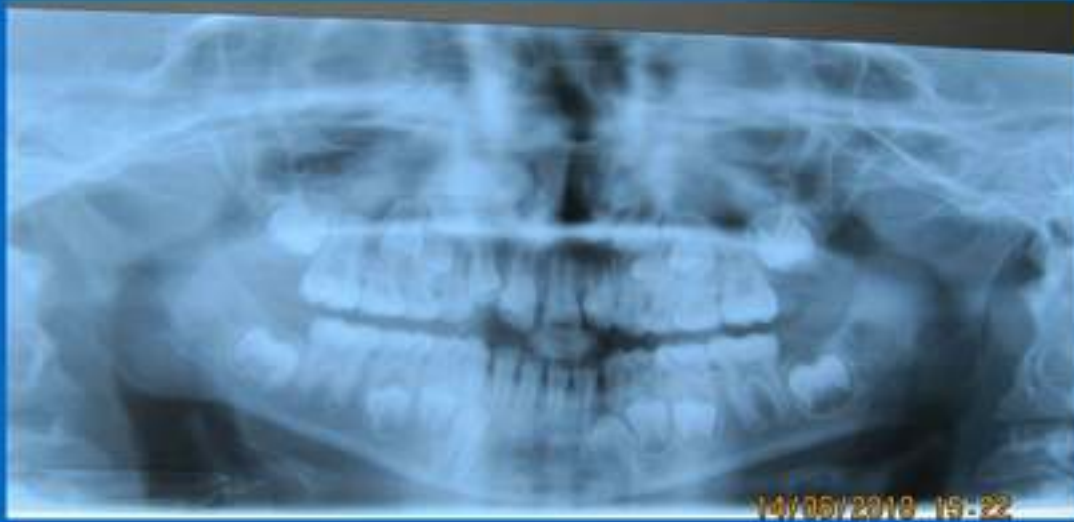*Mandibular Arch*



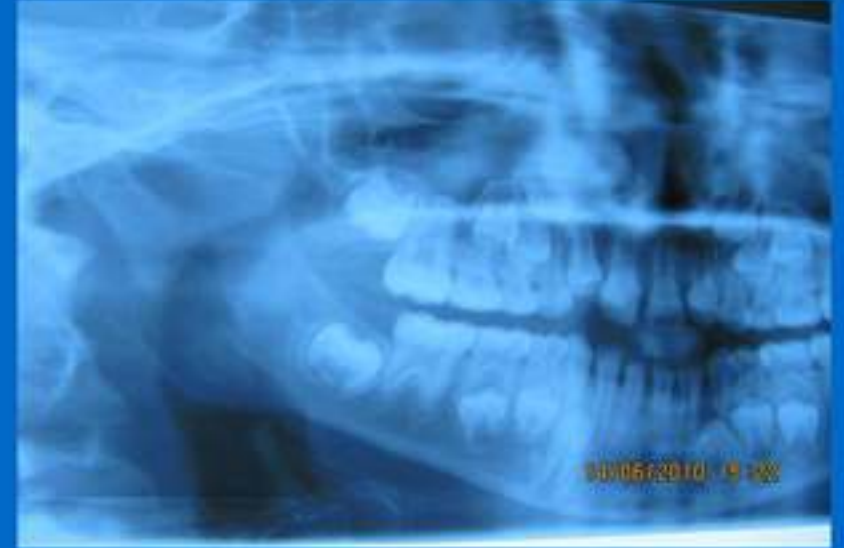*Tongue*



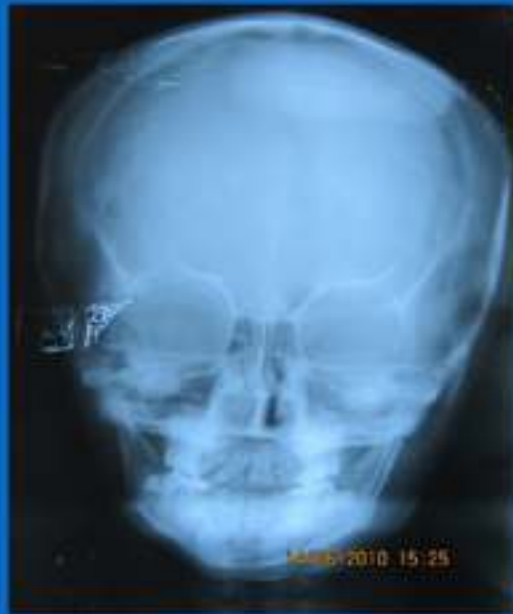# *Parry Romberg Syndrome*



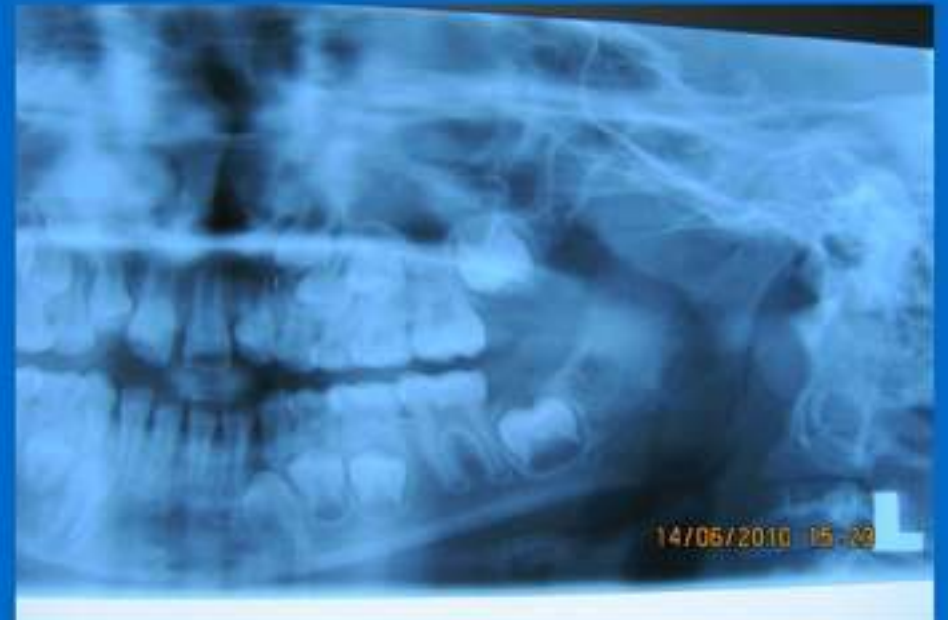*Orthopantomogram*



*OPT - Right Side*



*PA Skull*



*OPT - Left Side*

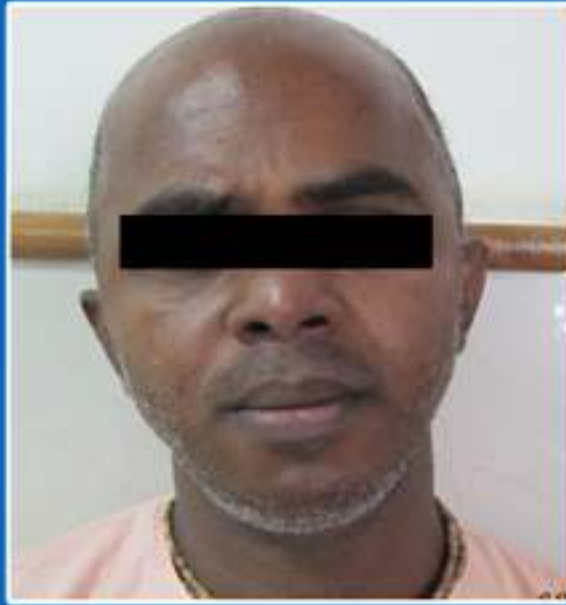*Patient Name: Mr.Chandrasekar*

*Age/sex: 38y/M*

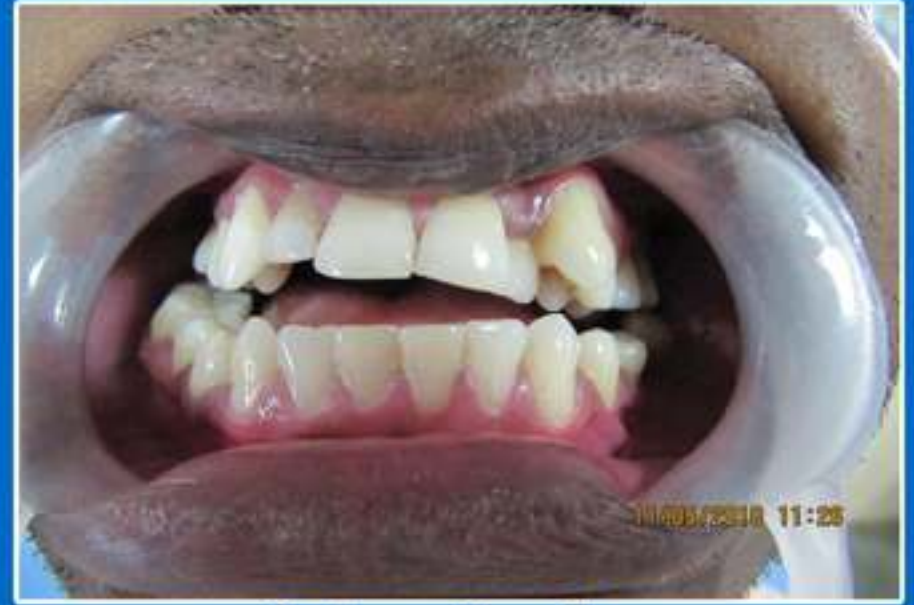*OP No: 201002220020*

*Diagnosis: Paget's Disease*

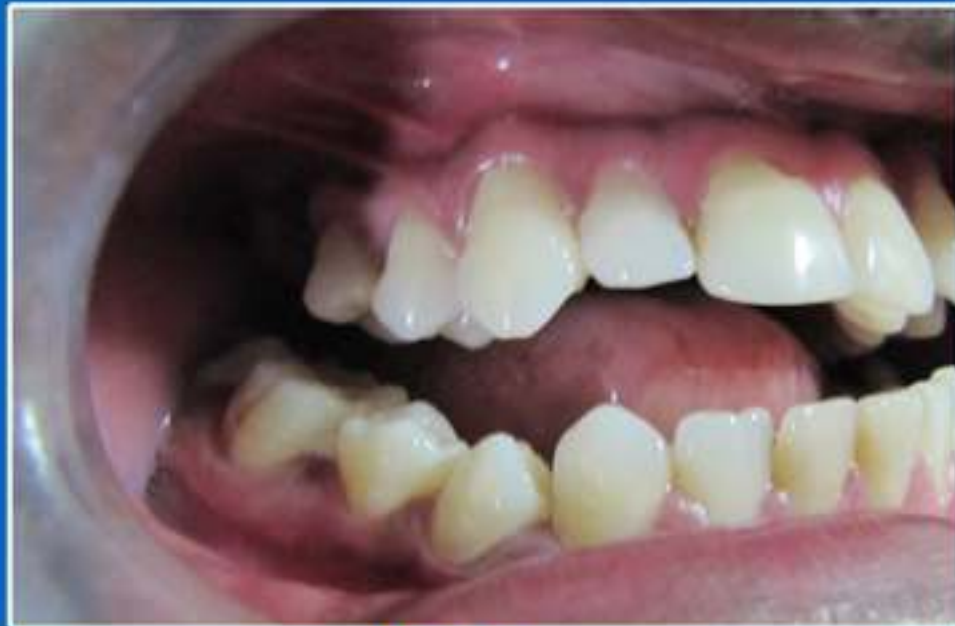# *Paget's Disease*



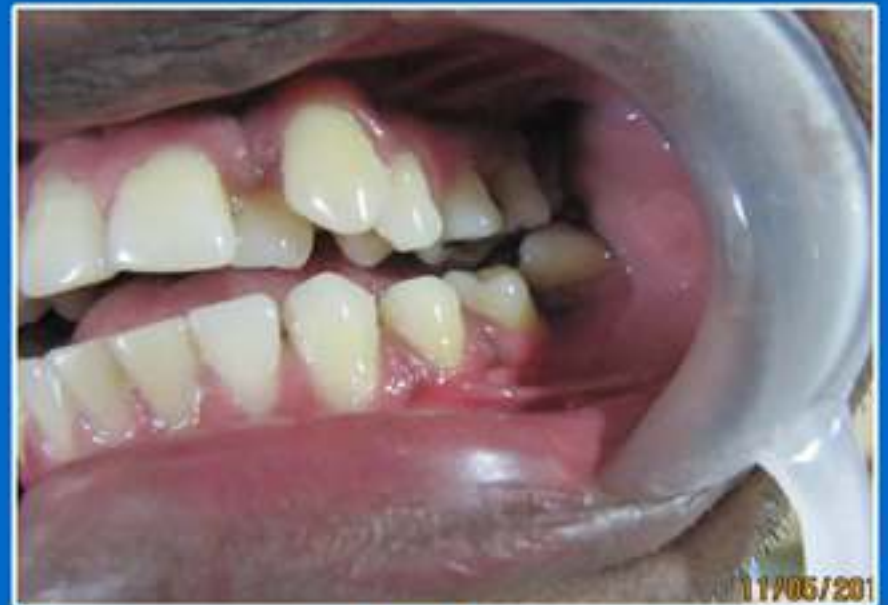*Profile*



*Intra Oral*

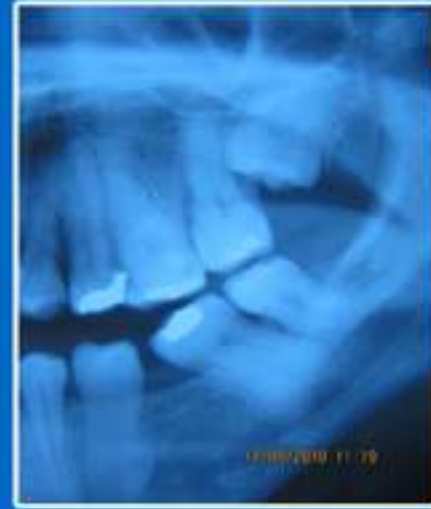
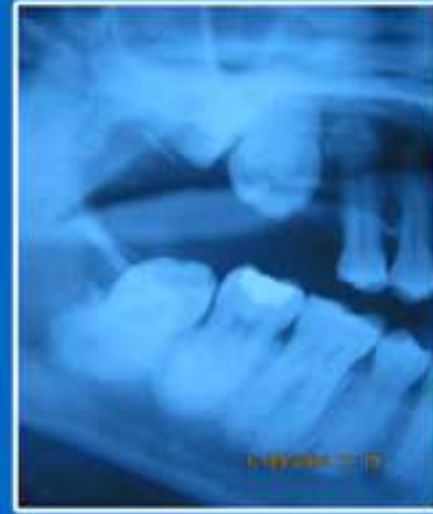
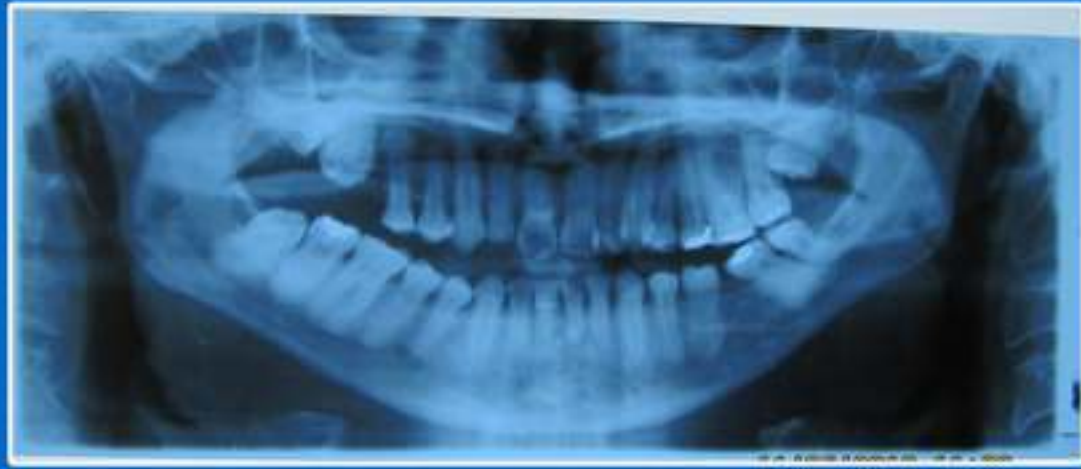*Right*

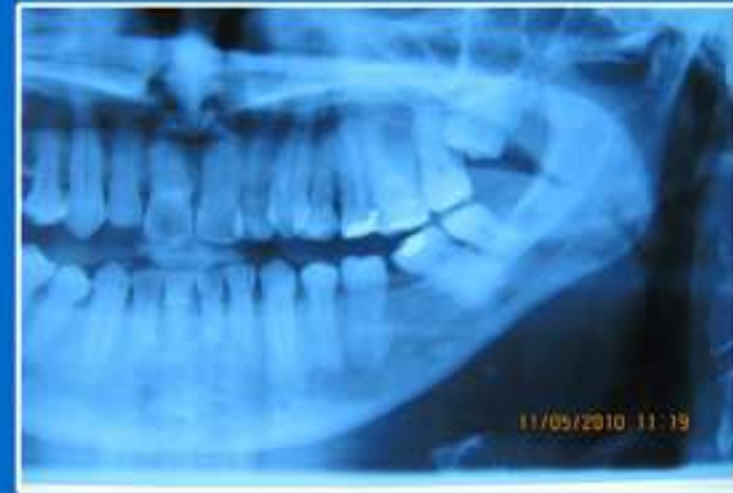
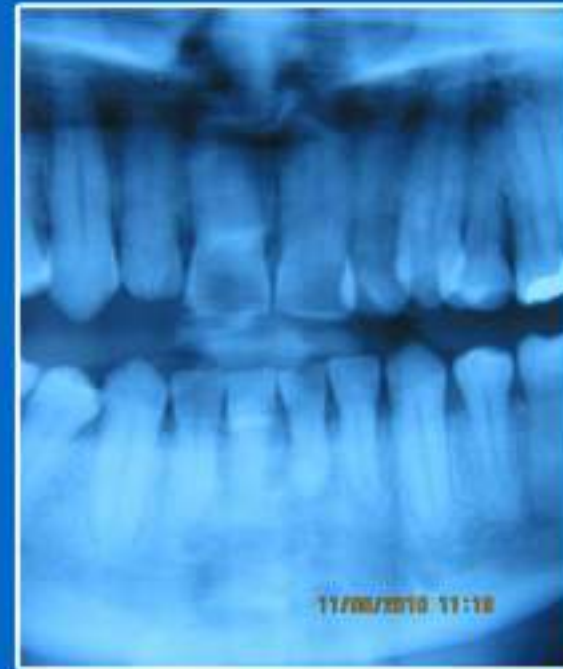
*Left*

# *Paget's Disease*



## *Orthopantomogram*



*Right*

*Left*

*Patient Name: Mr.Sengeni*

*Age/sex: 40y/M*

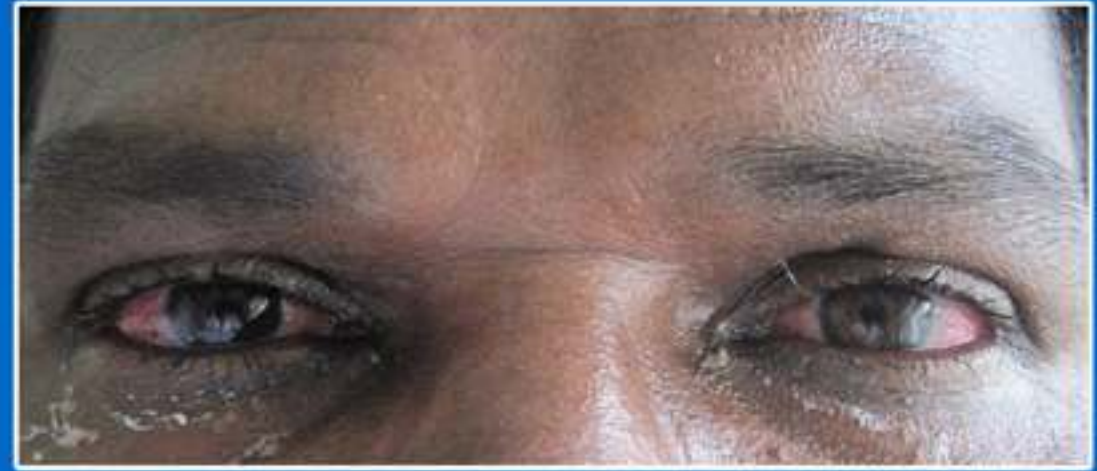*OP No: 201012270033*

*Diagnosis: Primary Sjogren's Syndrome  
(Sicca complex)*

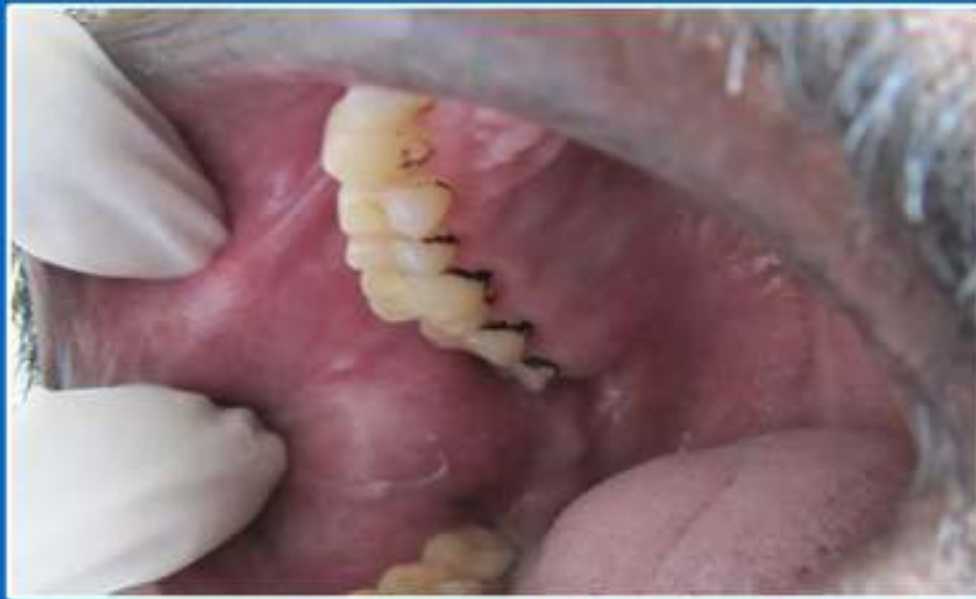# *Primary Sjogren's Syndrome (Sicca complex)*



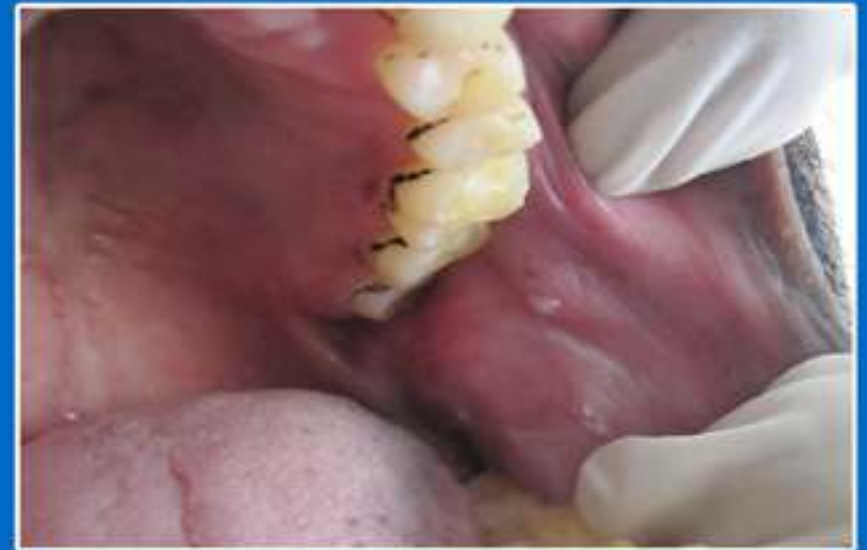*Profile*



*Keratoconjunctivitis*



*Right - Nil*



*Left - Turbid*

*Parotid Salivary Flow*

*Patient Name: Mrs.Latha*

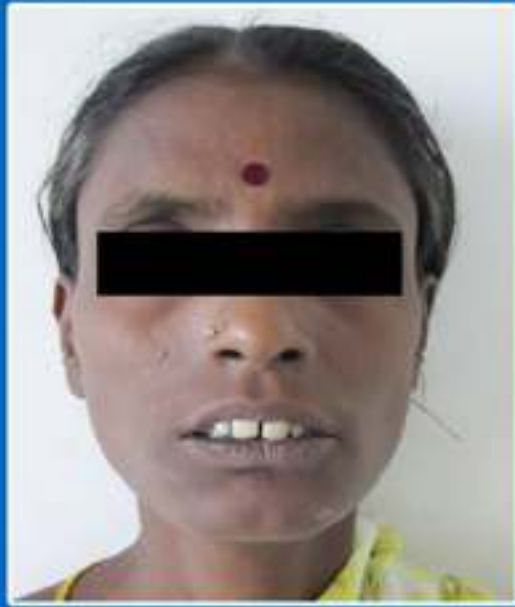*Age/sex: 34y/F*

*OP No: 201007070032*

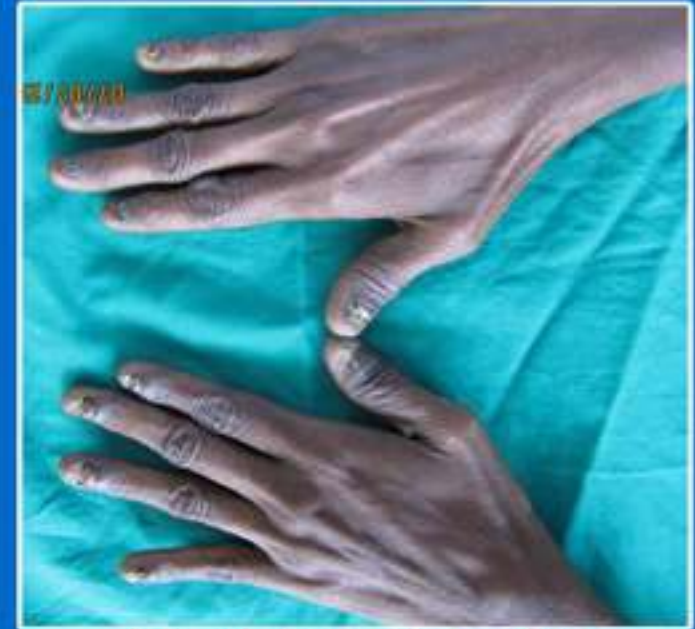*Diagnosis: Pachynochyia Congenita*



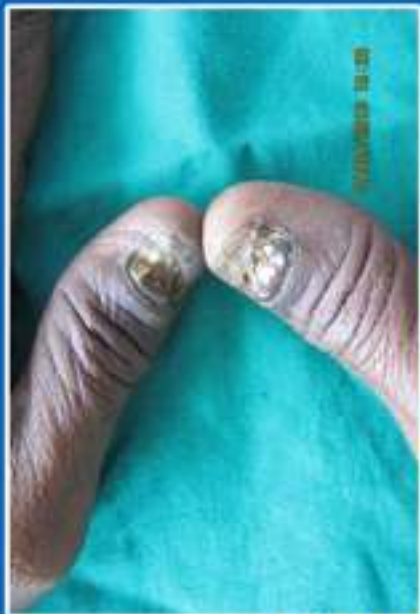# *Pachynochyia Congenita*



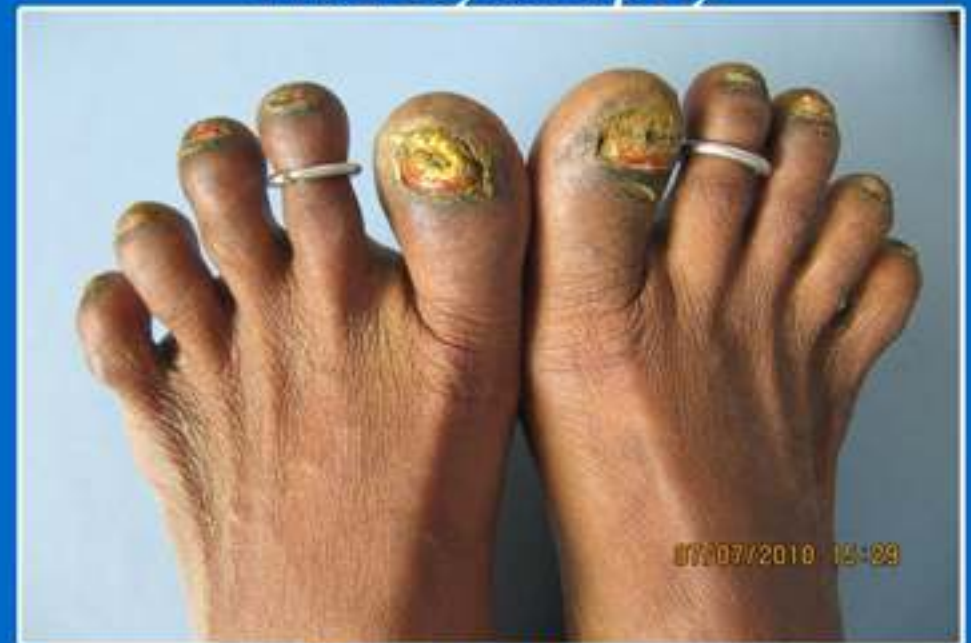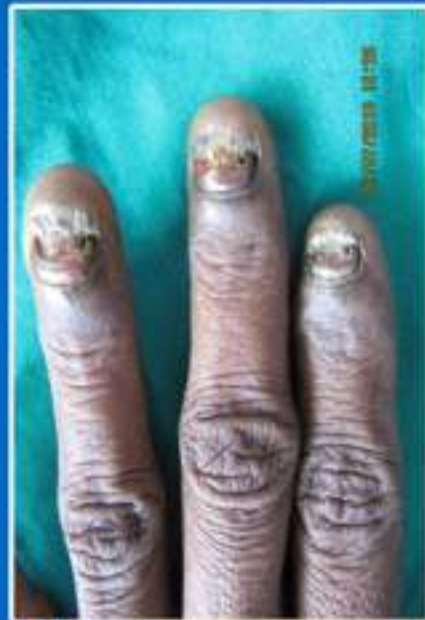*Profile*



*Nail Dystrophy*

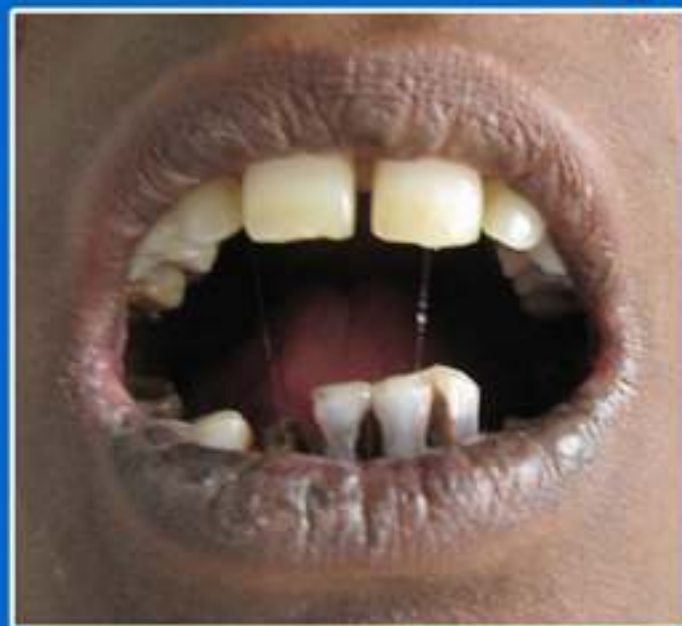

*Finger Nails*

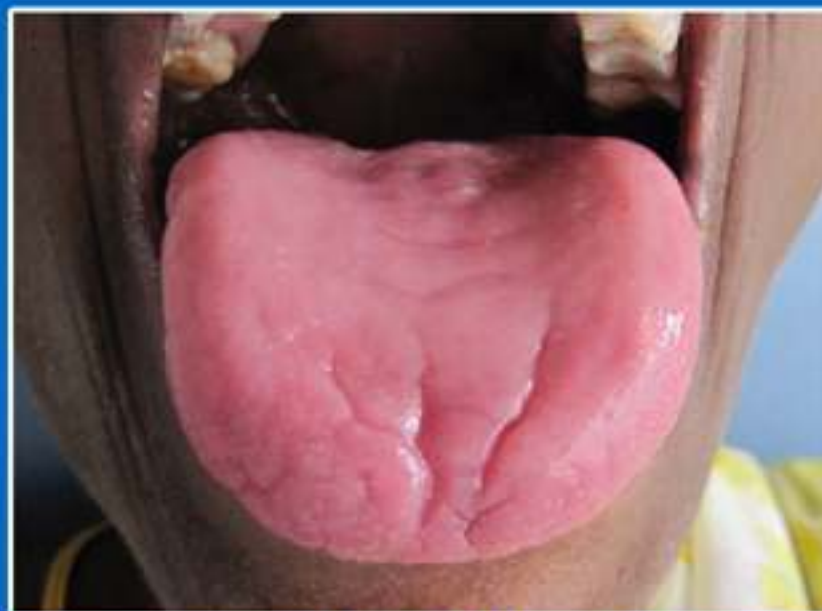
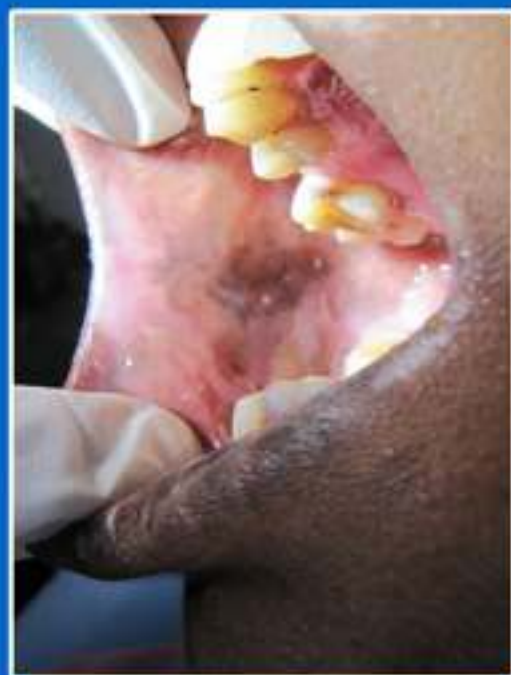
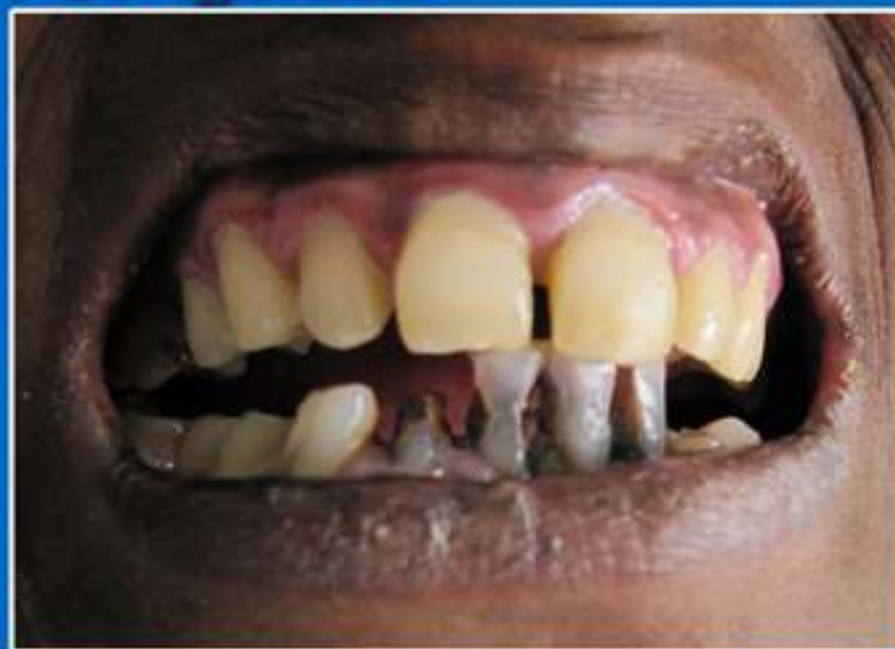*Toe Nails*

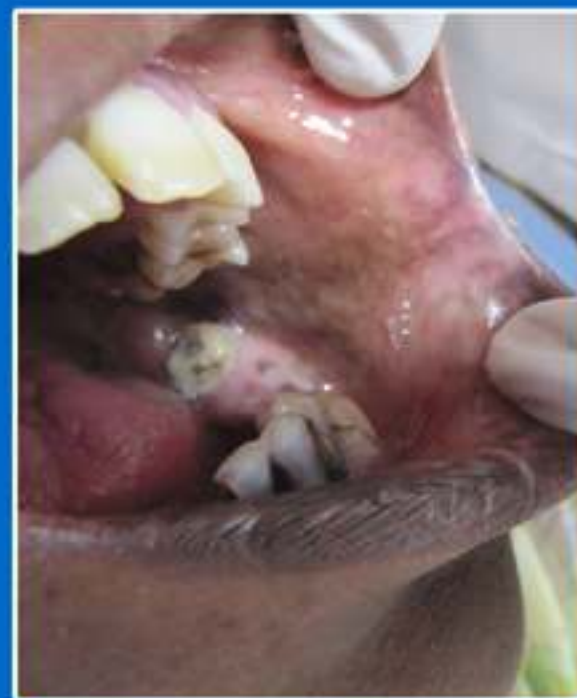# *Pachynochyia Congenita*



*Intra Oral*



*Bald Tongue*



*Patient Name: Ms.Anitha*

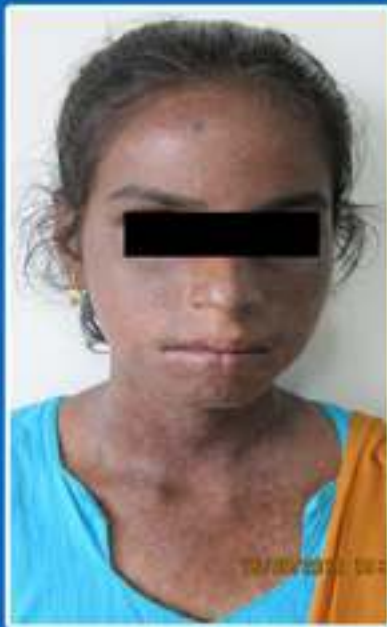*Age/sex: 9y/F*

*IP No: 090219086*

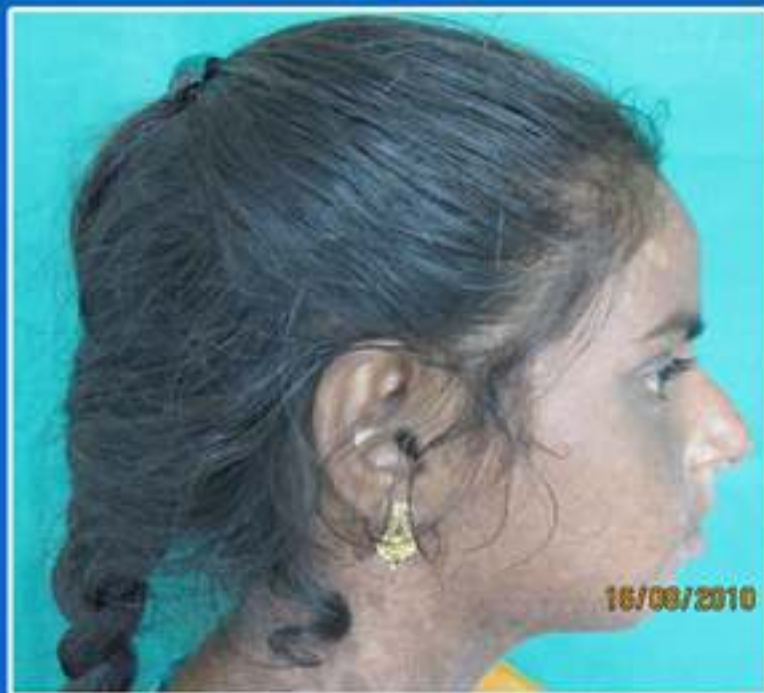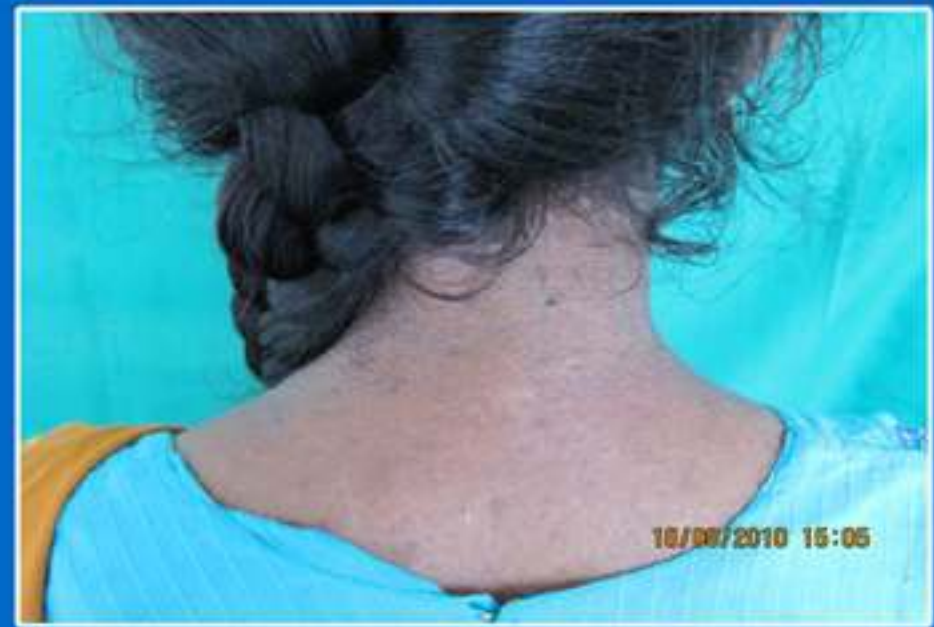*OP No: 201008120032*

*Diagnosis: Porphyria Cutaneous Tarda*

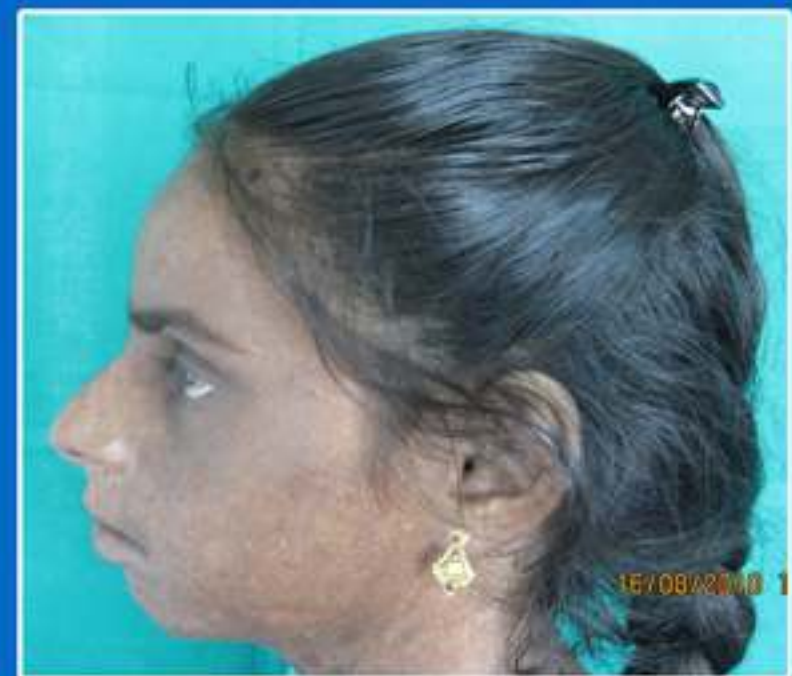# *Porphyria Cutaneous Tarda*



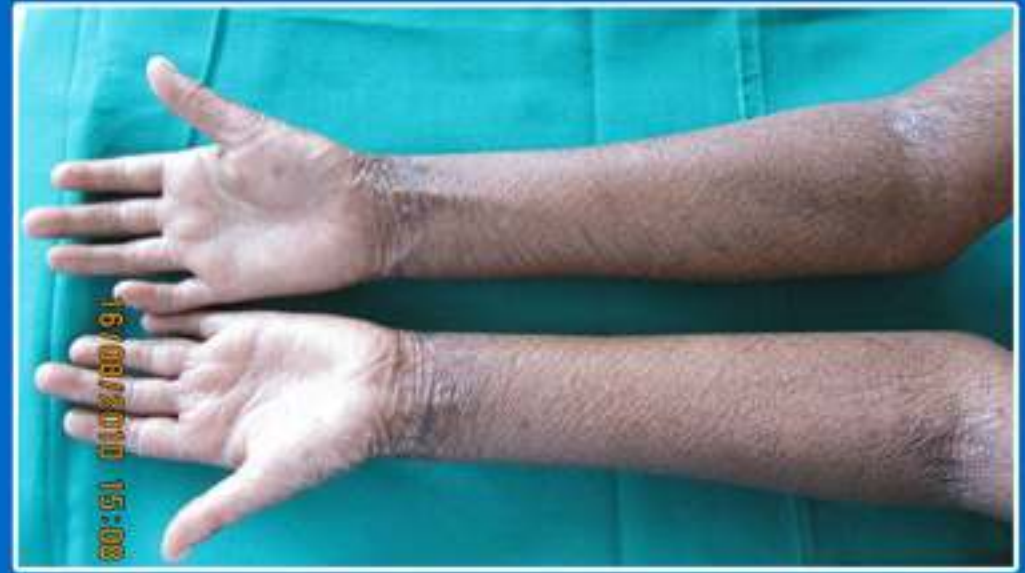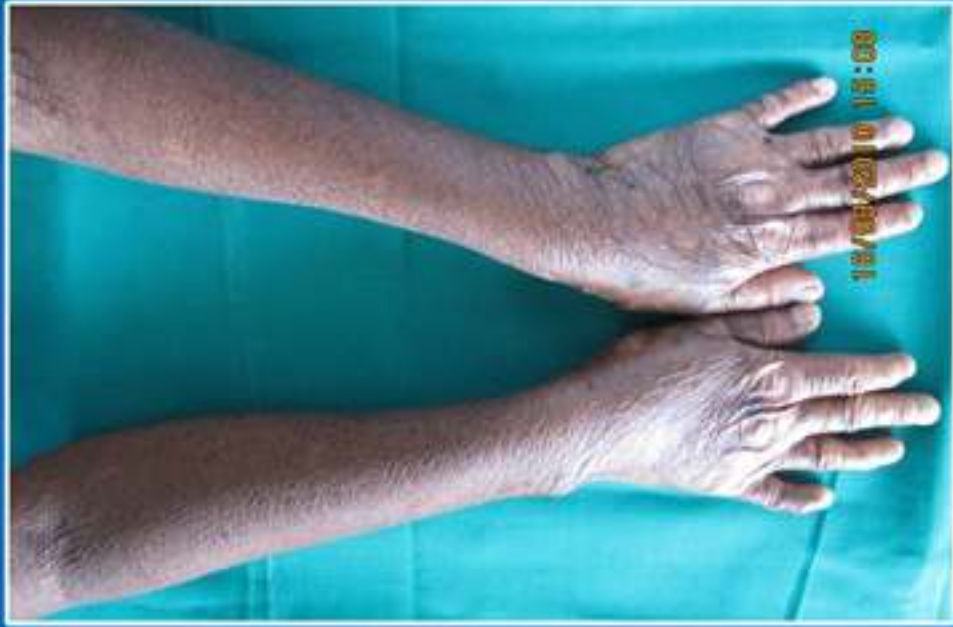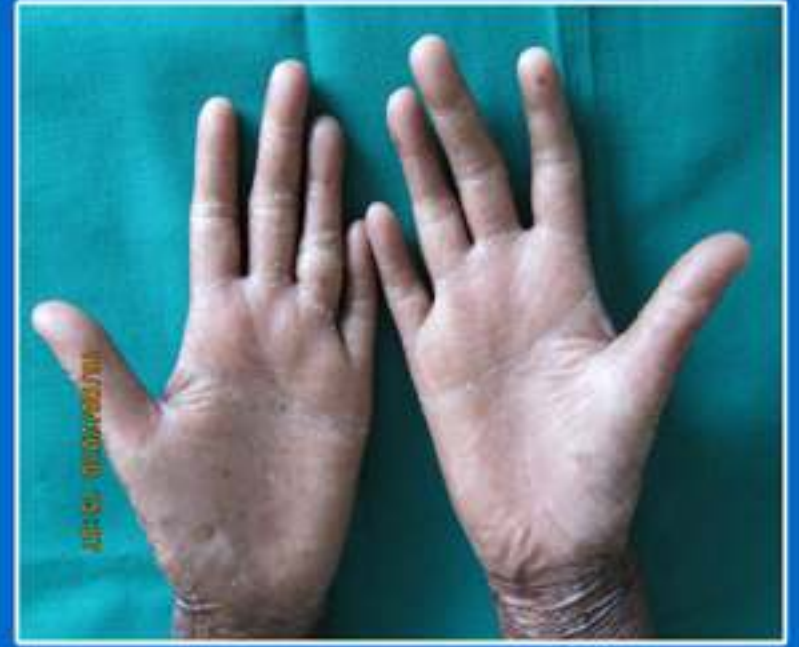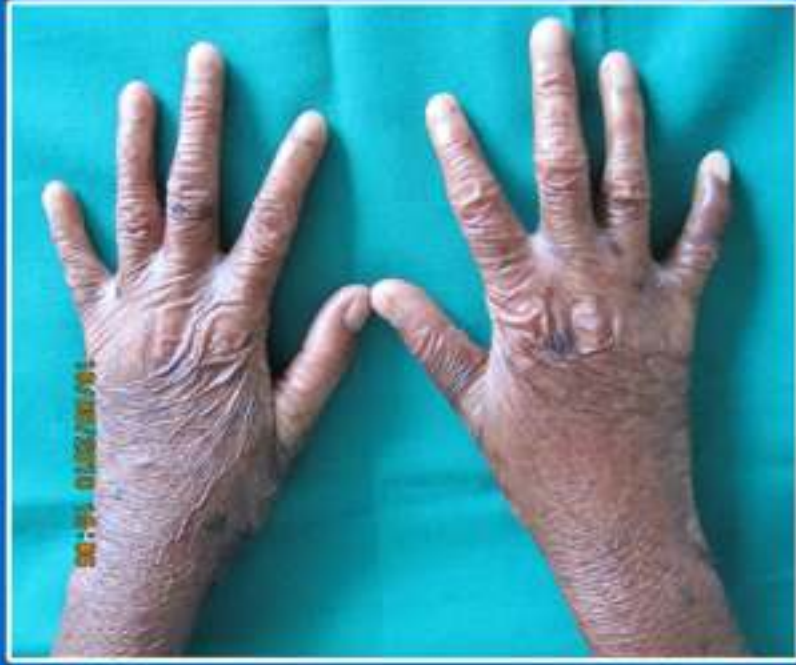*Profile*



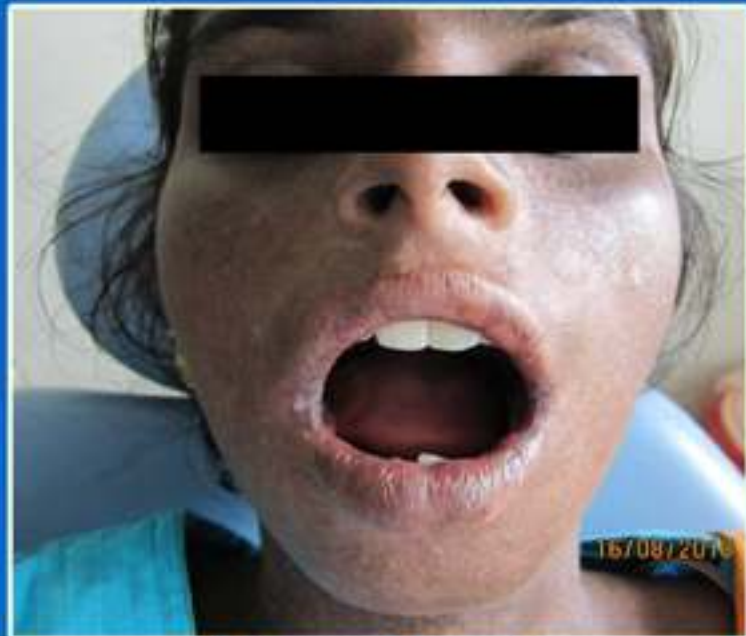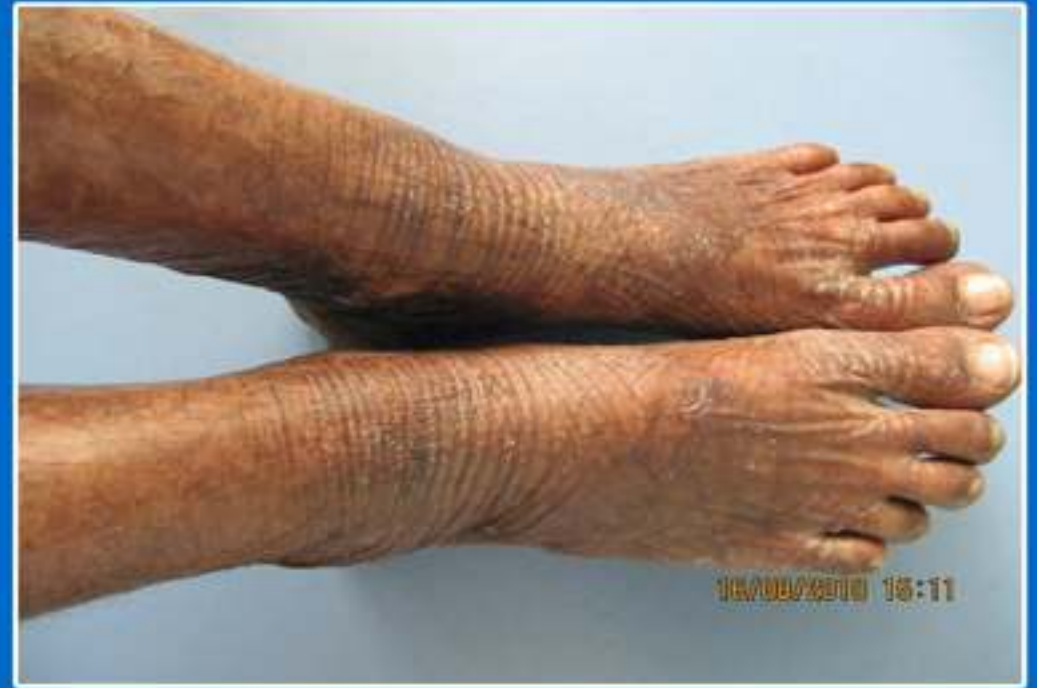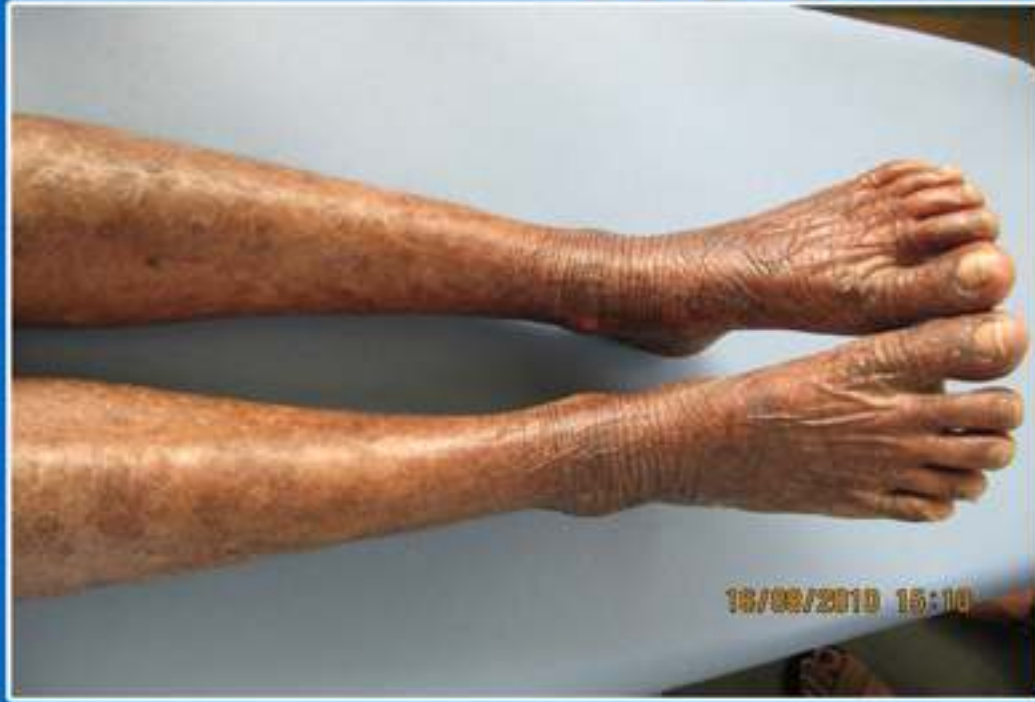*Lateral Profile*



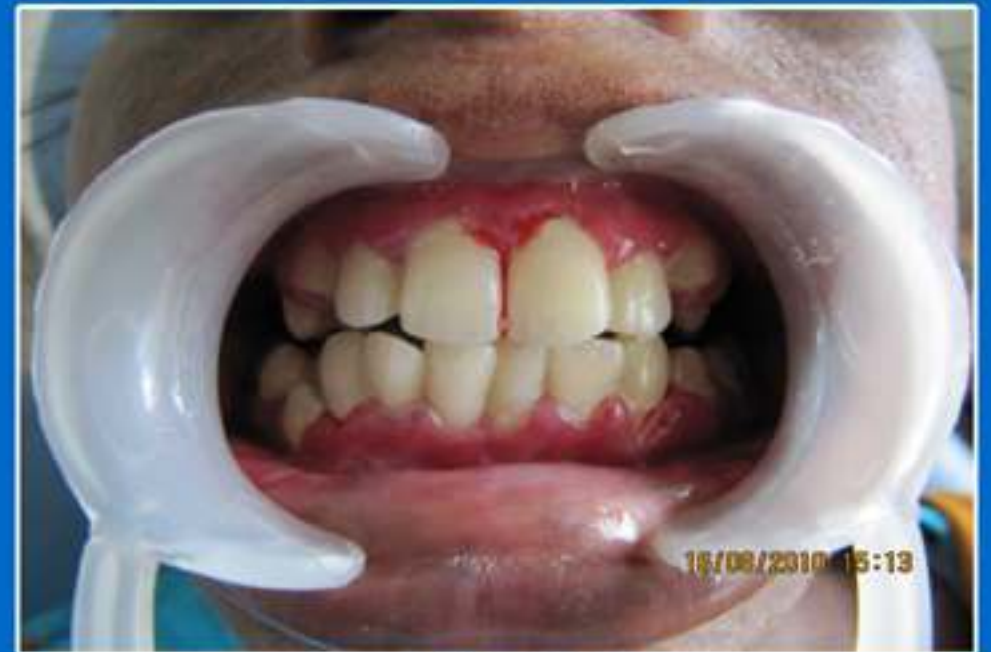# Porphyria Cutaneous Tarda



# *Porphyria Cutanea Tarda*

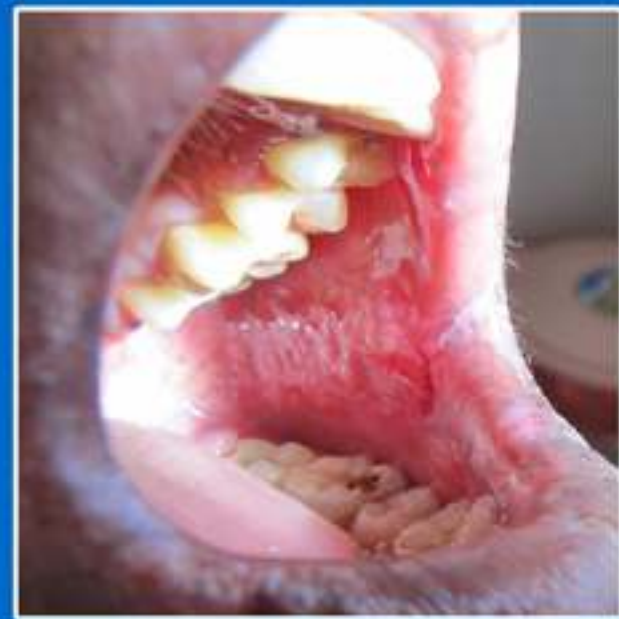
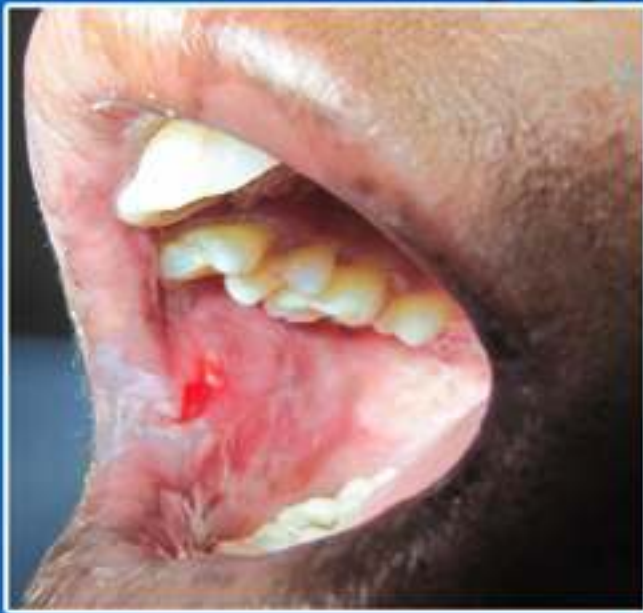
*Microstomia*

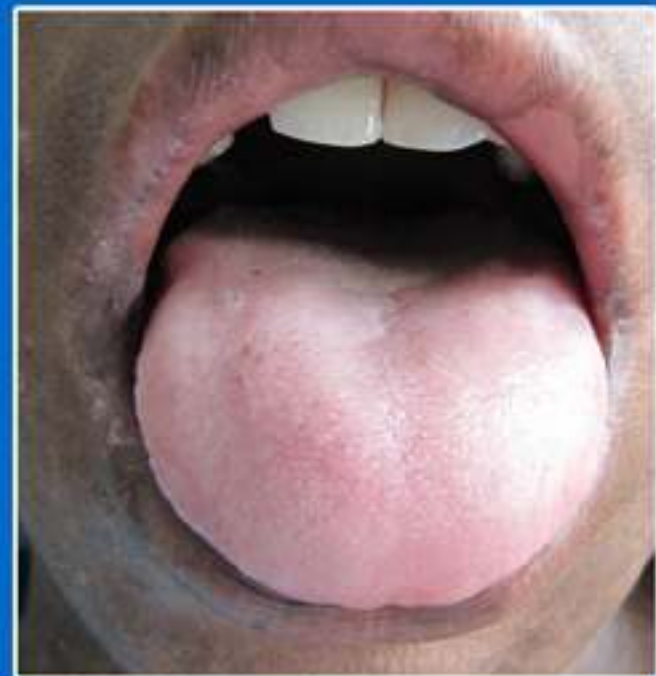
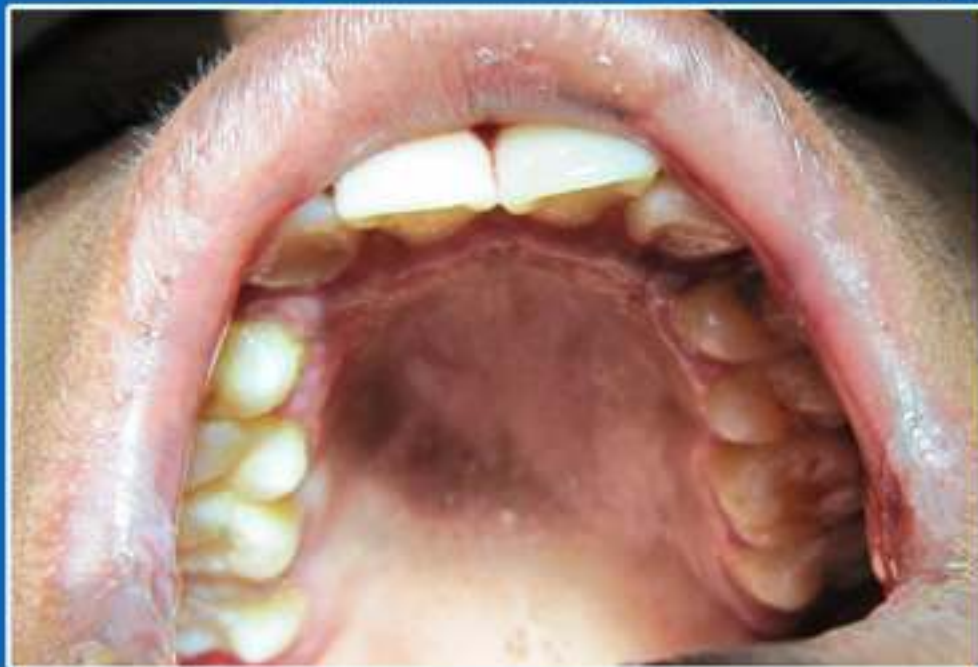
*Gingiva*

# *Porphyria Cutaneous Tarda*



*Intra Oral*



*Patient Name: Mr. Janakiraman*

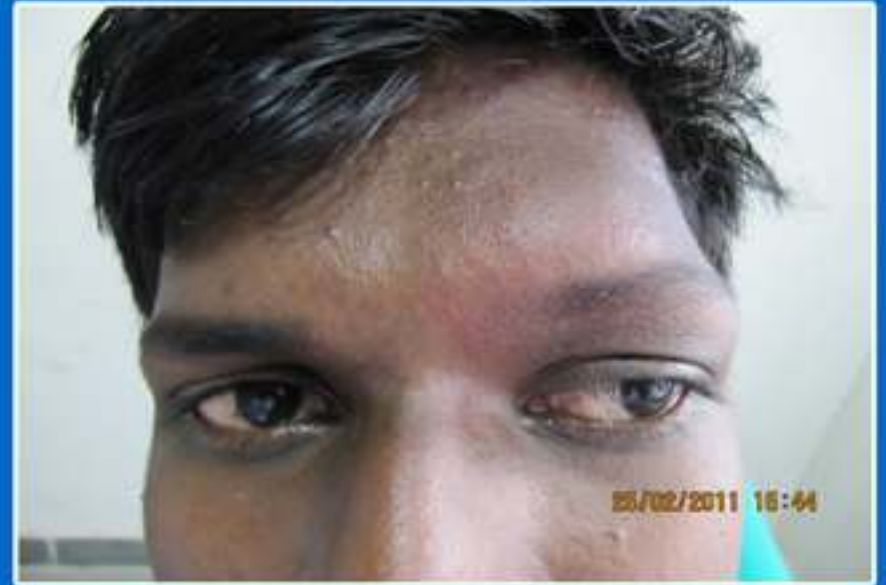*Age/sex: 19y/M*

*OP No: 201102250022*

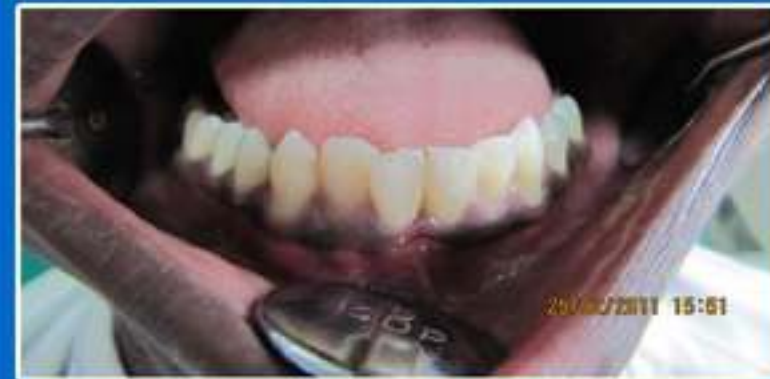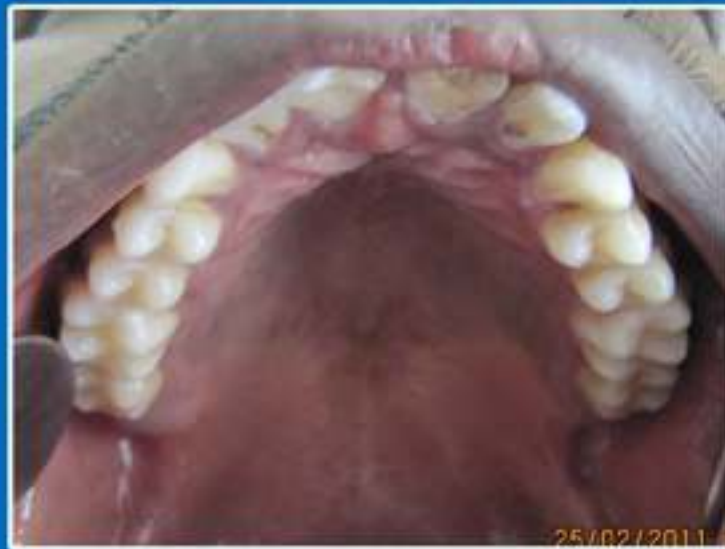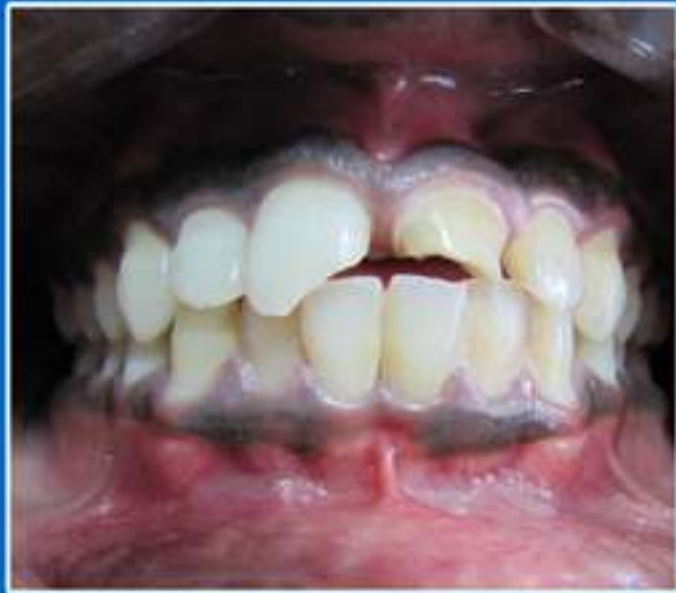*Diagnosis: Sturge Weber Syndrome*



# *Sturge Weber Syndrome*

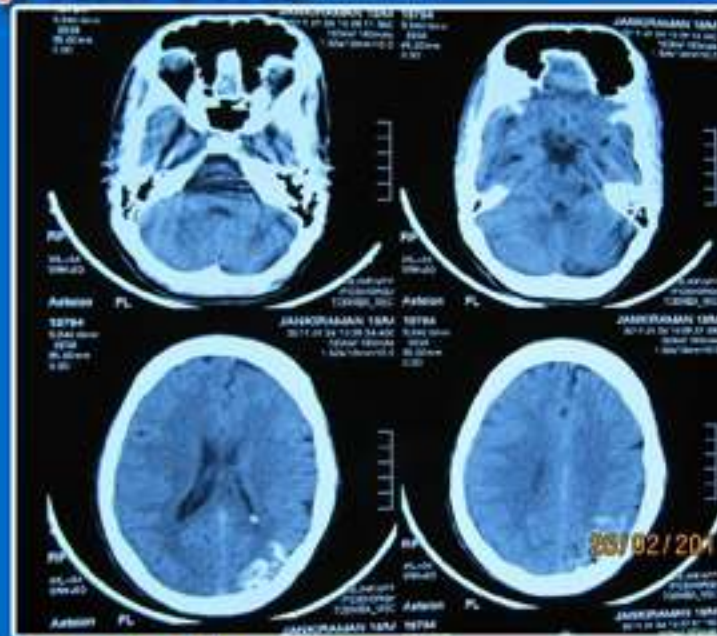
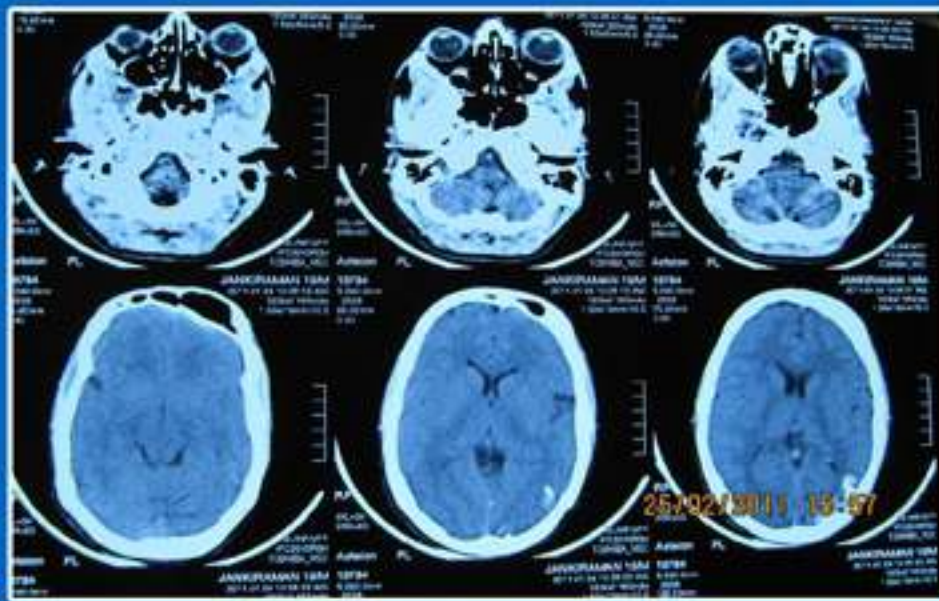


*Extra Oral - Unilateral Angiomatic Lesion*

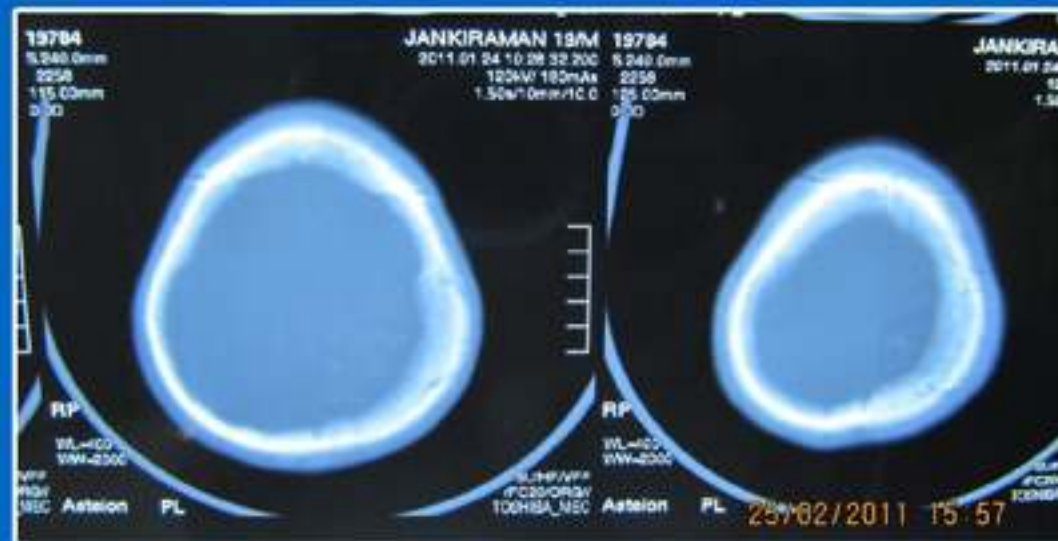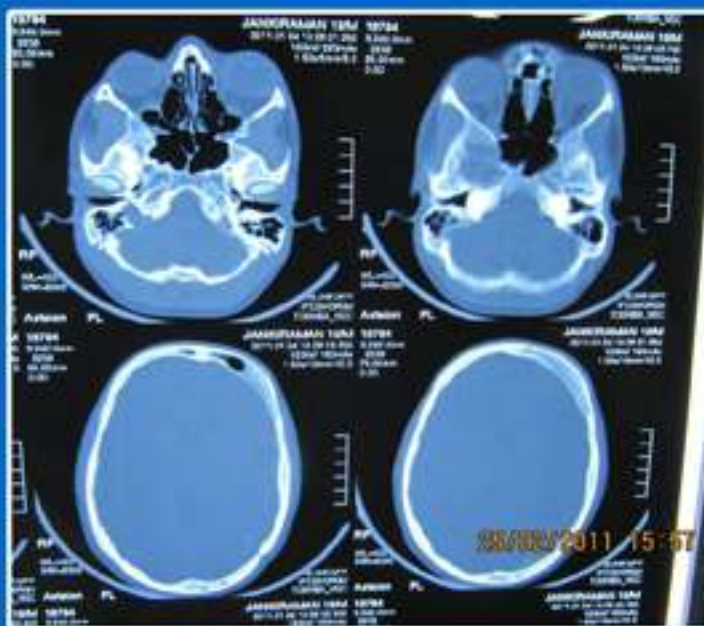


*Intra Oral - No Pathology*

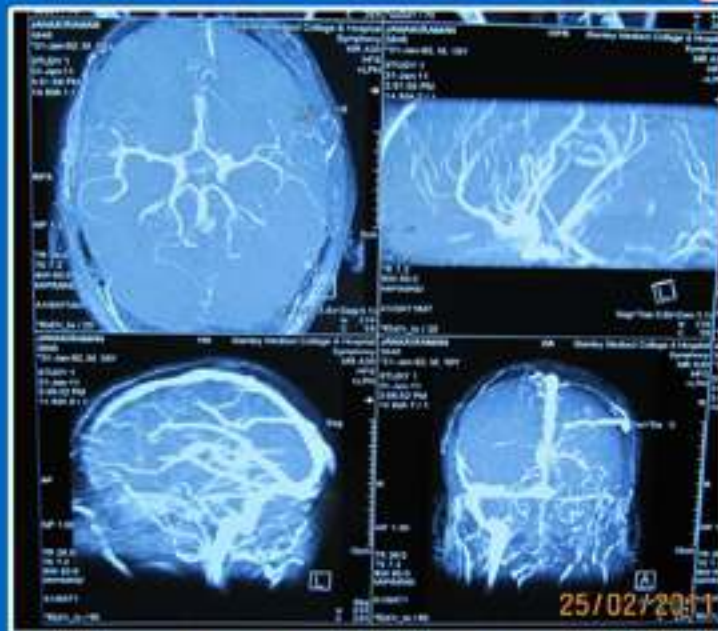# Sturge Weber Syndrome



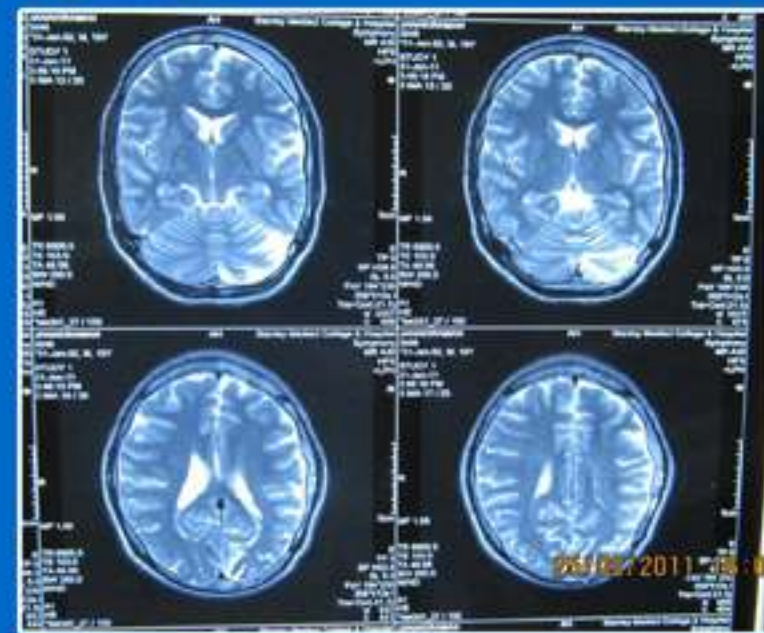
CT Brain - Tramline Calcifications



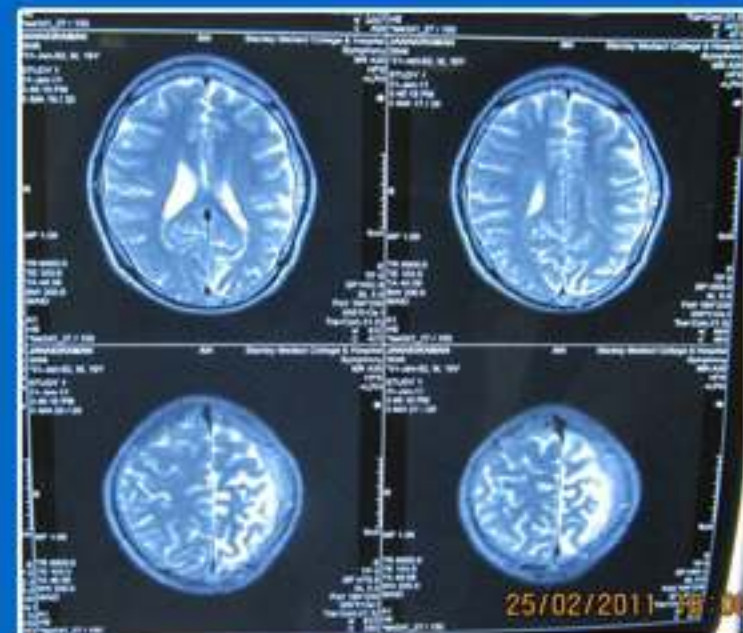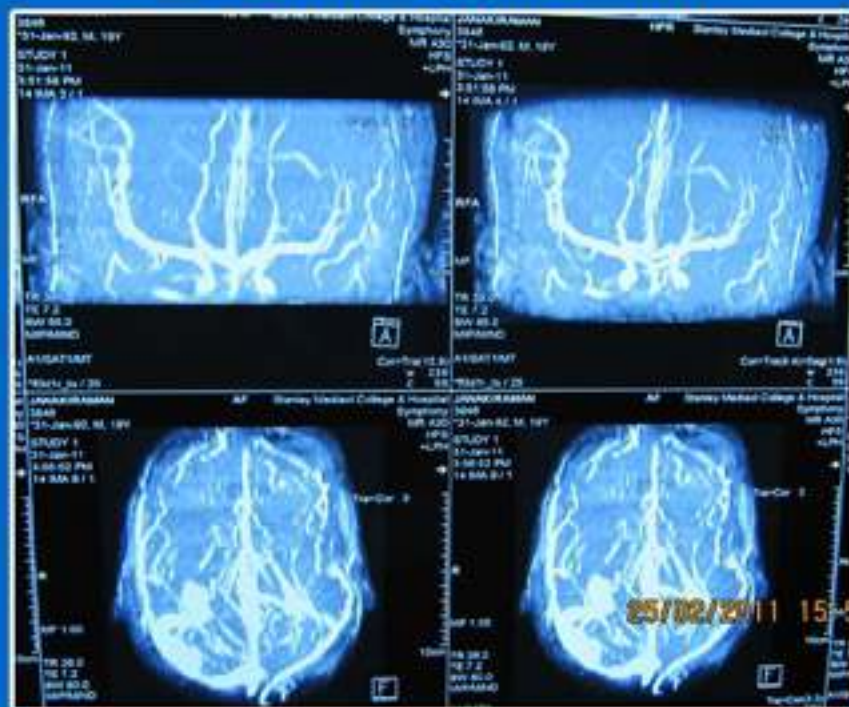
# Sturge Weber Syndrome



Cerebral Doppler Scan

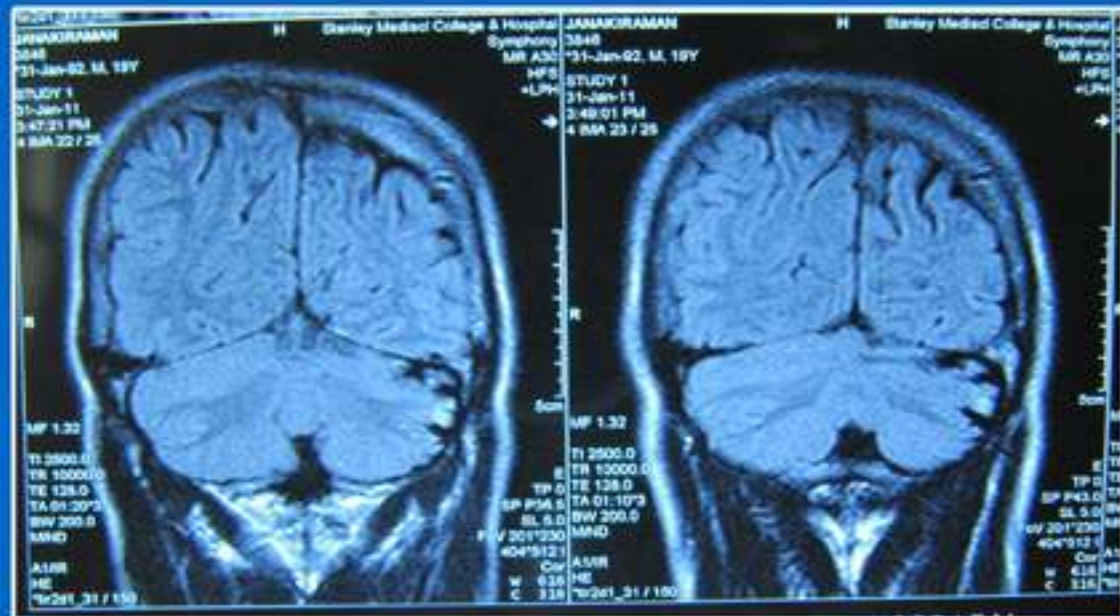
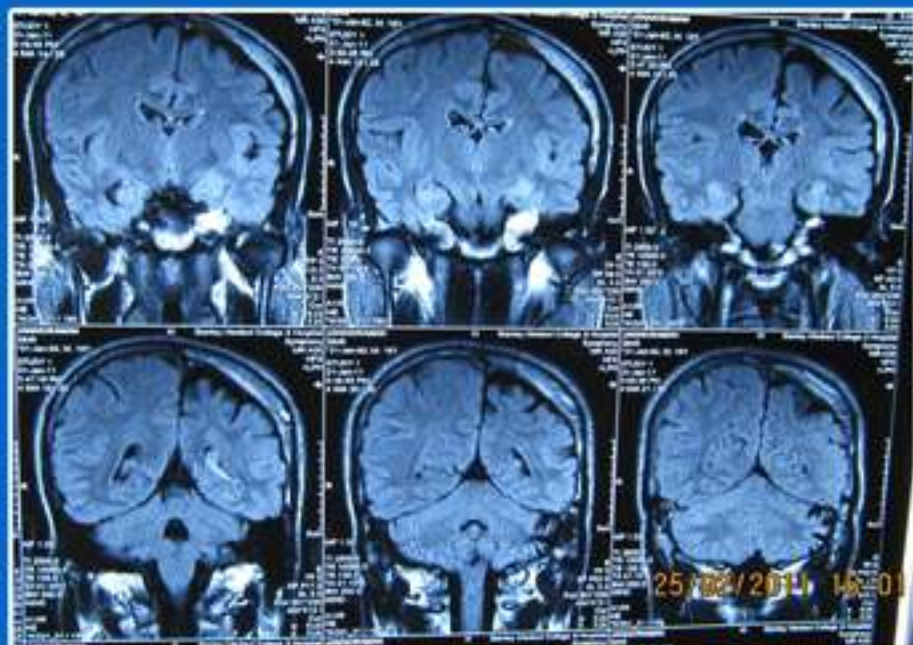


MRI Brain - Intra Cranial Calcification

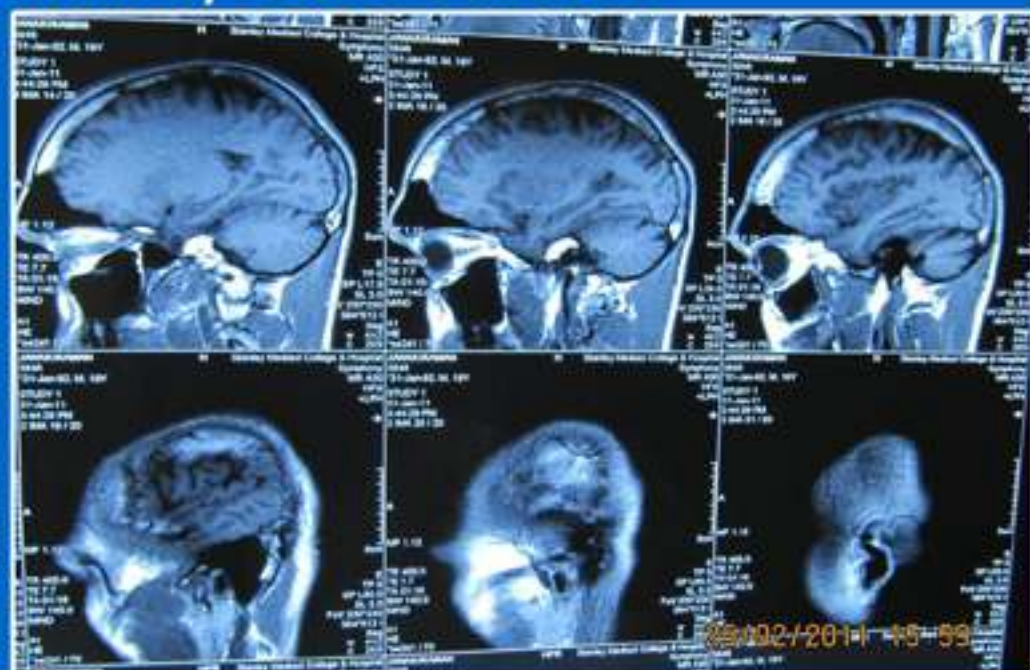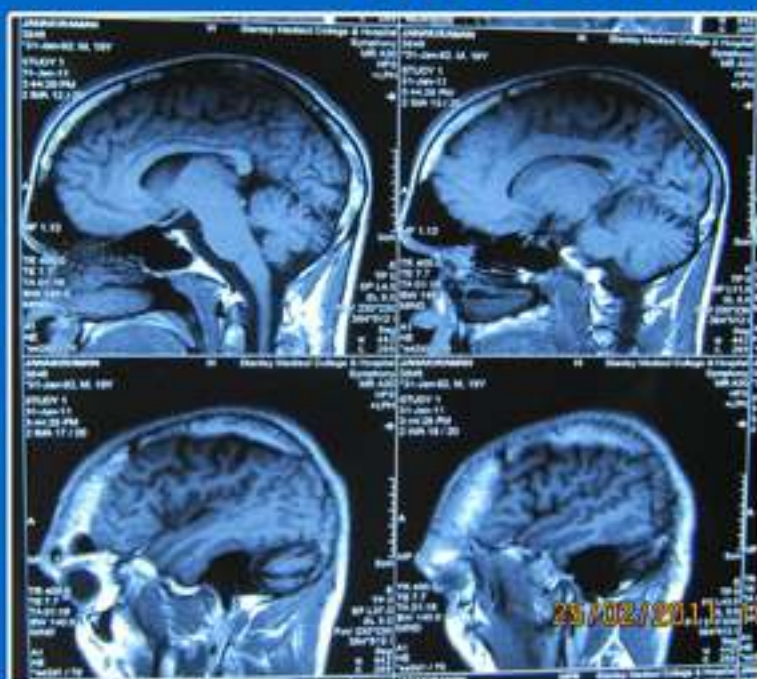


Axial Sections

# Coronal Sections



## MRI Brain - Calcification of Falx Cerebri



# Sagittal Sections

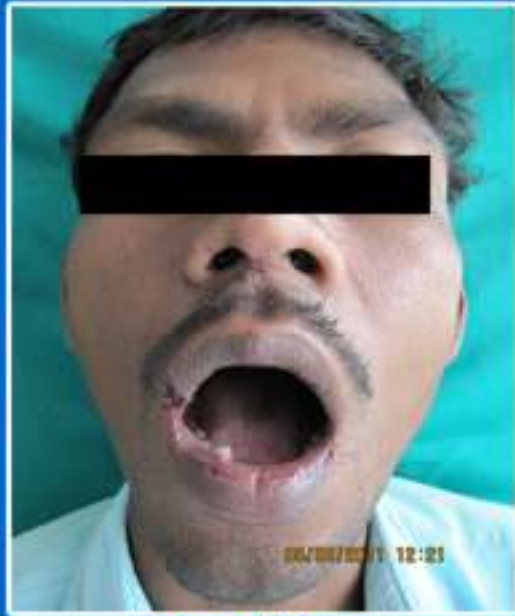*Patient Name: Mr.Ram bhajan*

*Age/sex: 30y/M*

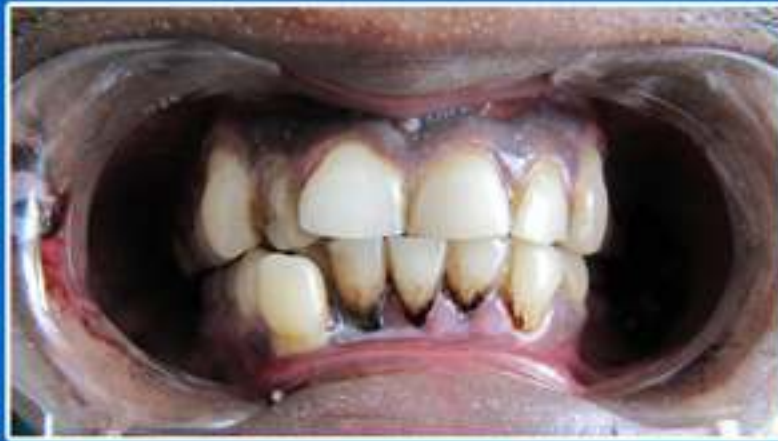*IP No: 090309635*

*Diagnosis: Idiopathic Thrombocytopenia*

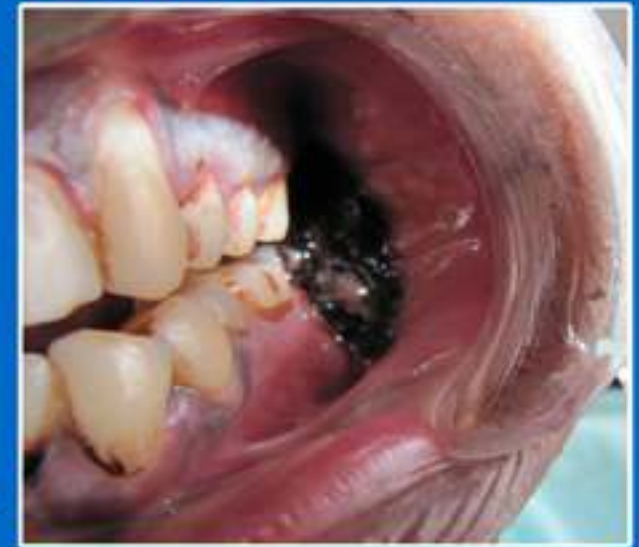# *Idiopathic Thrombocytopenia*



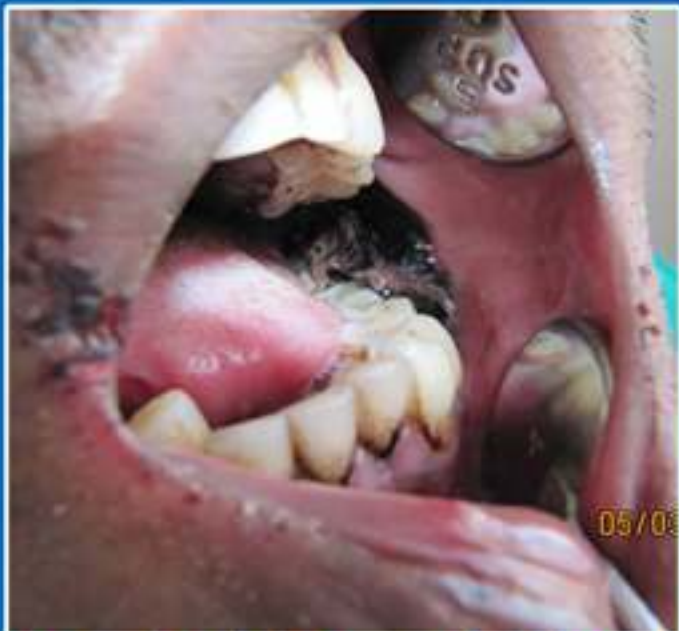*Profile*



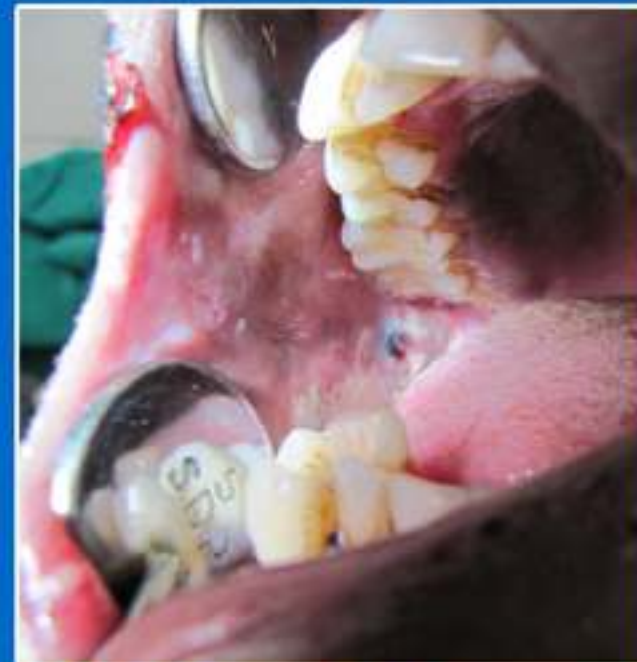*Gingival Bleeding*



*Intro Oral*



*Clot - Left Buccal Mucosa*



*Right Buccol Mucosa*

# Idiopathic Thrombocytopenia

**CHETTINAD HOSPITAL & RESEARCH INSTITUTE (A UNIT OF CARE)**  
 Rajiv Gandhi Salai, Kattavakkam, Kanchipuram District  
 Chennai-603103, Phone No: 044-47411000

**CHEMICAL LABORATORY - PATHOLOGY**

Name: RAM SHAJAN  
 Age: 30 Years (C/Male) (D/Dave)  
 Sex: Male  
 Source: In Patient

Referred By: G MED - GA  
 Hospital No: CARE/080200435  
 Order No: ICR000000124552  
 Ward Name: General Medicine Male 4

Car. No. M - 0204

Sample No.	Test	Result/Comment	Units	Normal	Methodology	Collected Time/Date
34612	CBC (COMPLETE BLOOD COUNT)					
	TOTAL LEUCOCYTE COUNT	2900	KMM	4000 - 11000	Electrical Impedance	3/3/2011 5:25:20PM
	WBC COUNT	4.72	Millions/cu mm	M: 4.5 - 6 F: 4.5 - 5	Electrical Impedance	3/3/2011 5:25:20PM
	HB (HAEMOGLOBIN)	14.4	G/DL	M: 11.1 - 17 F: 11.8 - 16	Cyanmethemoglobin	3/3/2011 5:25:20PM
	PCV	42.4	%	40 - 54	Electrical Impedance	3/3/2011 5:25:20PM
	MCV	89.5	FL	80 - 100	Calculated	3/3/2011 5:25:20PM
	MCH	30.5	PG	27 - 32	Calculated	3/3/2011 5:25:20PM
	MCHC	33.9	G/DL	33 - 38	Calculated	3/3/2011 5:25:20PM
	RDW	11.2	%	11.5 - 13.5	Calculated	3/3/2011 5:25:20PM
	PLATELET COUNT	0.30	LAC/CM	1.5 - 4	Electrical Impedance	3/3/2011 5:25:20PM
	NEUTROPHIL	61.9	%	40 - 75	Light Absorbance	3/3/2011 5:25:20PM
	EOSINOPHIL	0.6	%	1 - 8	Light Absorbance	3/3/2011 5:25:20PM
	BASOPHIL	1.5	%	0 - 1	Light Absorbance	3/3/2011 5:25:20PM
	LYMPHOCYTE	24.2	%	20 - 40	Light Absorbance	3/3/2011 5:25:20PM
	MONOCYTE	12.2	%	1 - 8	Light Absorbance	3/3/2011 5:25:20PM

Comments: NEUTROPHILS - LEFT SHIFT (+), TOXIC GRANULES (+)  
 ADV: REPEAT SMEAR AT SPKZ OF FEVER.  
 CBC - MALARIA.

34613 URINE ALBUMIN  
 URINE ALBUMIN (PROTEIN) ML 3/3/2011 11:53:00PM

34614 URINE SUGAR  
 URINE SUGAR NL Reagent Strip 3/3/2011 11:53:00PM

34615 DEPOSITS (URINE)  
 URINE WBC (PUS CELLS) OCCASION SEEN Microscopy 3/3/2011 11:53:00PM  
 URINE EPITHELIAL CELLS 1-CELLS/HPF Microscopy 3/3/2011 11:53:00PM  
 URINE RBC NL Microscopy 3/3/2011 11:53:00PM  
 URINE CASTS NL Microscopy 3/3/2011 11:53:00PM  
 URINE CRYSTALS NL Microscopy 3/3/2011 11:53:00PM

05/03/2011 13:24

Page 1 of 2

## Investigation

**DEPARTMENT OF RADIOLOGY & IMAGING**

Super: Mr. Ram Shajam Age / Sex: 36/M  
 Ref: No: CARE/080200435  
 Ref by: M/MD

**ULTRASONOGRAPHY OF ABDOMEN**

**Liver** : The liver is normal in size. The parenchymal echotexture is homogeneous. No evidence of any focal lesions. The intra hepatic biliary system is normal. There is no evidence of intra or extra hepatic biliary ductal dilatation.

**Gall Bladder** : The Gall Bladder is normal in size and contour with normal wall thickness. There is no evidence of calculus or sludge.

**Spleen** : The spleen is normal in size and echotexture.

**Pancreas** : Normal in size and echotexture with well defined contour.

**Kidney** : Both kidneys are normal in size and echotexture. The Right kidney measured: 10.2 x 3.7 cm. Cyst of size 1.0 x 1.0 cm noted in inferior pole of right kidney. The Left kidney measured: 11.1 x 3.0 cm. No evidence of calculi or caliectasis.

**Bladder** : The Urinary Bladder is normal in size and contour with normal wall thickness. No evidence of calculus or tubal ectasis.

**Prostate** : The Prostate is normal in size (vol- 13 cc) and echotexture. The capsule is intact.

No evidence of free fluid in the abdomen.

DIAGNOSIS: \* No significant abnormality detected.

LICENCE No. 275  
 60mi

**Chettinad Hospital & Research Institute**  
 Rajiv Gandhi Salai, Kattavakkam, Kanchipuram Dist - 603 103

**PLATELET CONCENTRATE USP (30-40ML)**  
 Prepared from blood collected with anticoagulant Citrate Phosphate Dextrose adenine solution U.S.P. 43ML. Whole blood 350 ml

BAG NO.	COLLECTION DATE	EXPIRY DATE
529/11	28/2/11	5/3/11

**INSTRUCTIONS:**

- Do not use if there is any visible evidence of deterioration.
- Storage temperature 20 to 24 degree centigrade.
- Do not add any medication.
- Use a fresh, clean, sterile transfusion set with filter.
- Do not dispense without prescription.
- Check blood group on the label and recipient blood group before administration and properly identify intended recipient.
- Should be administered immediately (Transfuse within 4 hours after receiving the unit).
- Shelf life 8 days from collection.
- Transfusion Citrate RBC and Rh compatible, if possible.

**BLOOD GROUP**

**B**

Rh<sub>0</sub> (D)

Pos

SCREENED: NEGATIVE / NON REACTIVE FOR: HBsAg, Anti HCV, Anti HIV 1 & 2, MP & VDRL.

PREPARED FROM A VOLUNTARY / REPLACEMENT BLOOD DONOR.

## Treatment

*Patient Name: Mrs.Rani*

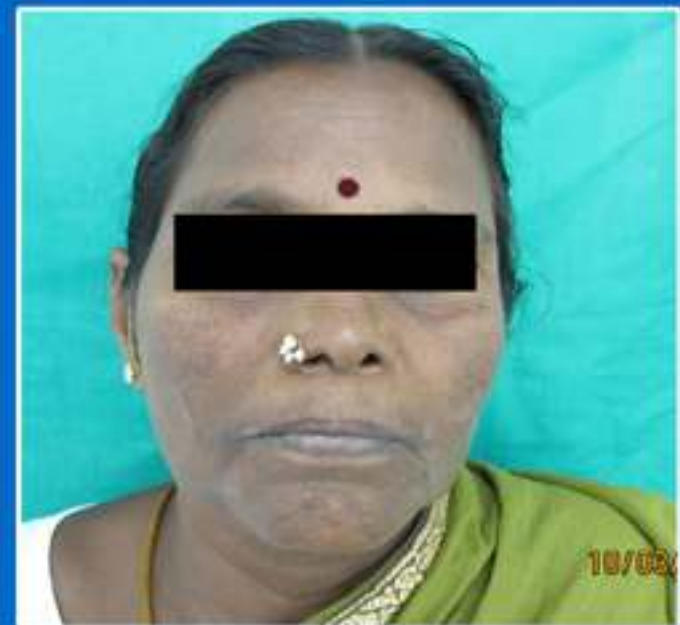*Age/sex: 57y/F*

*OP No: 201103090025*

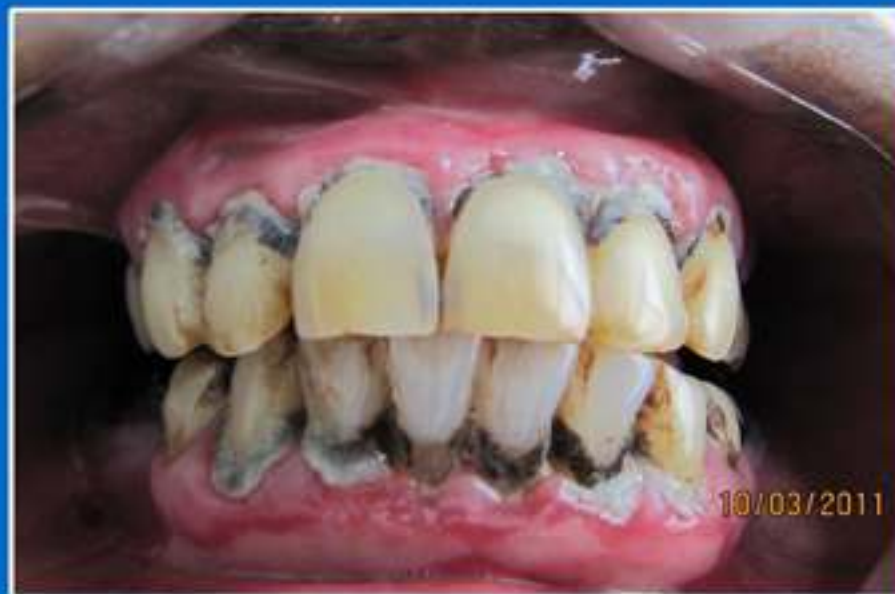*Diagnosis: Pemphigoid*



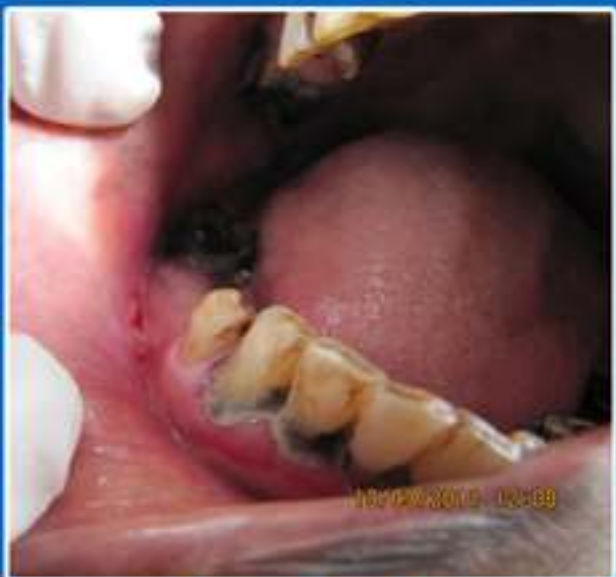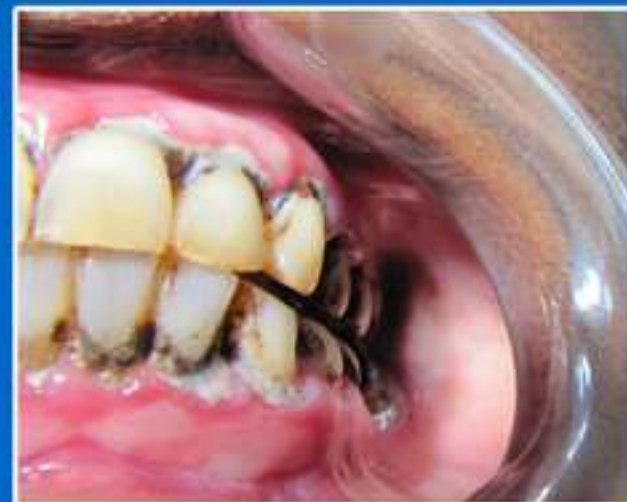# *Pemphigoid*



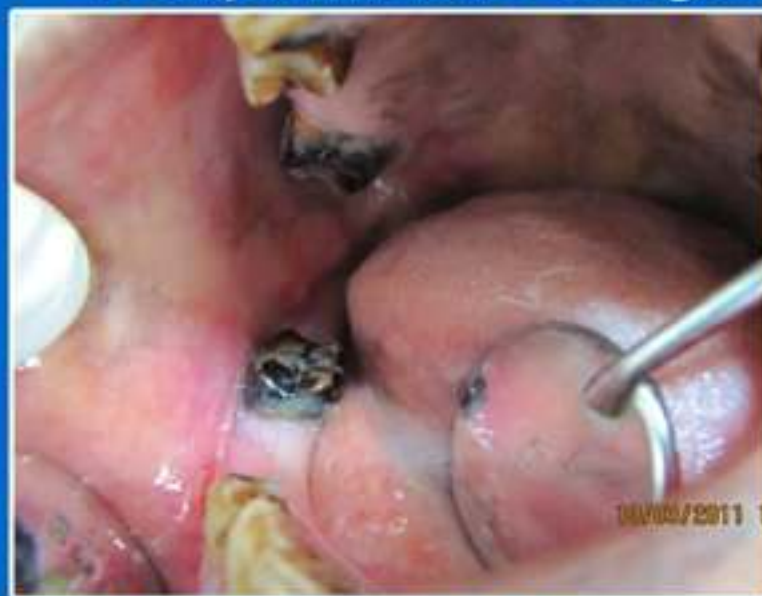*Profile*



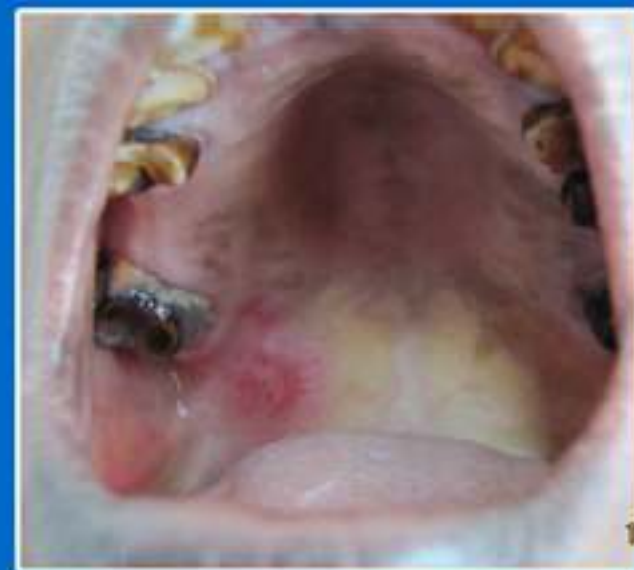*Desquamative Gingivitis*



*Vestibule*



*Right Buccal Mucosa*



*Palate*

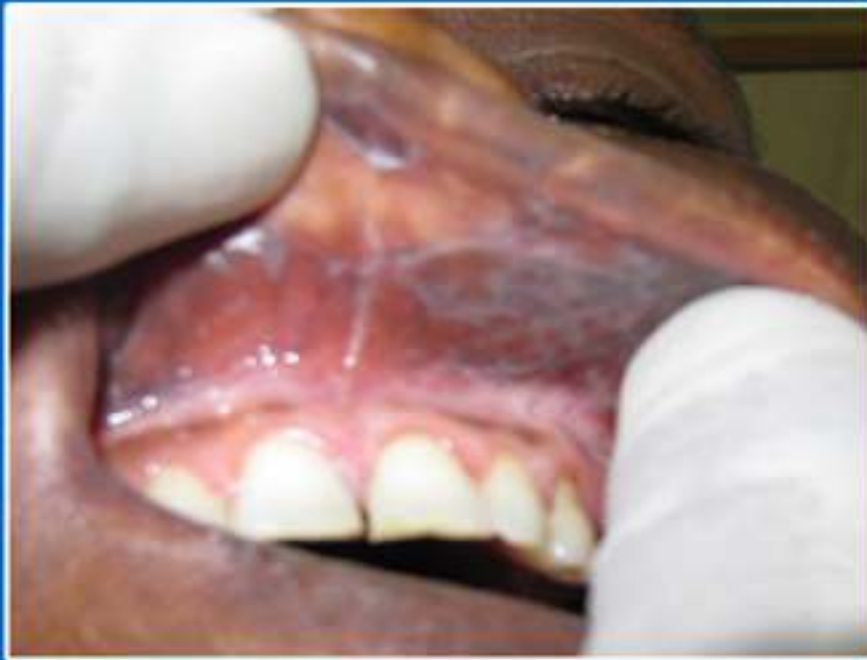*Patient Name: Mrs.Indira*

*Age/sex: 36y/F*

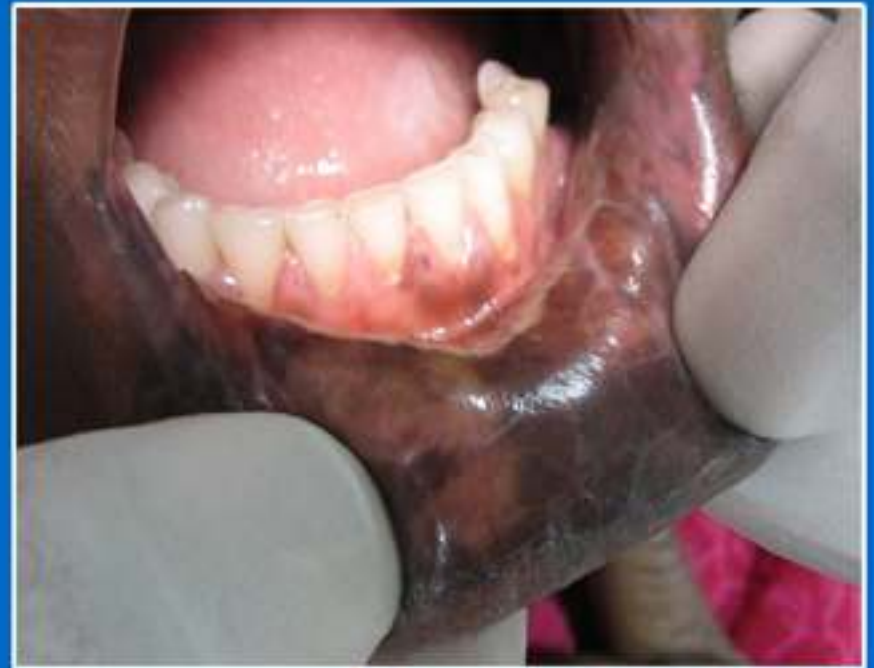*OP No: 201002230022*

*Diagnosis: Oral Lichen Planus*

# *Oral Lichen Planus*

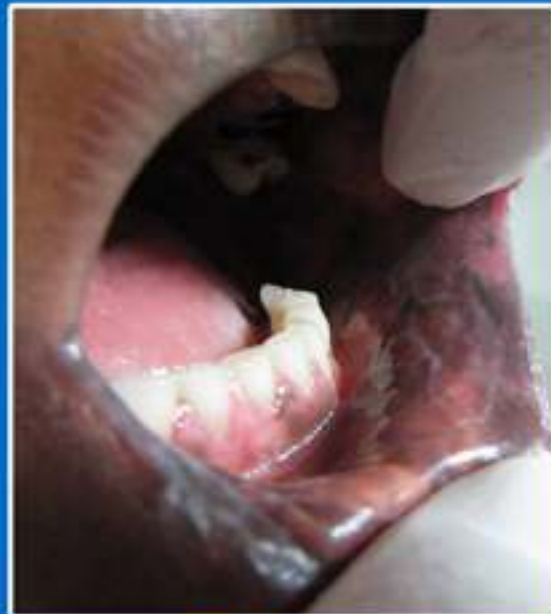

*Upper*

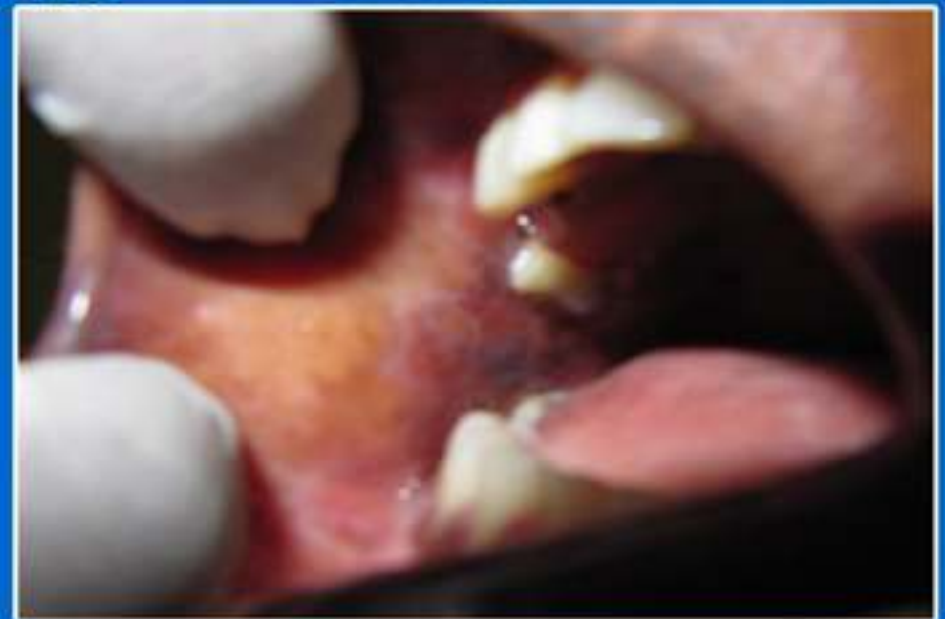

*Lower*

*Labial Mucosa*



*Left*



*Right*

*Buccal Mucosa*

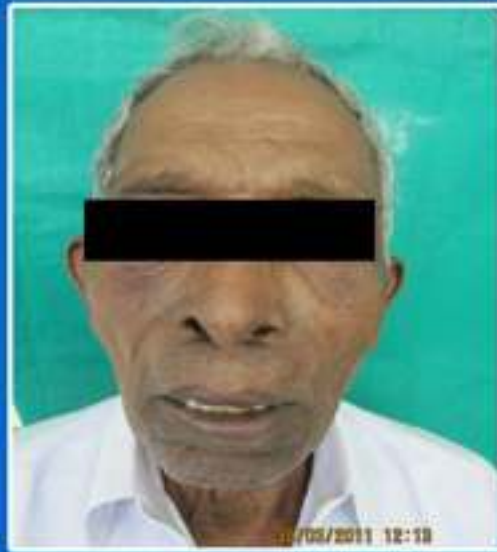*Patient Name: Mr.Ponnupillai*

*Age/sex: 76y/M*

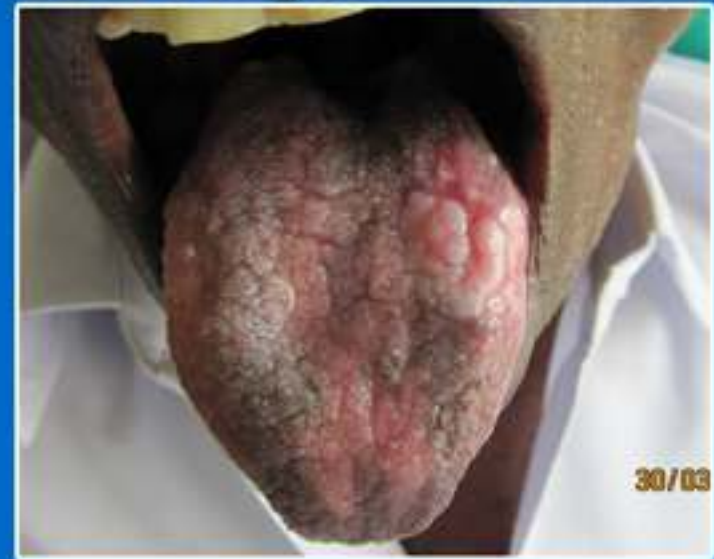*OP No: 201103300011*

*Diagnosis: Speckled Leukoplakia - Left  
Lateral Tongue & PVL - Dorsum Tongue*

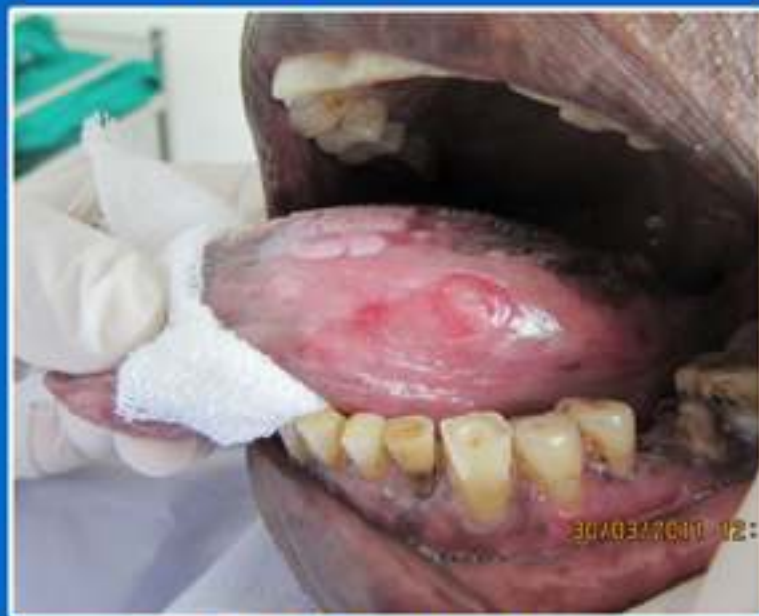# *Speckled Leukoplakia - Left Lateral Tongue & PVL - Dorsum Tongue*



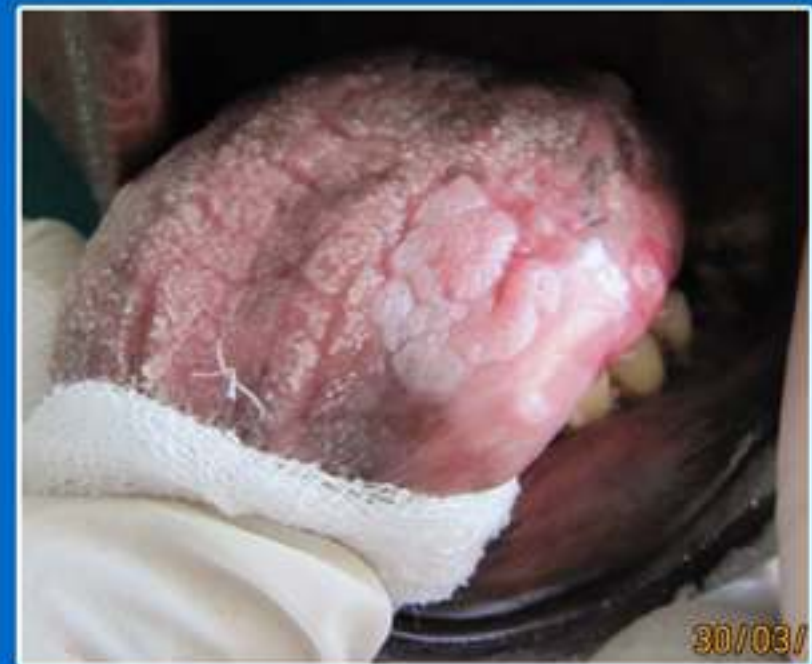*Profile*



*PVL - Dorsum Tongue*



*Speckled Leukoplakia  
- Left Lateral Tongue*



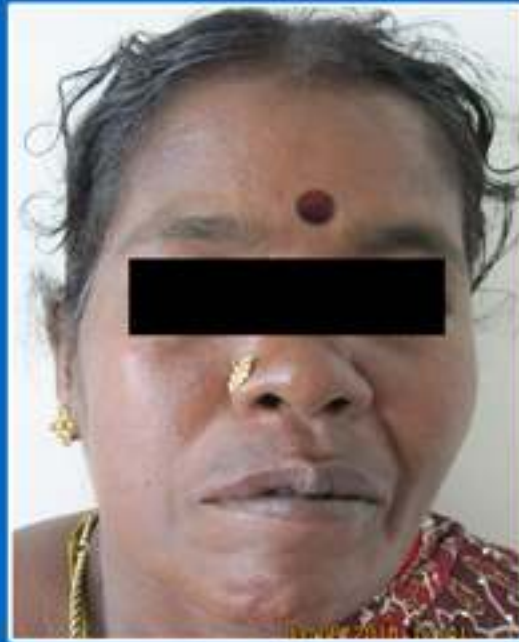*Patient Name: Mrs.Jeyalakshmi*

*Age/sex: 42y/F*

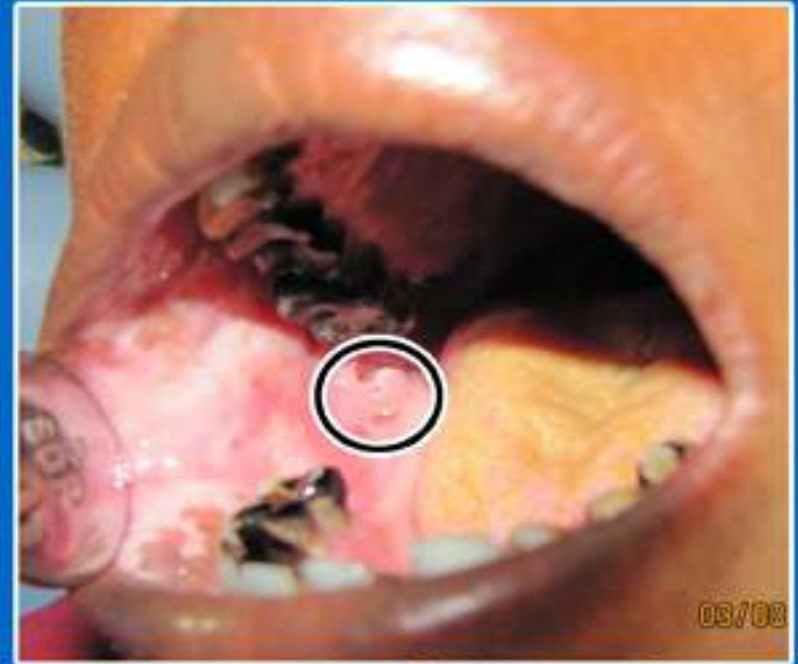*OP No: 201008030016*

*Diagnosis: OSMF with Traumatic Fibroma*

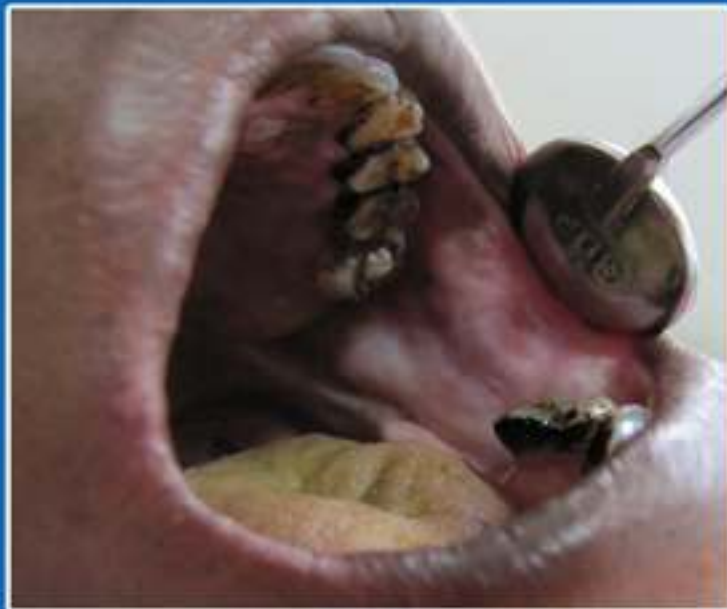# *OSMF with Traumatic Fibroma*



*Profile*

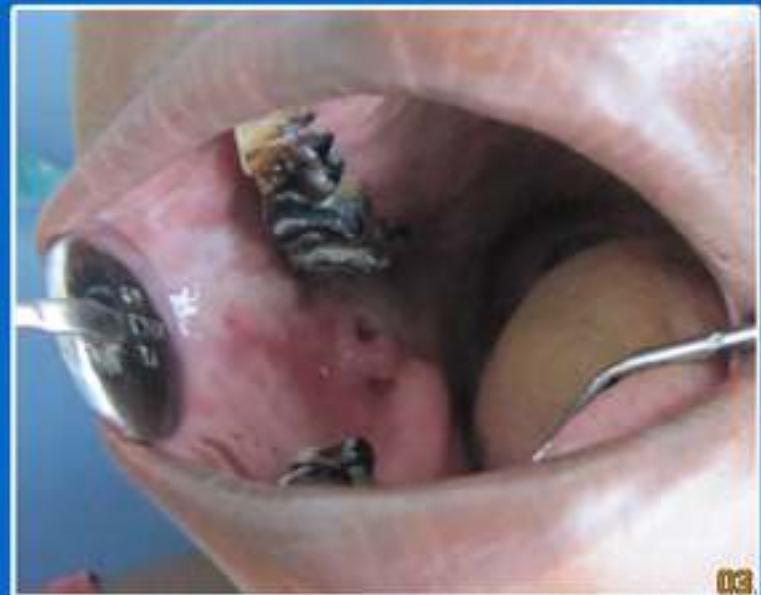

*Intra Oral Growth*



*Left*

*Buccal Mucosa*



*Right*

*Patient Name: Mr.Thopan Majumdar*

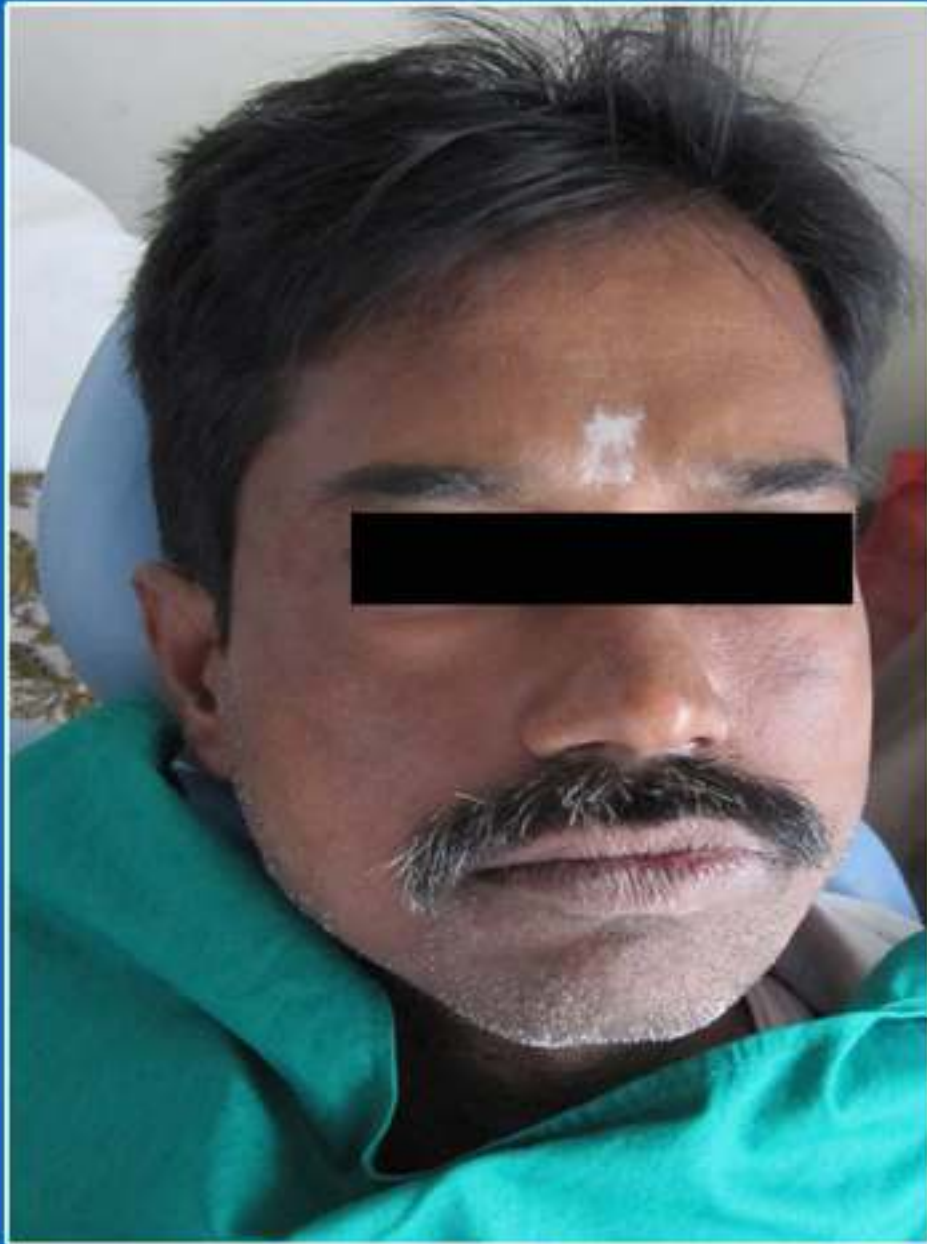*Age/sex: 39y/M*

*OP No: 201004300019*

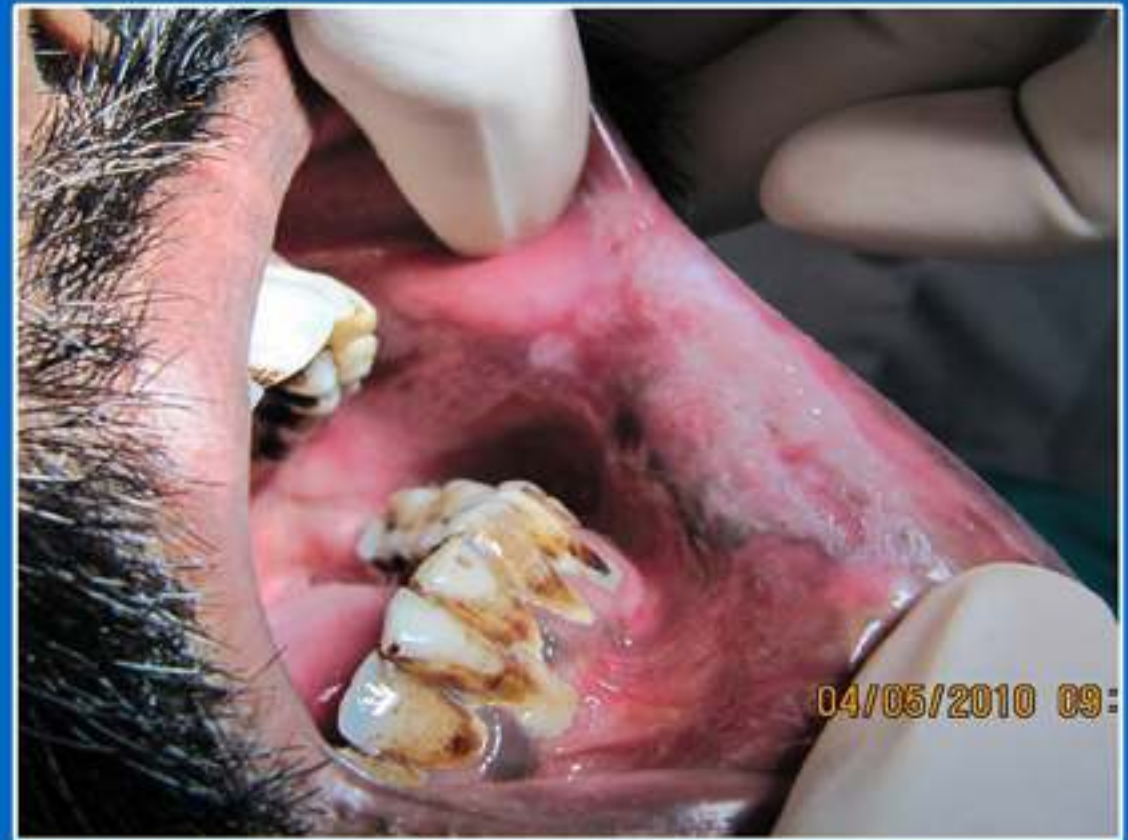*Diagnosis: Speckled Leukoplakia*



# *Speckled Leukoplakia*



*Extra Oral*



*Intra Oral*

*Patient Name: Mr.Karthikeyan*

*Age/sex: 19y/M*

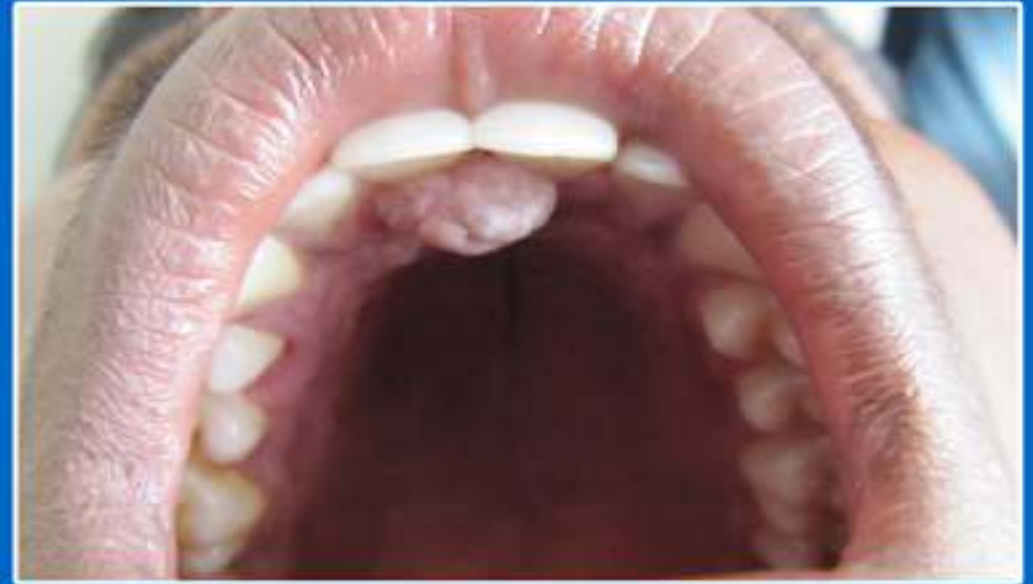*OP No: 201004210034*

*Diagnosis: Fibroma of Palate*

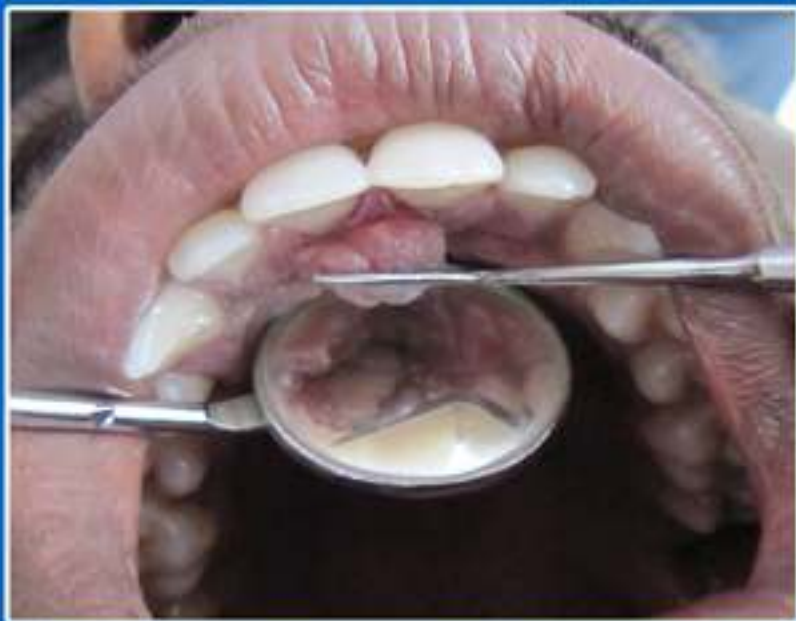# *Fibroma of Palate*



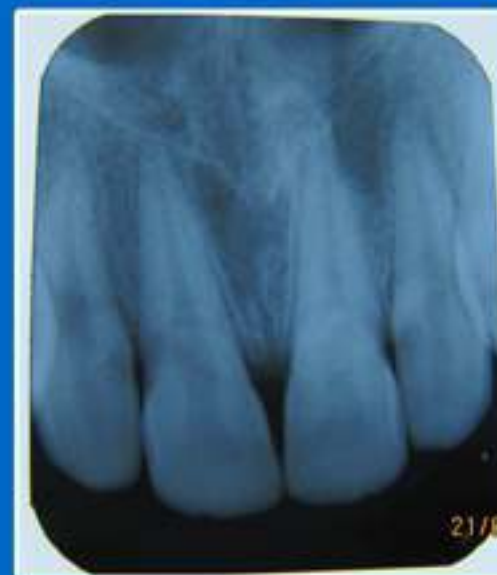
*Profile*



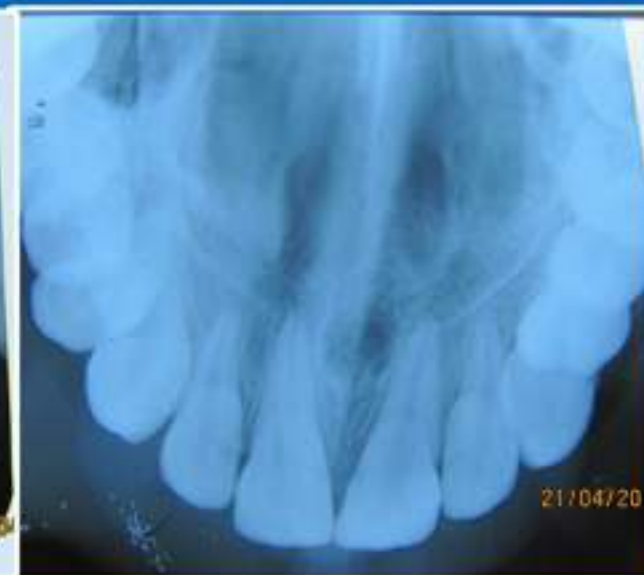
*Intra Oral*



*Palatal Growth*



*IOPA*



*Maxillary Occlusal*

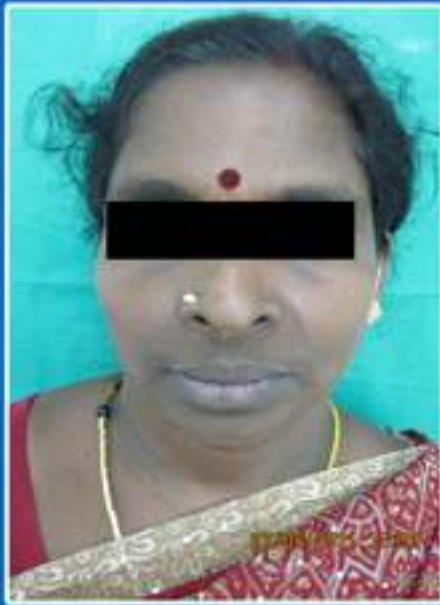*Patient Name: Mrs.Manimegalai*

*Age/sex: 46y/F*

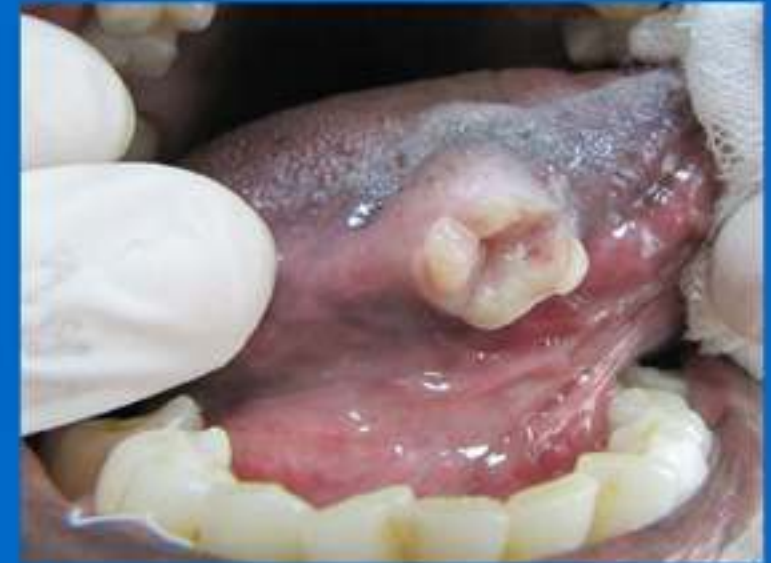*OP No: 201105260020*

*Diagnosis: Irritational Fibroma of Tongue*

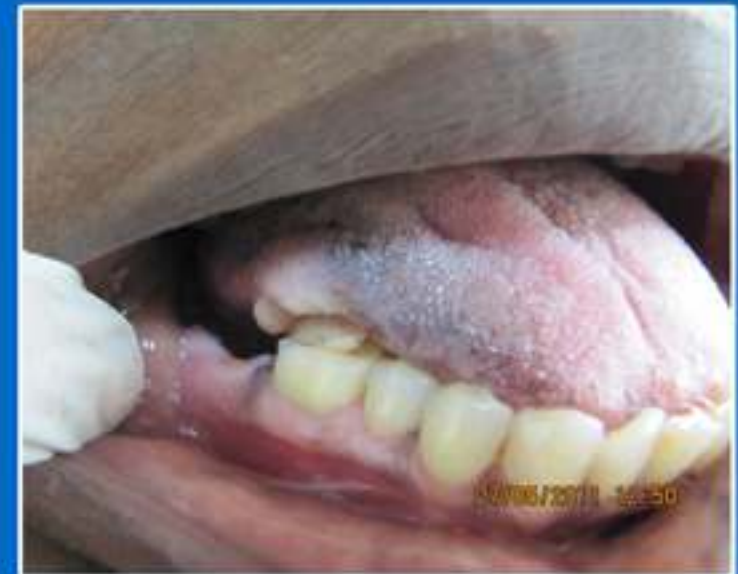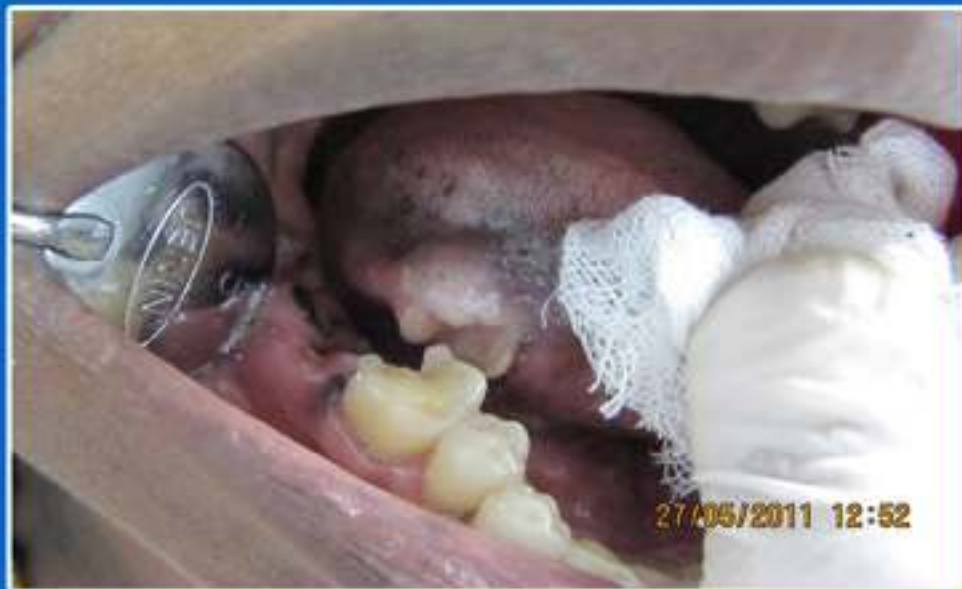# *Irritational Fibroma of Tongue*



*Profile*



*Intra Oral Growth*



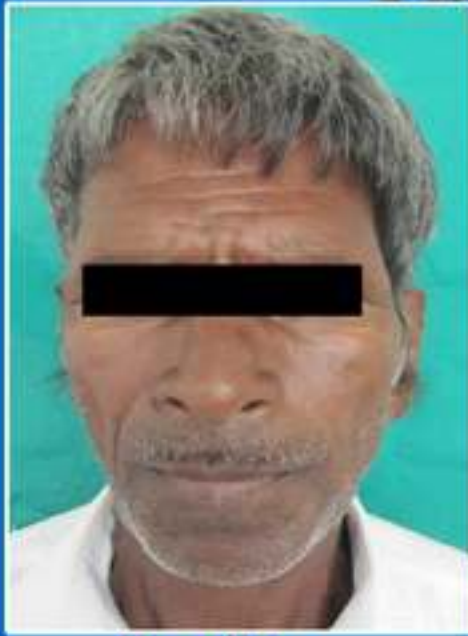*Patient Name: Mr.Govindhan*

*Age/sex: 60y/M*

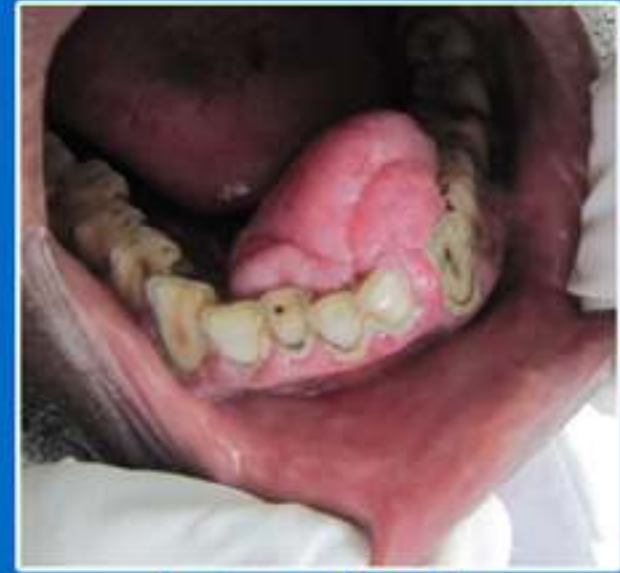*OP No: 201106280024*

*Diagnosis: Fibrosed Pyogenic Granuloma*

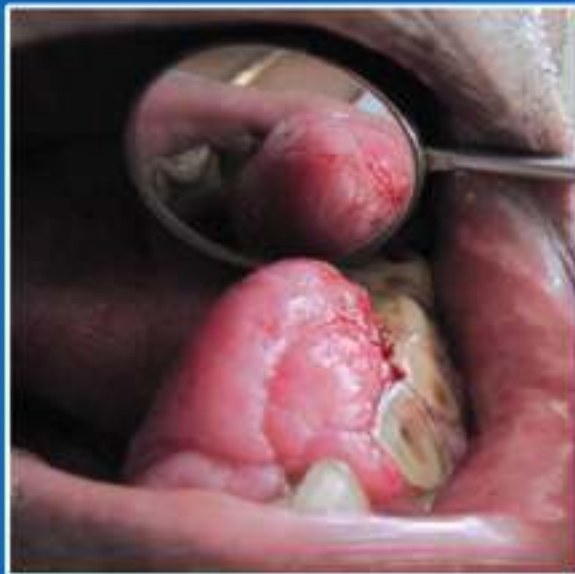# *Fibrosed Pyogenic Granuloma*



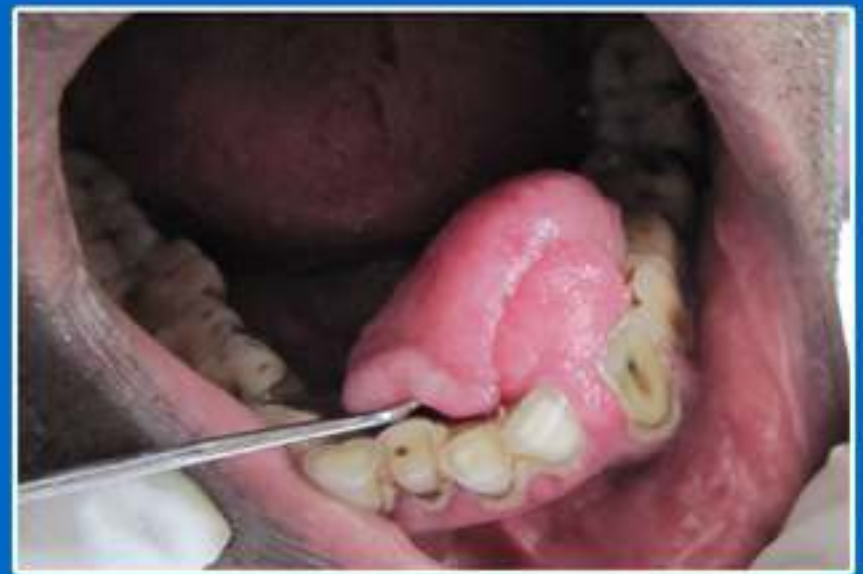*Profile*



*Intra Oral*



*Intra Oral Growth*



*Peduncalated*

*Patient Name: Mrs.Usha*

*Age/sex: 33y/F*

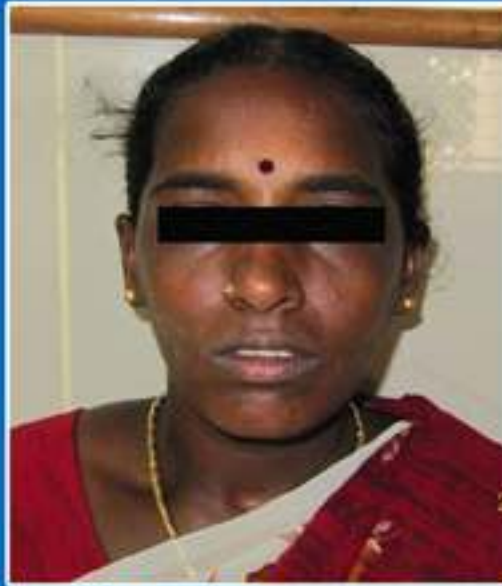*OP No: 201004200014*

*Diagnosis: Enamel Hypoplasia  
- Amelogenesis Imperfecta*

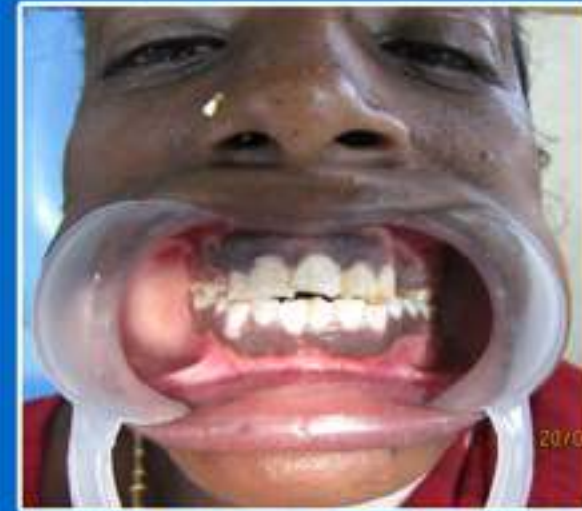

# *Enamel Hypoplasia*

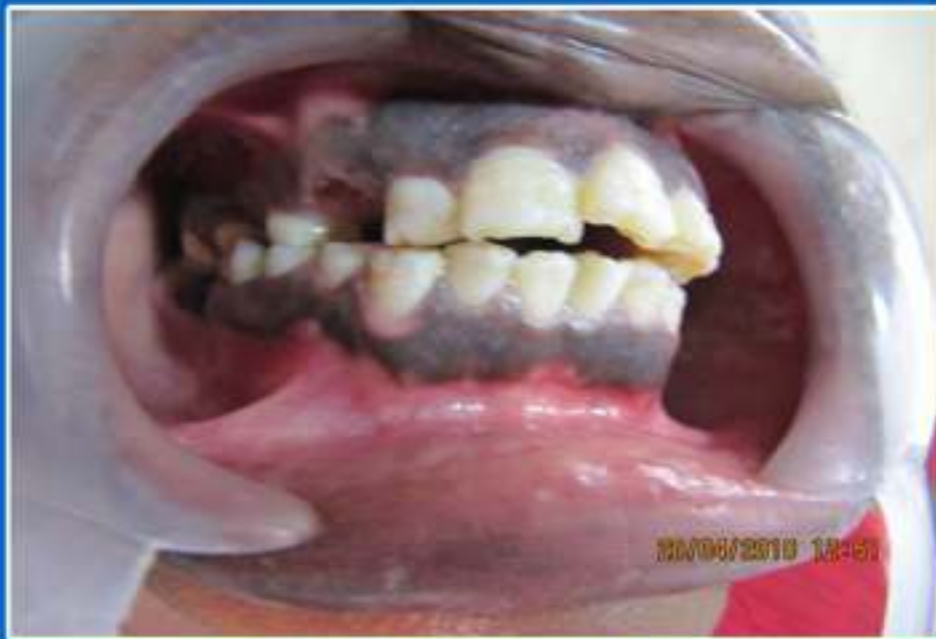*- Amelogenesis Imperfecta*



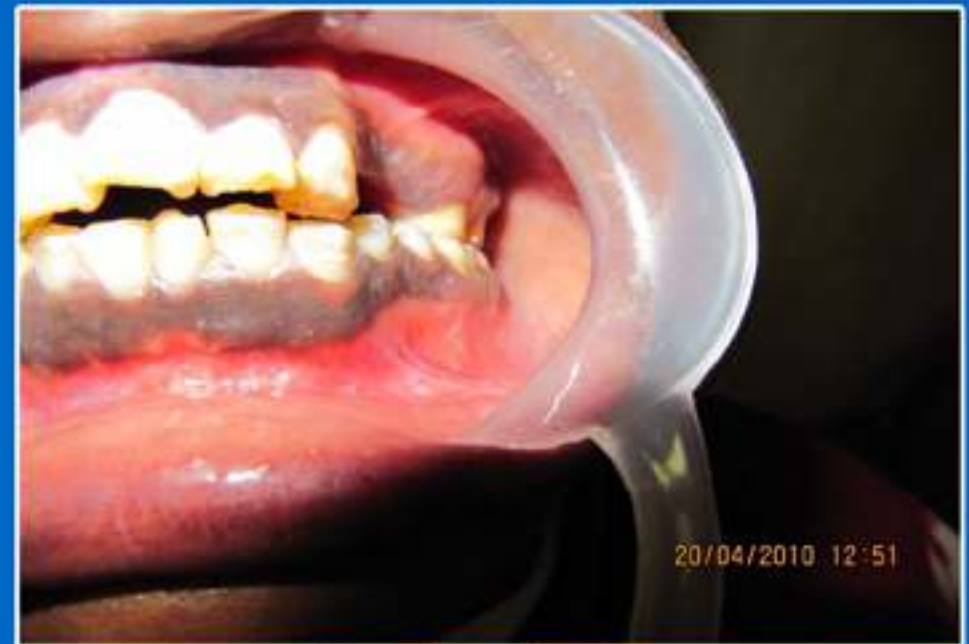*Profile*



*Extra Oral*



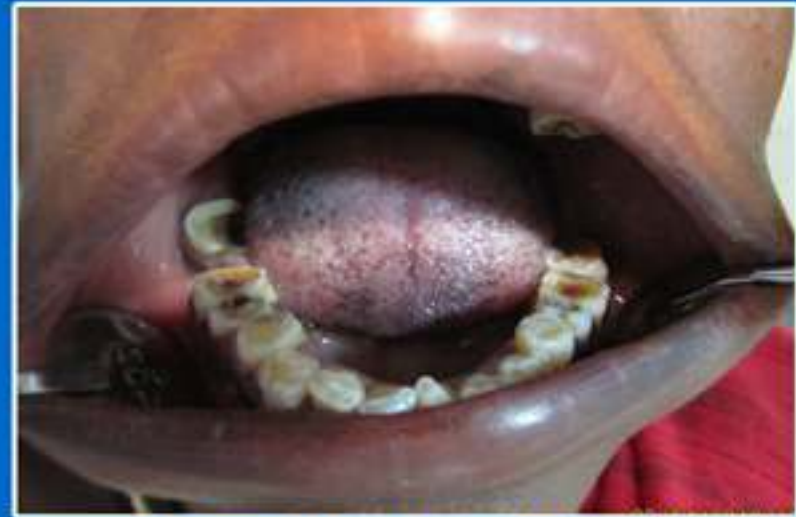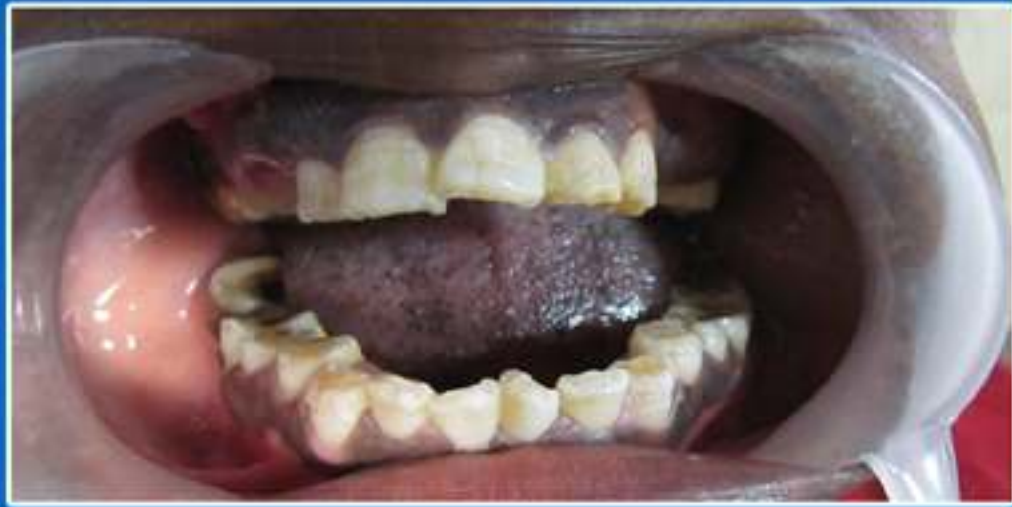*Intra Oral-Right Side*



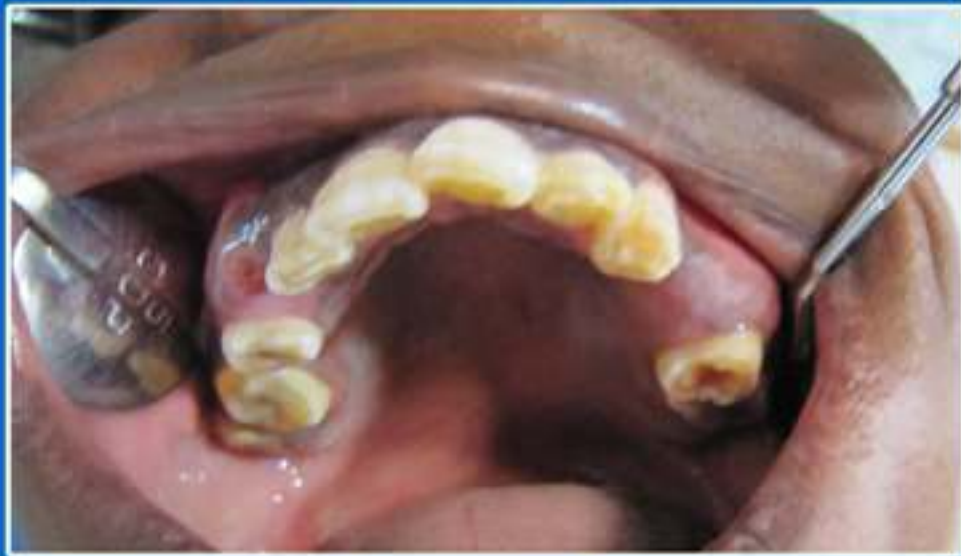*Intra Oral-Left Side*

# *Enamel Hypoplasia*

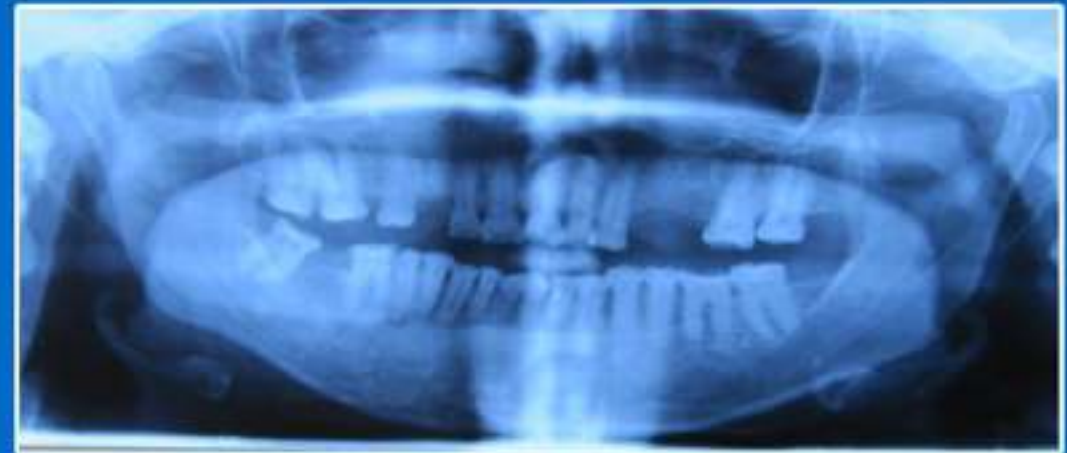
*- Amelogenesis Imperfecta*



*Mandibular Teeth*



*Maxillary Teeth*



*Orthopantomogram*

*Patient Name: Mr.Raja*

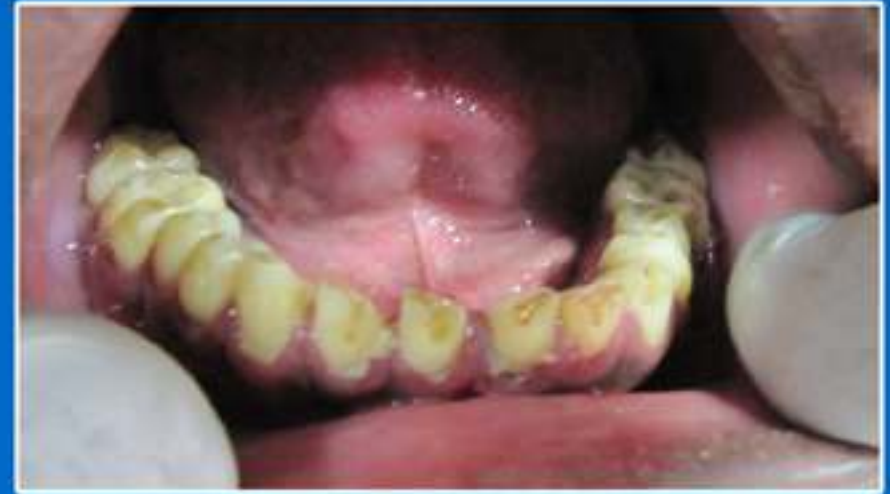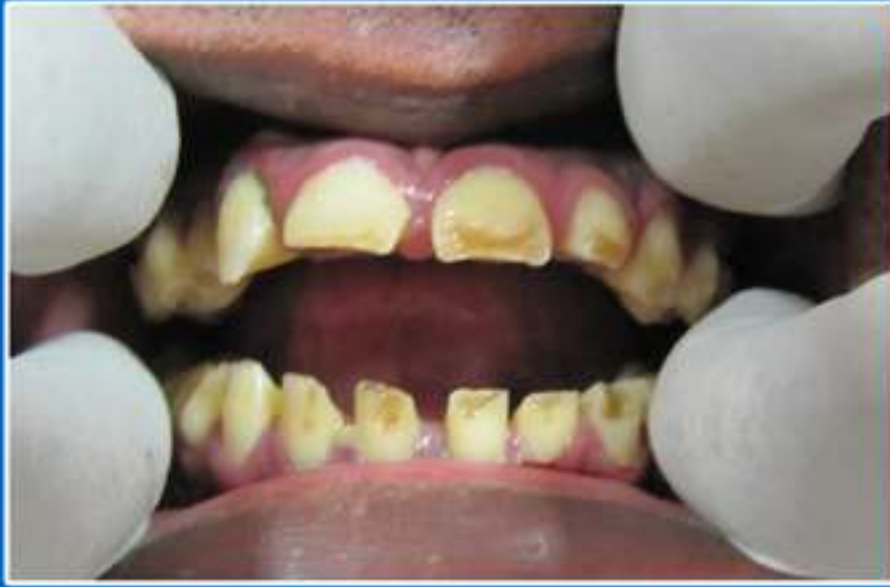*Age/sex: 30y/M*

*OP No: 201003310025*

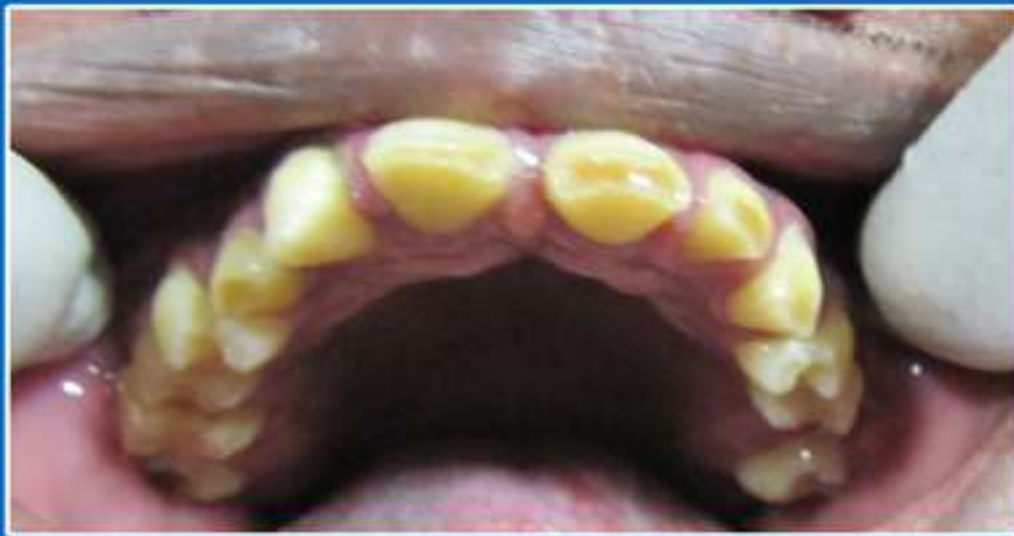*Diagnosis: Enamel Hypoplasia  
- Amelogenesis Imperfecta*

# *Enamel Hypoplasia*

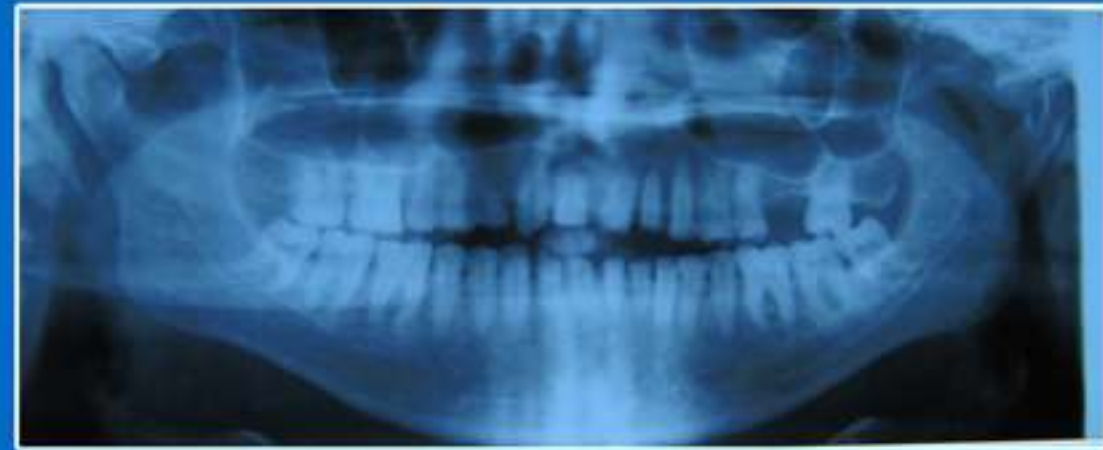*- Amelogenesis Imperfecta*



*Mandibular Teeth*



*Maxillary Teeth*



*Orthopantomogram*