



Chettinad
Dental College & Research Institute



Department of ORAL SURGERY

CASE ALBUM

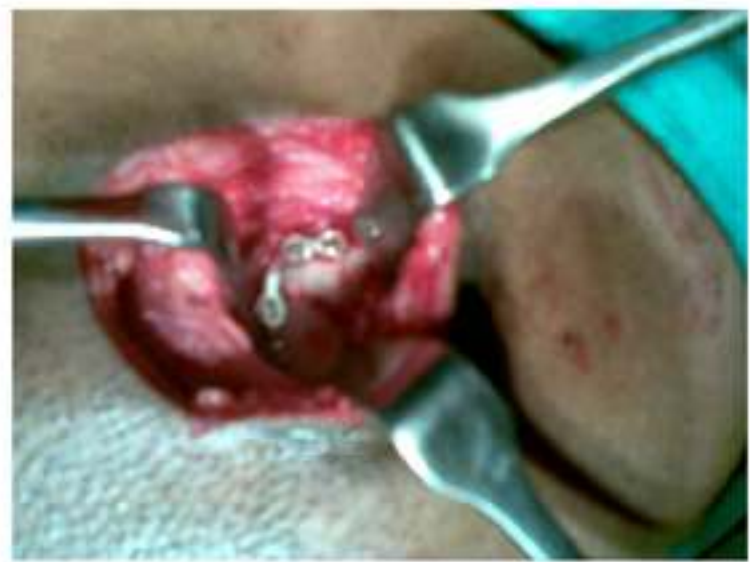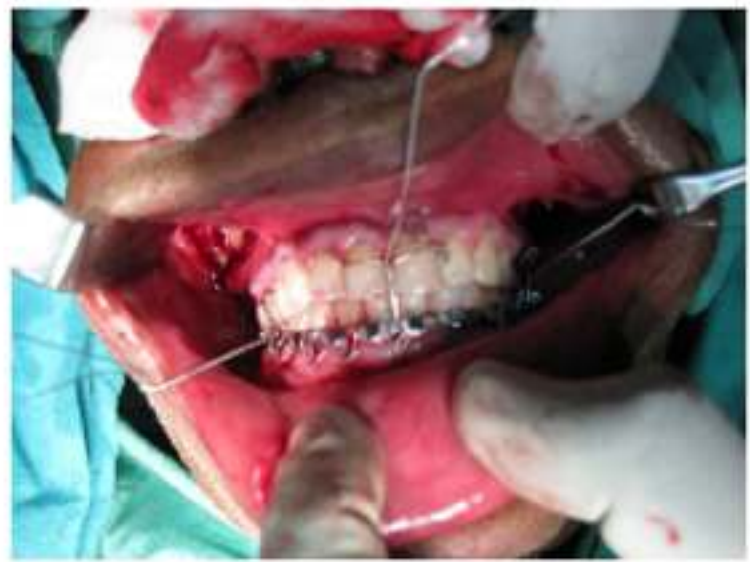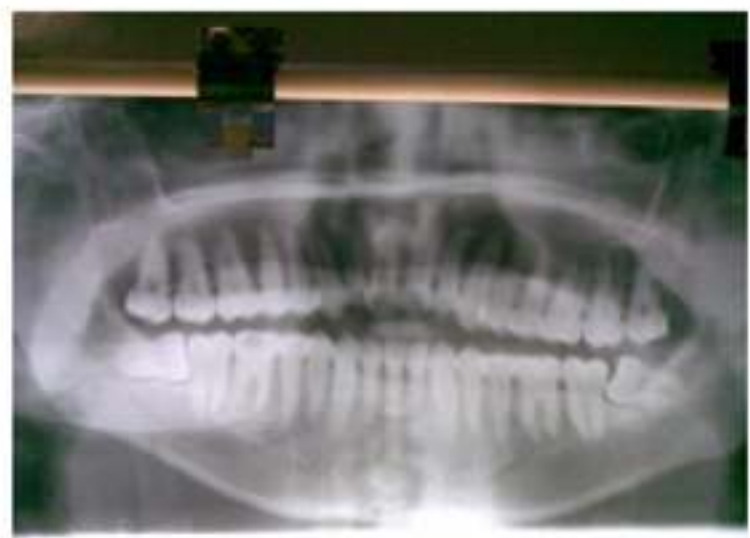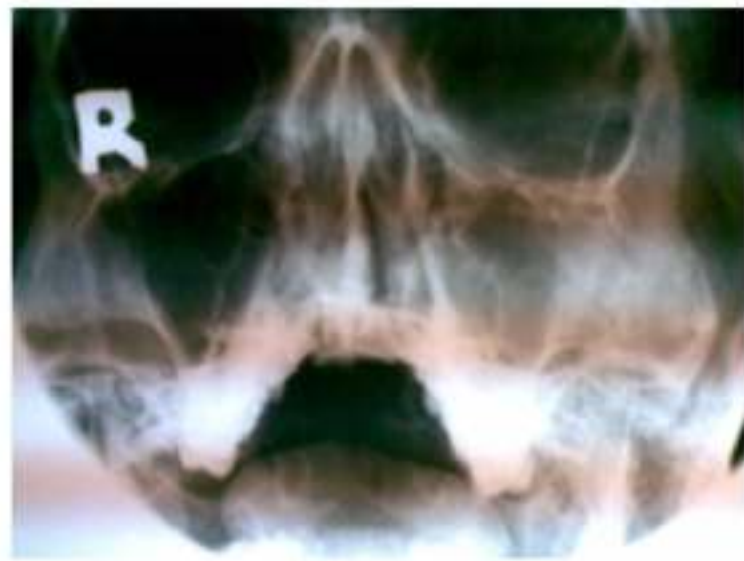**DEPARTMENT OF ORAL &
MAXILLOFACIAL SURGERY**

SURGICALCASE ALBUM

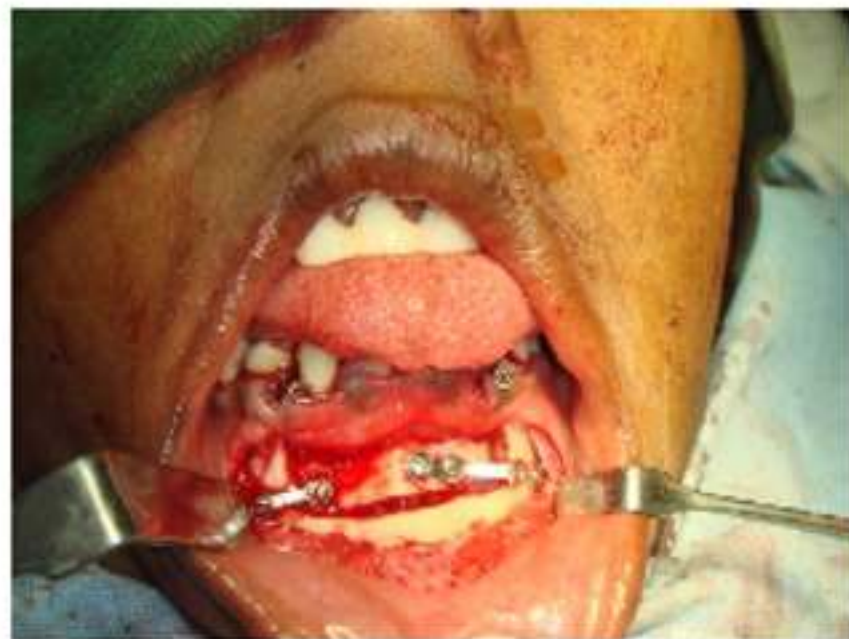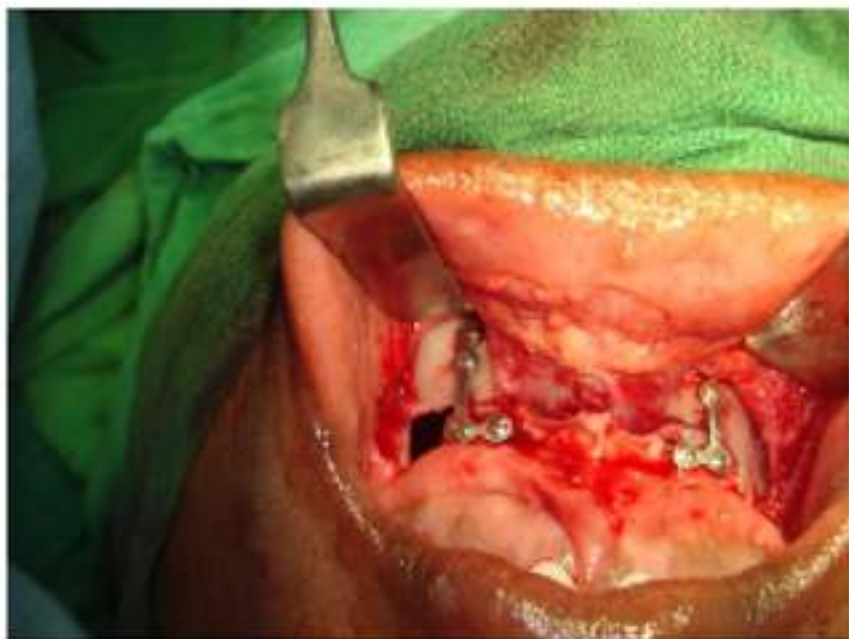Lefort II fracture maxilla & Right angle fracture of mandible

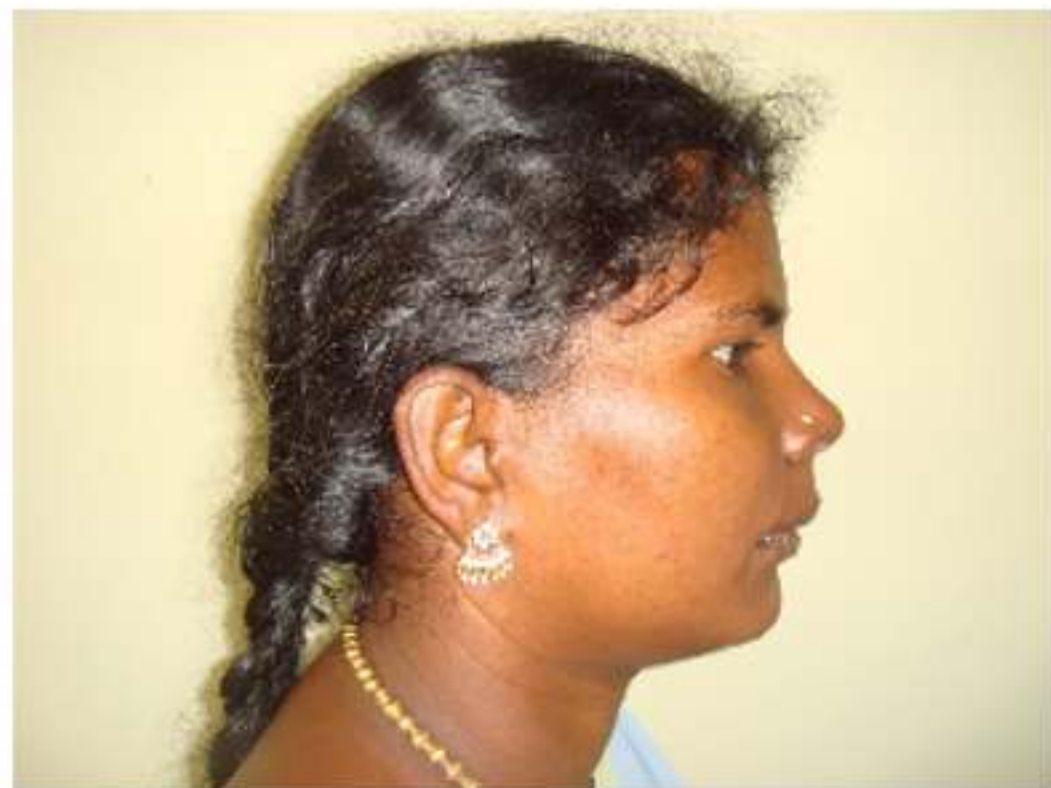- Patient name- Mr Mohan
- Age/ sex – 25/m
- Hosp no – 200808250045
- Date- 26/08/2008

Pre-op X-ray & Intra-op view



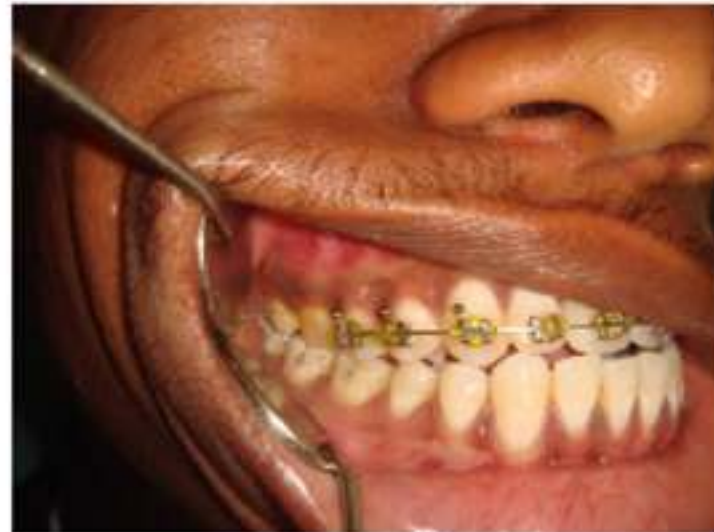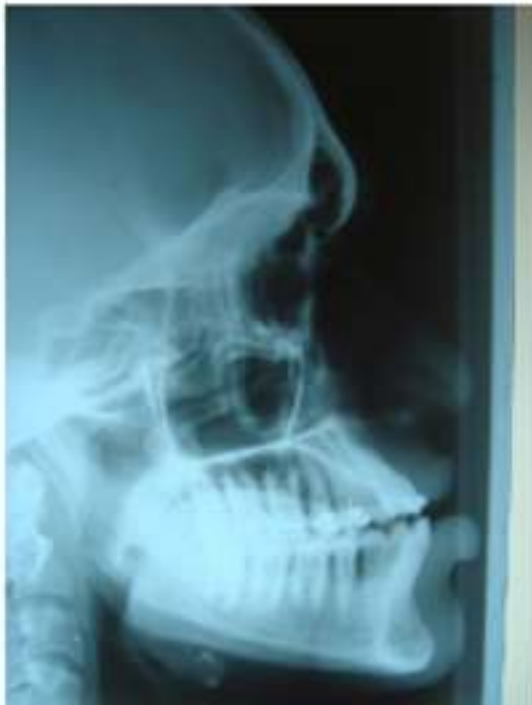- Anterior maxillary osteotomy & Mandibular subapical osteotomy
- Patient Name – Mrs Dharani
- Age / sex – 31/ F
- Hosp no- 0908100003
- Date – 19/08/2009



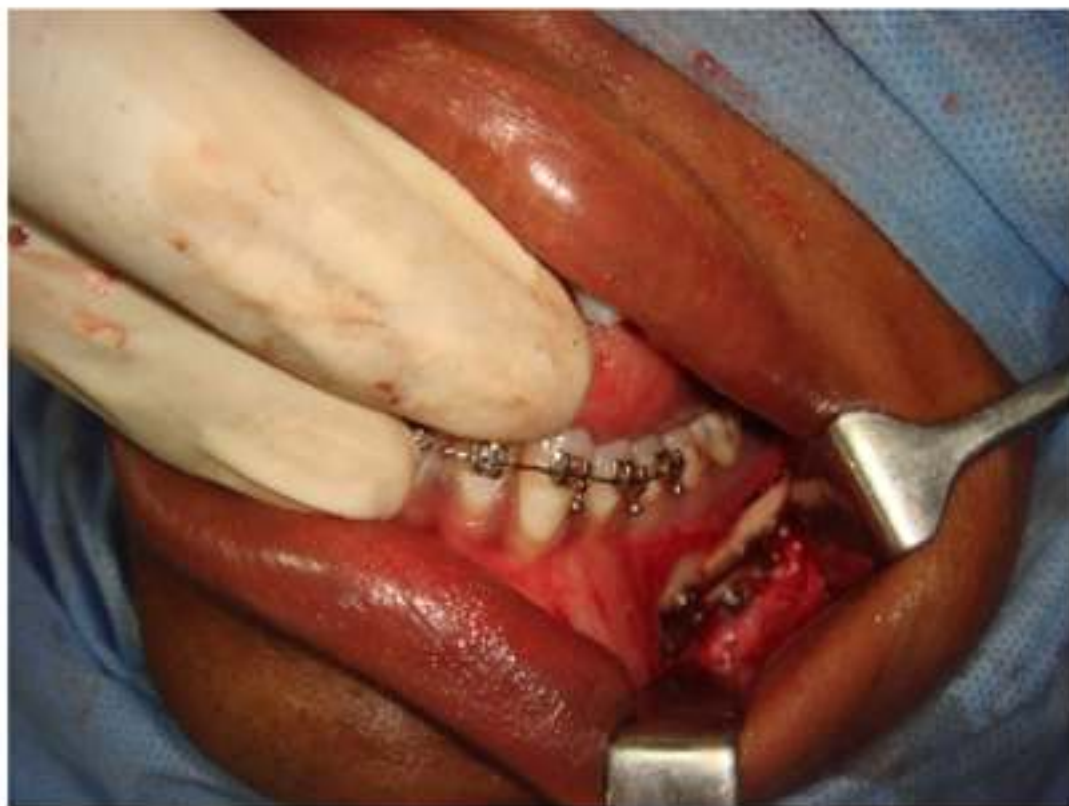
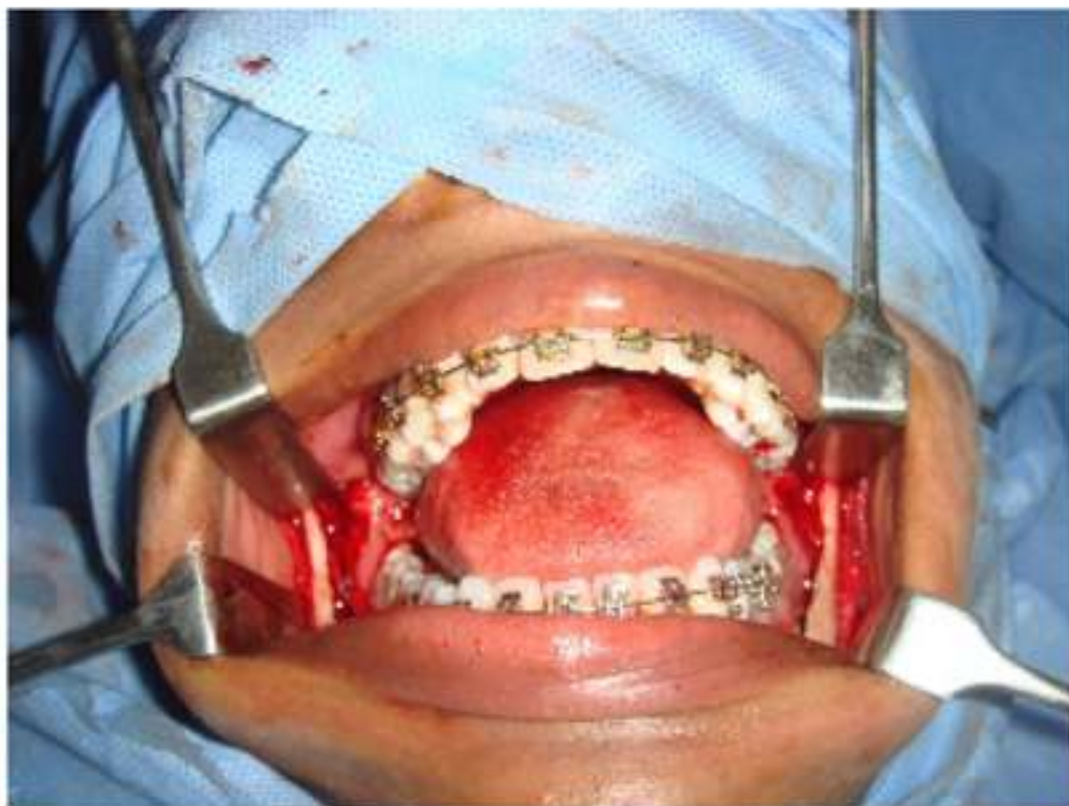
- Bilateral Sagittal split Osteotomy of Mandible
- Patient Name – Mr Ranjith
- Age / Sex – 22 / M
- Hosp no – 090007375
- Date – 2/6/2010

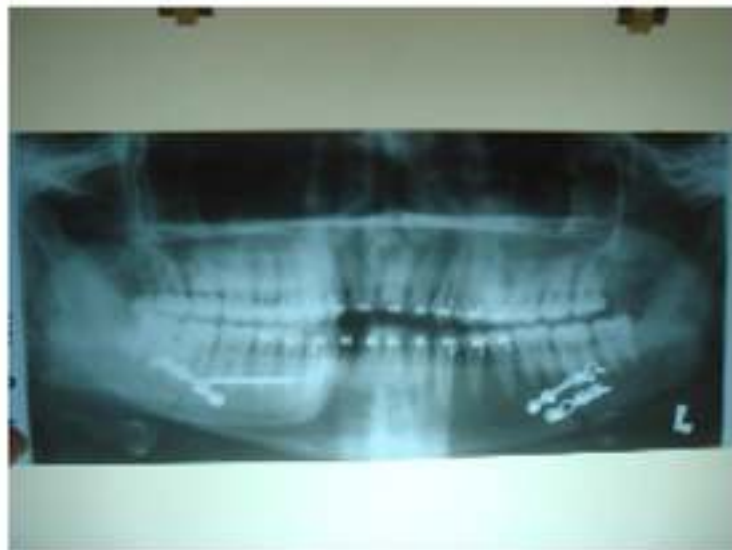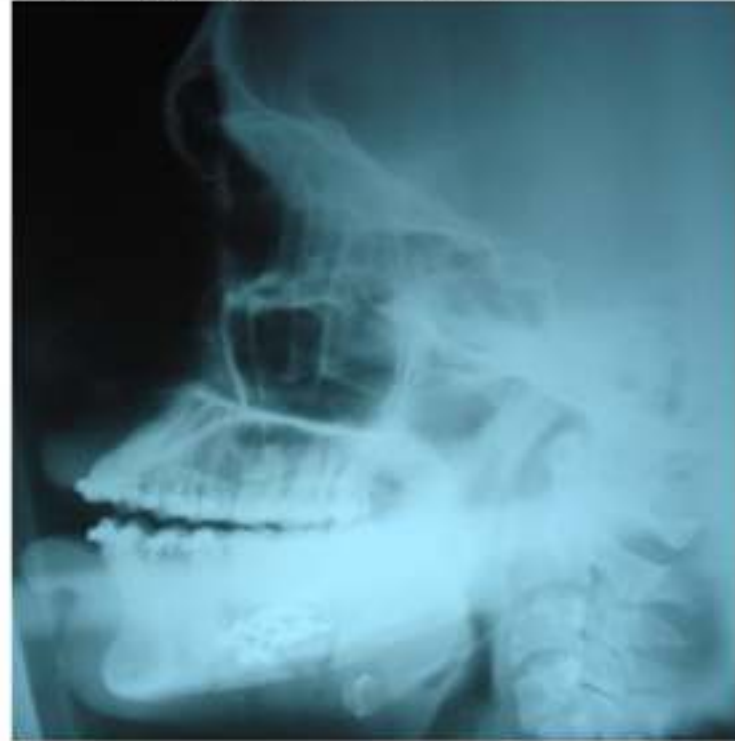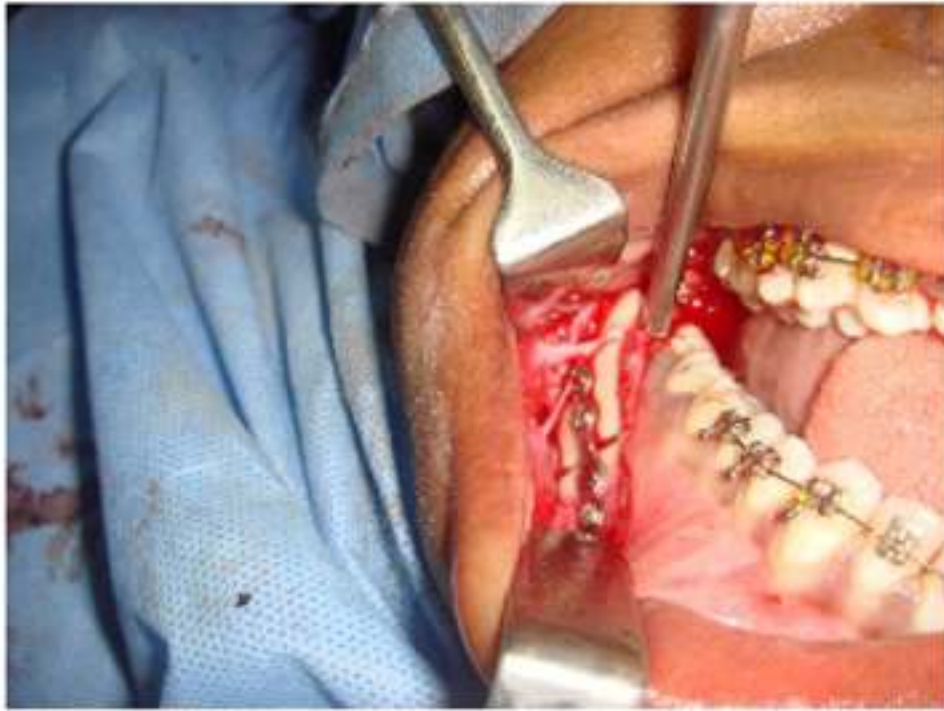PREOPERATIVE



INTRAOPERATIVE



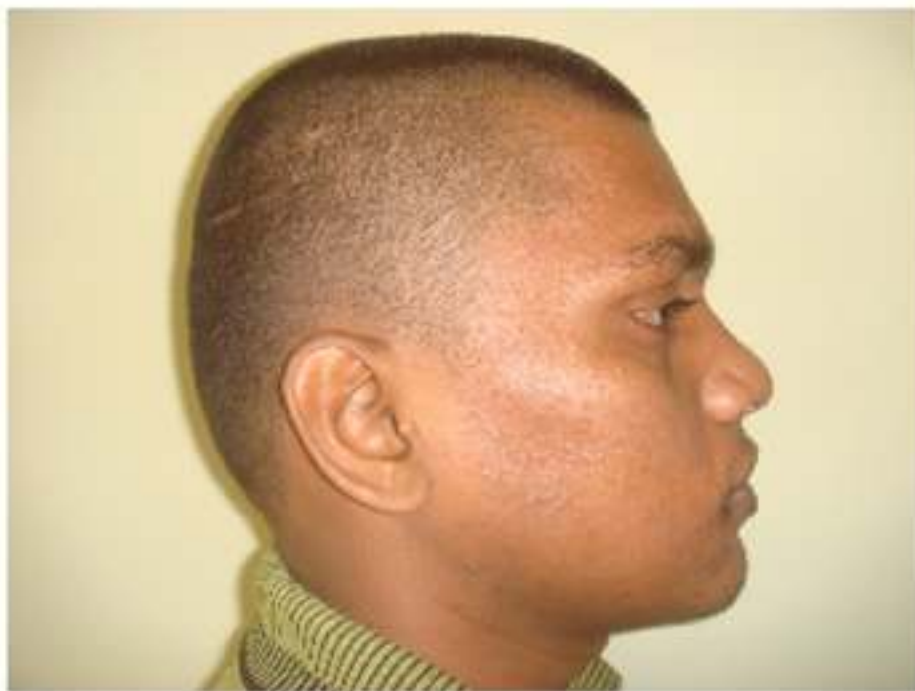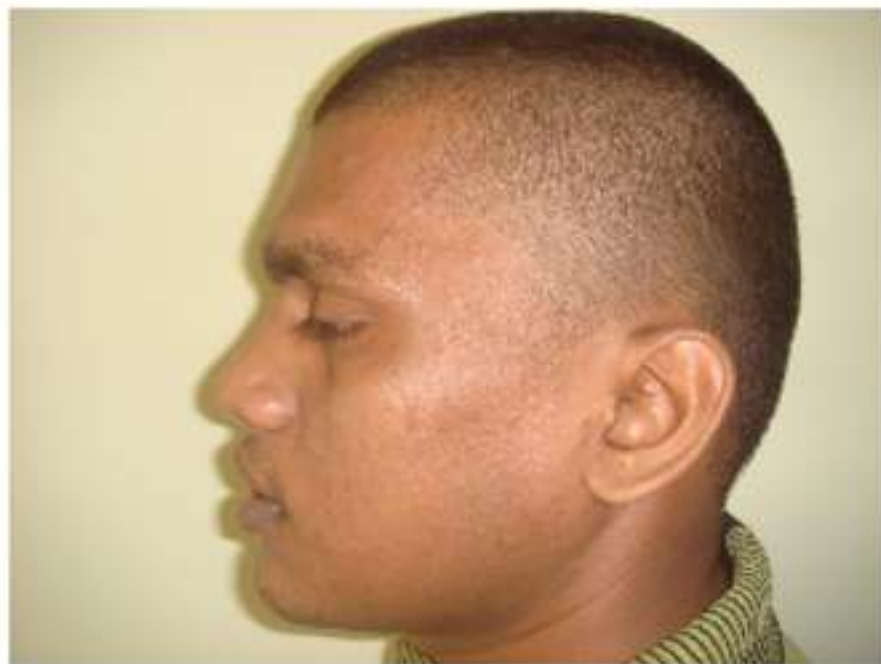INTRA OPERATIVE



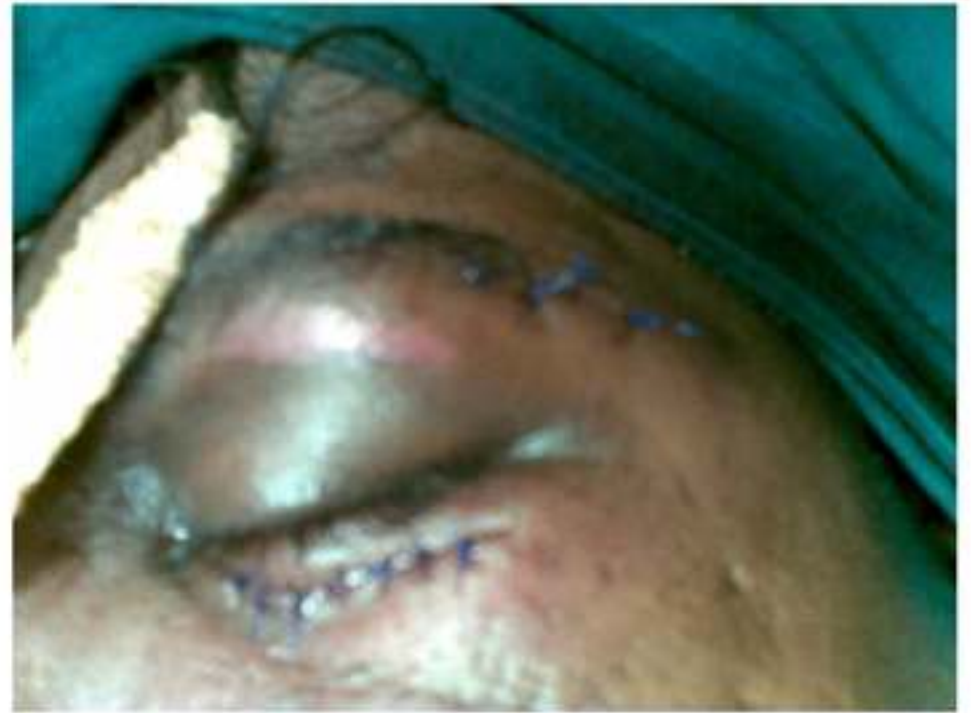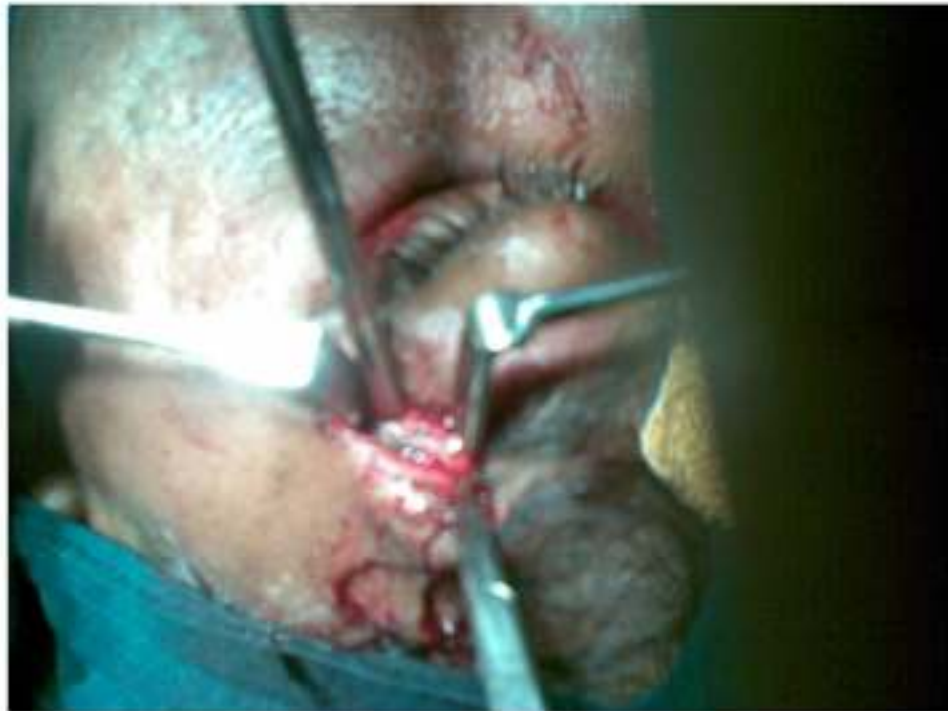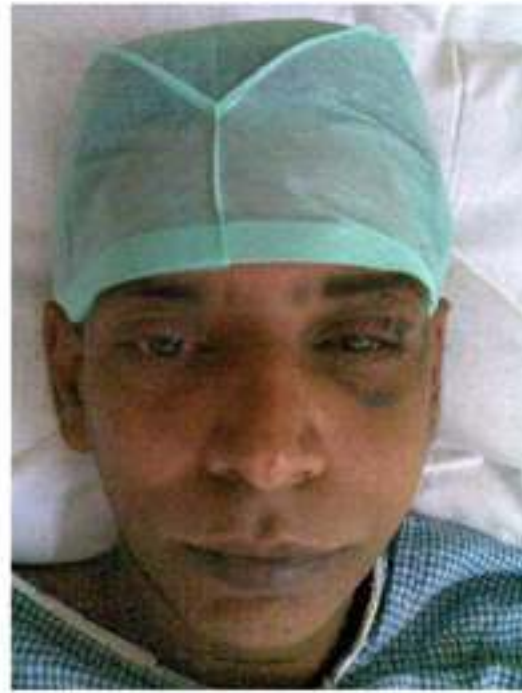IMMEDIATE POST OP



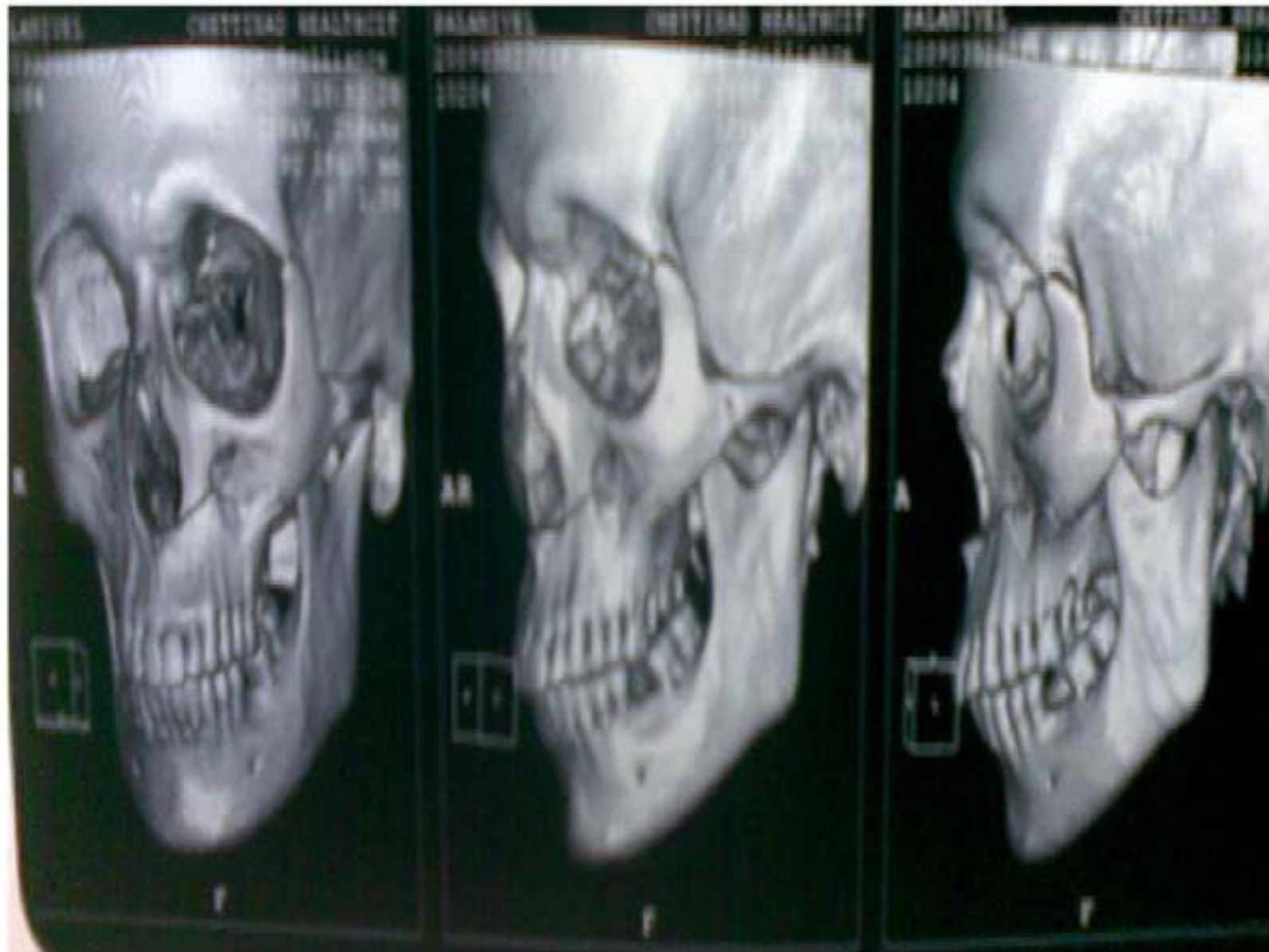
POSTOPERATIVE



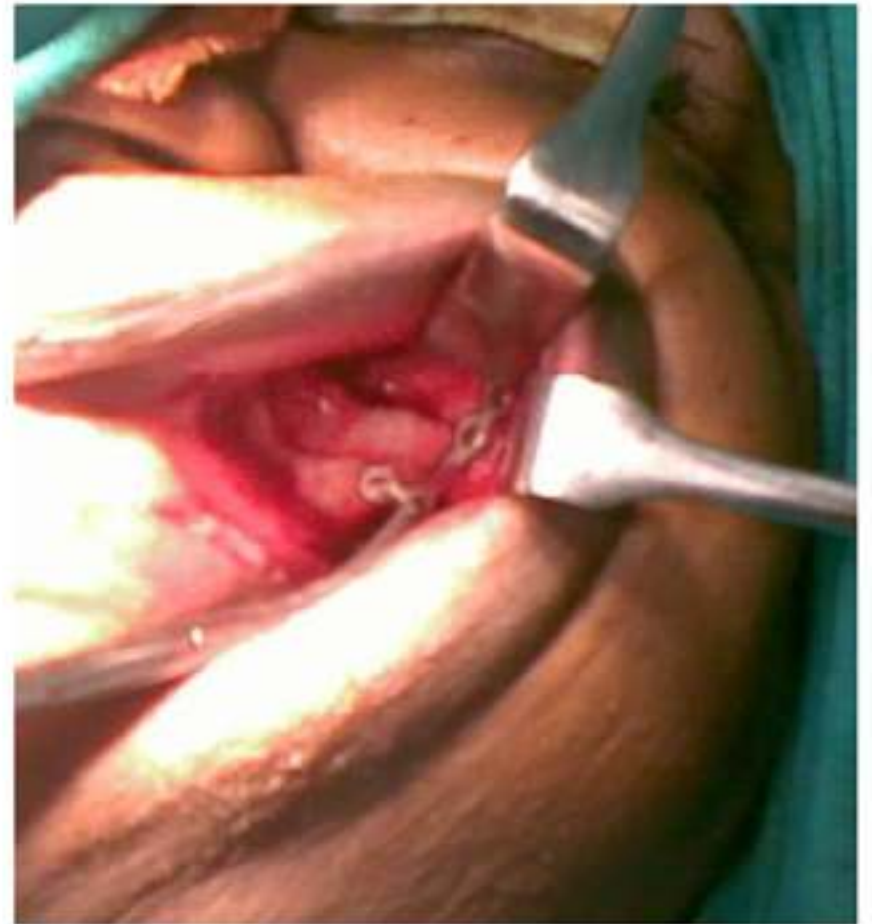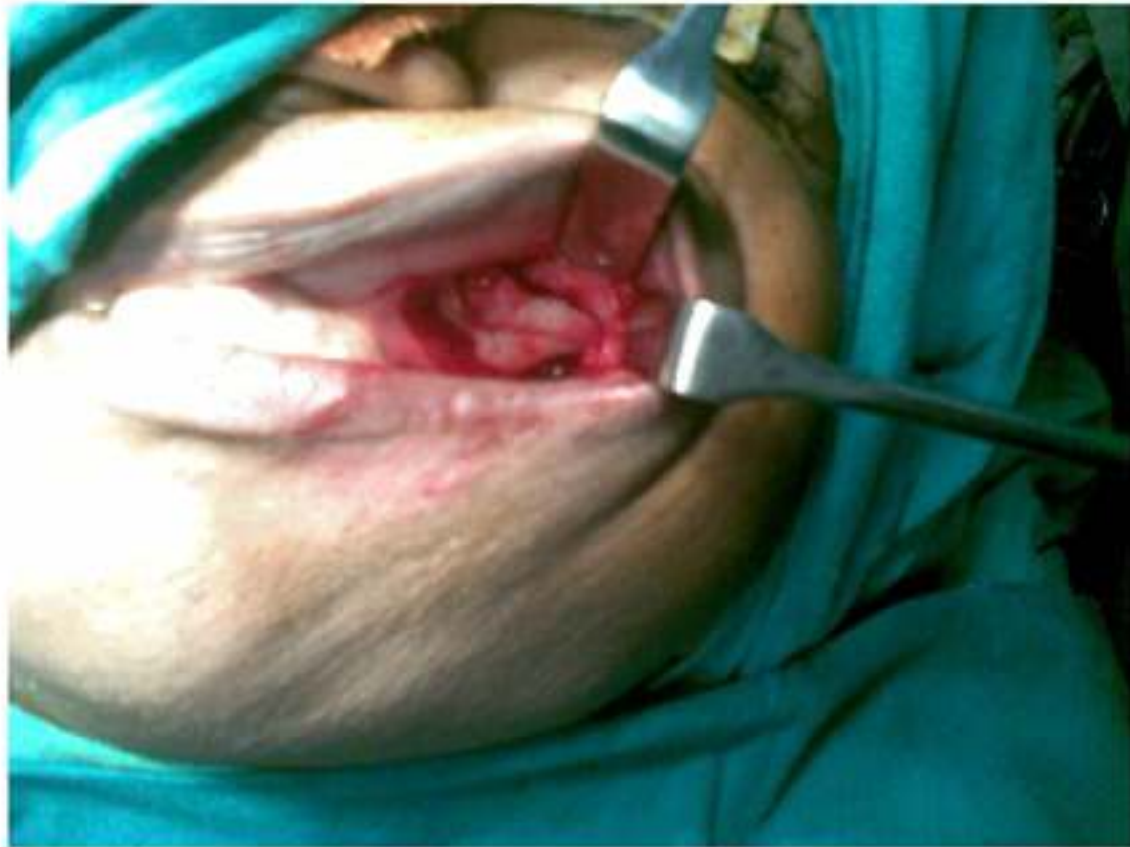- UNILATERAL LEFORT I Fracture
- Patient Name – Mr Palanivelu
- Age / Sex – 44/M
- Date- 7/3/2009



PREOPERATIVE X-RAY

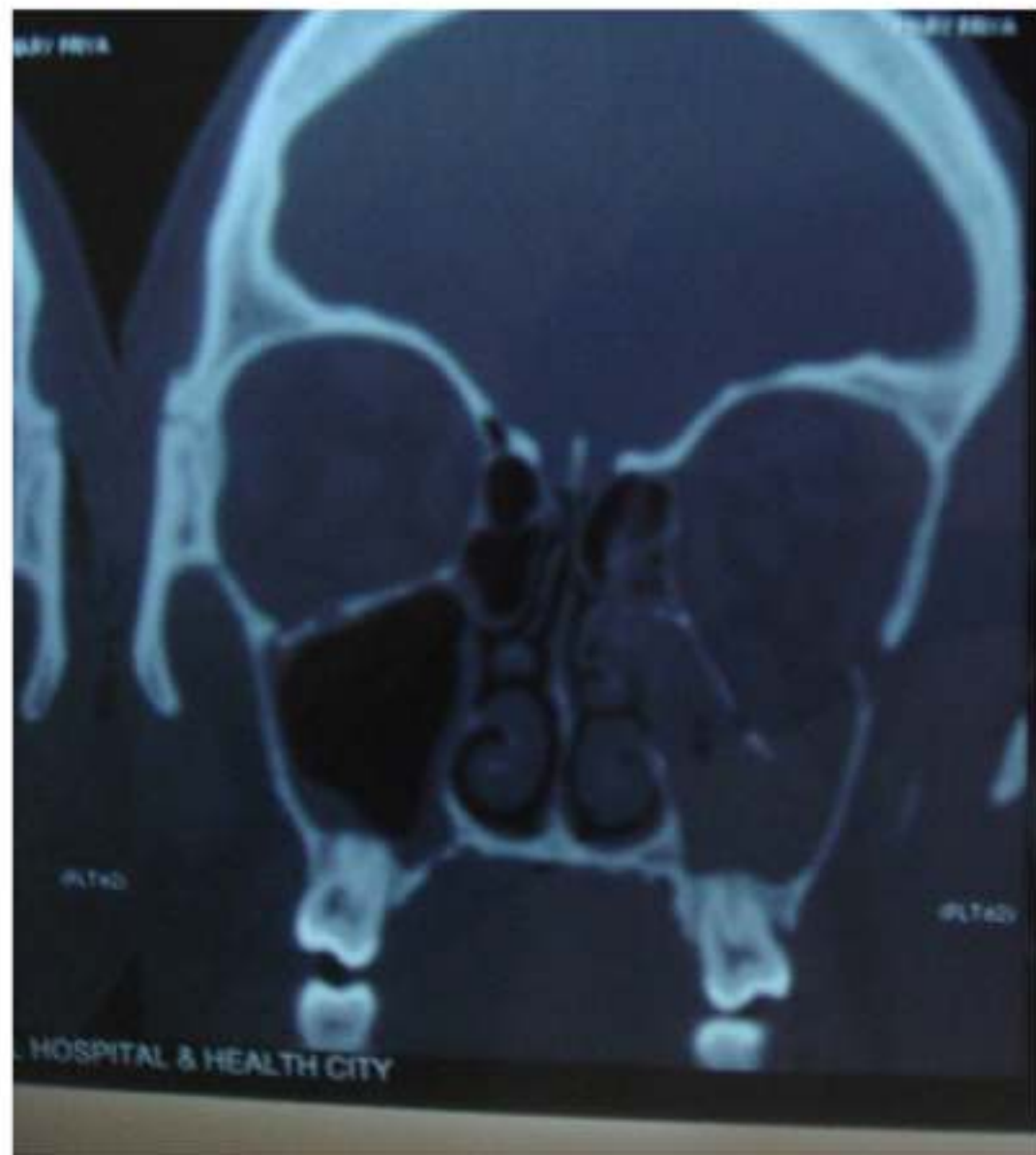
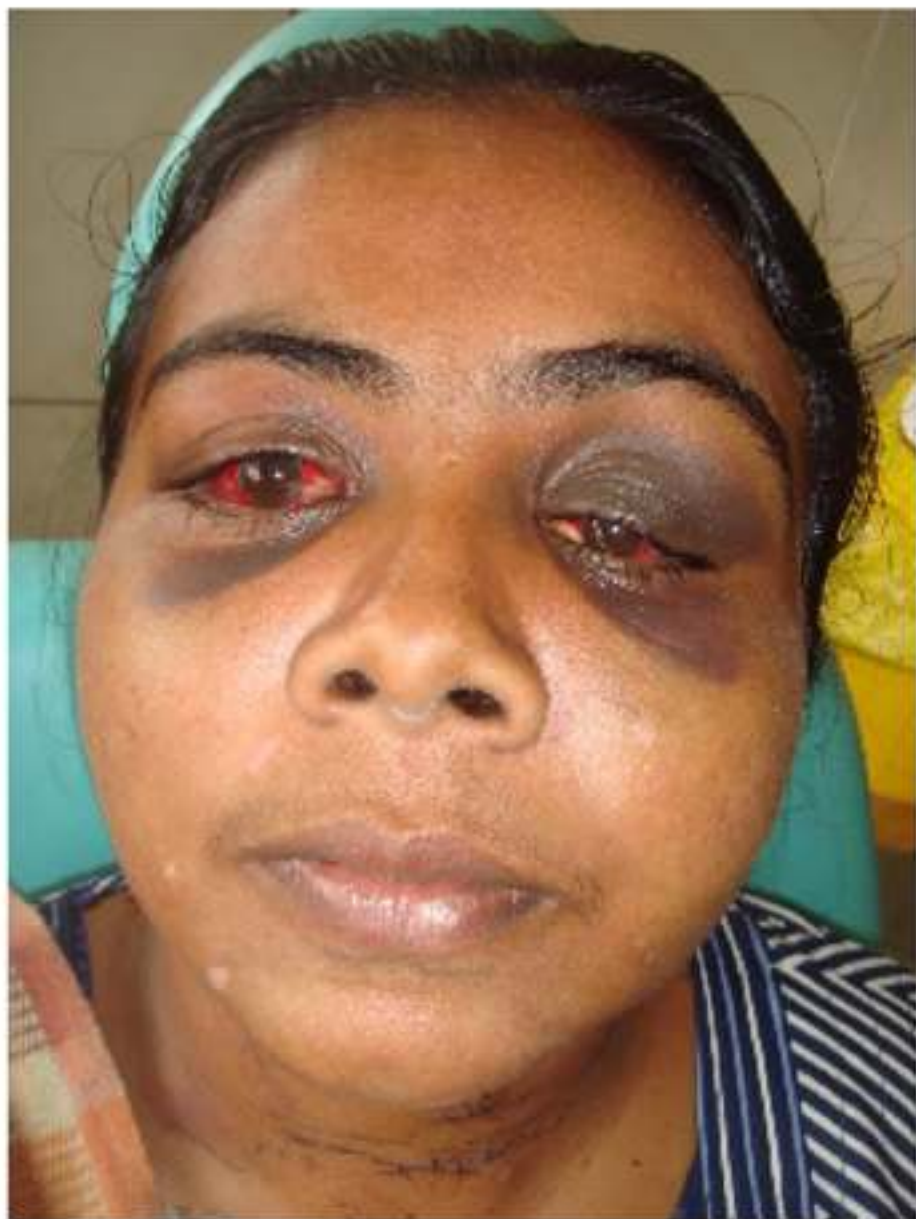
INTRAOOPERATIVE

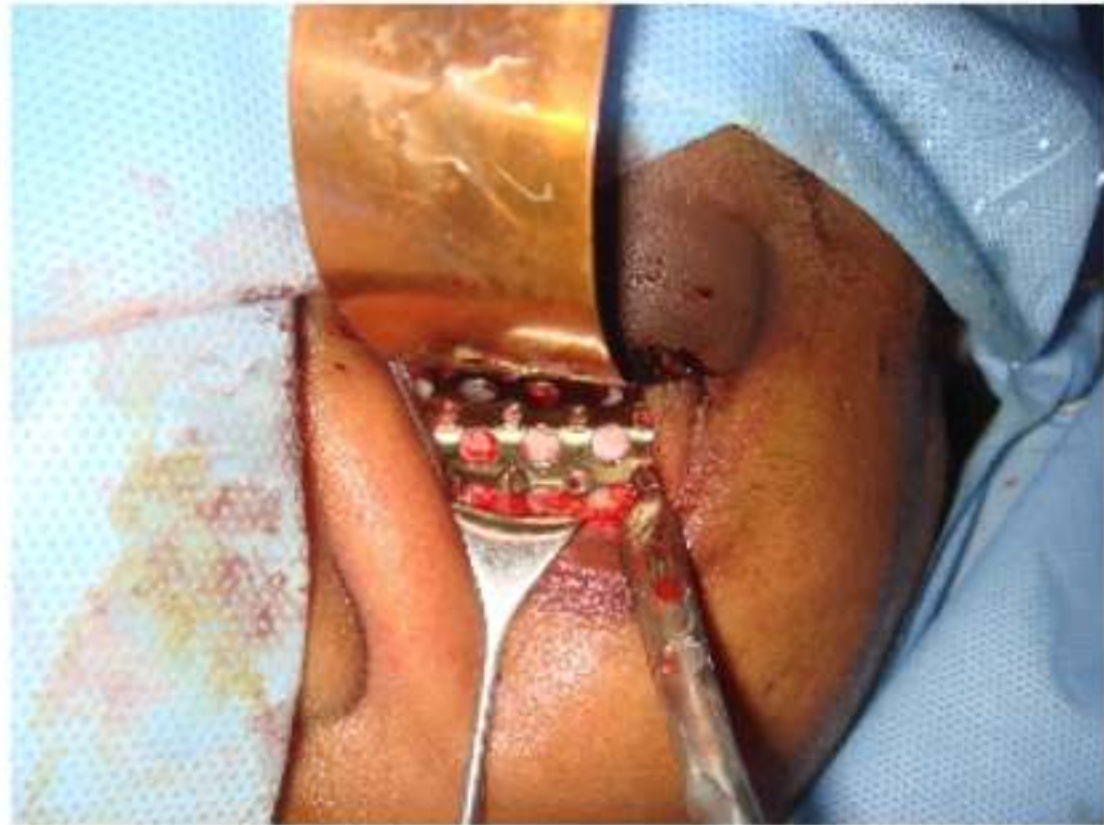
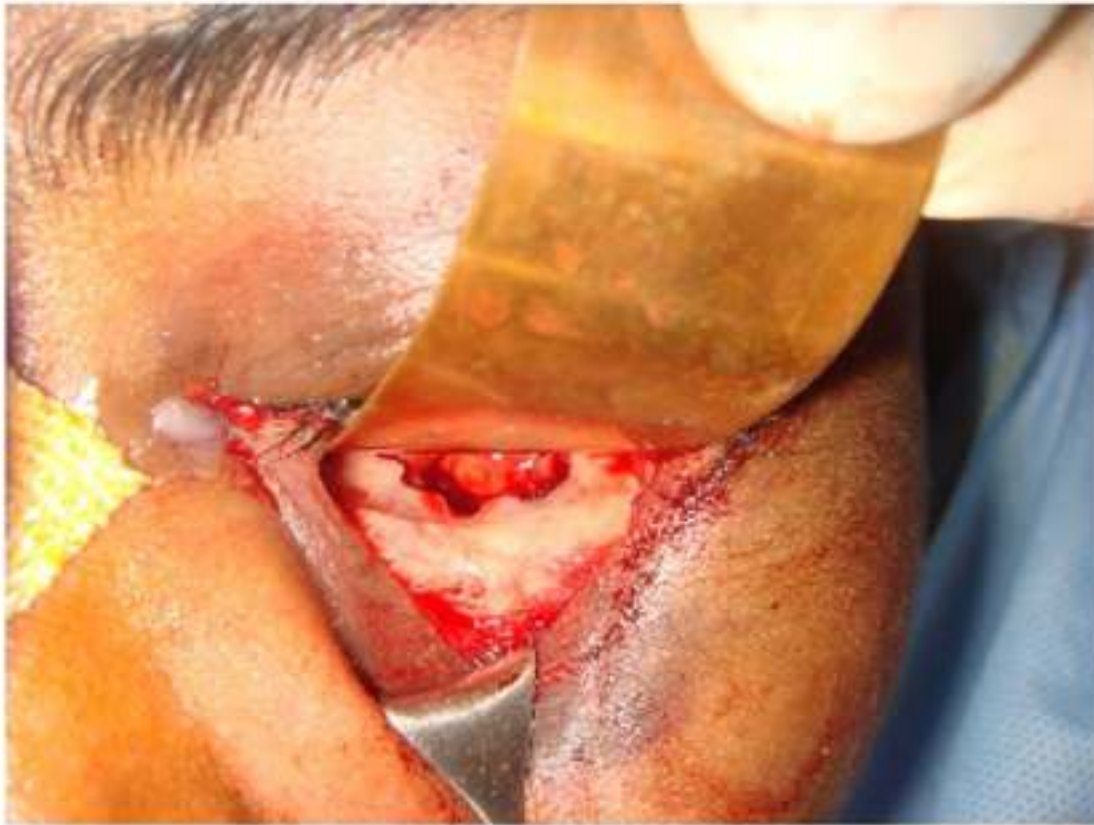
- Orbital blow out fracture
- Patient name - Mary priya
- Age / Sex – 32/f
- Hosp no – 0900086651

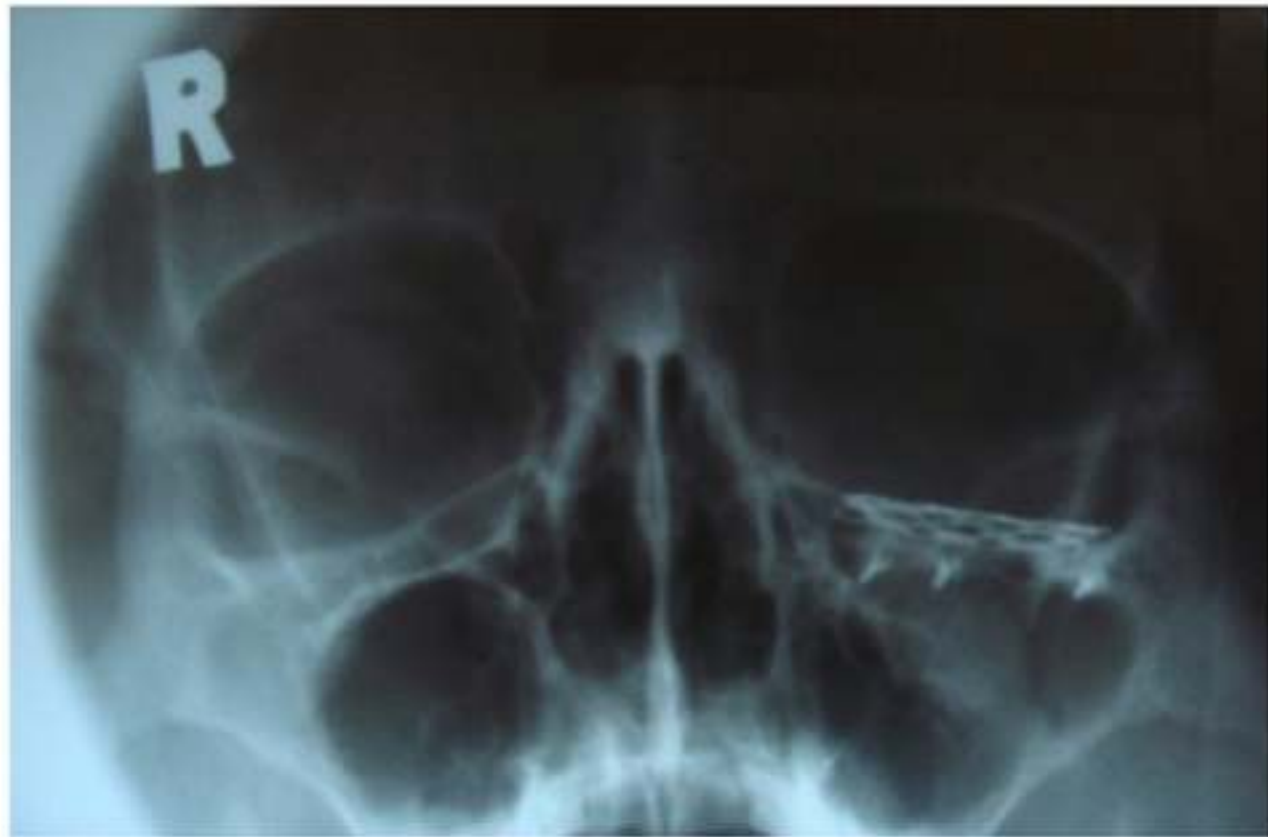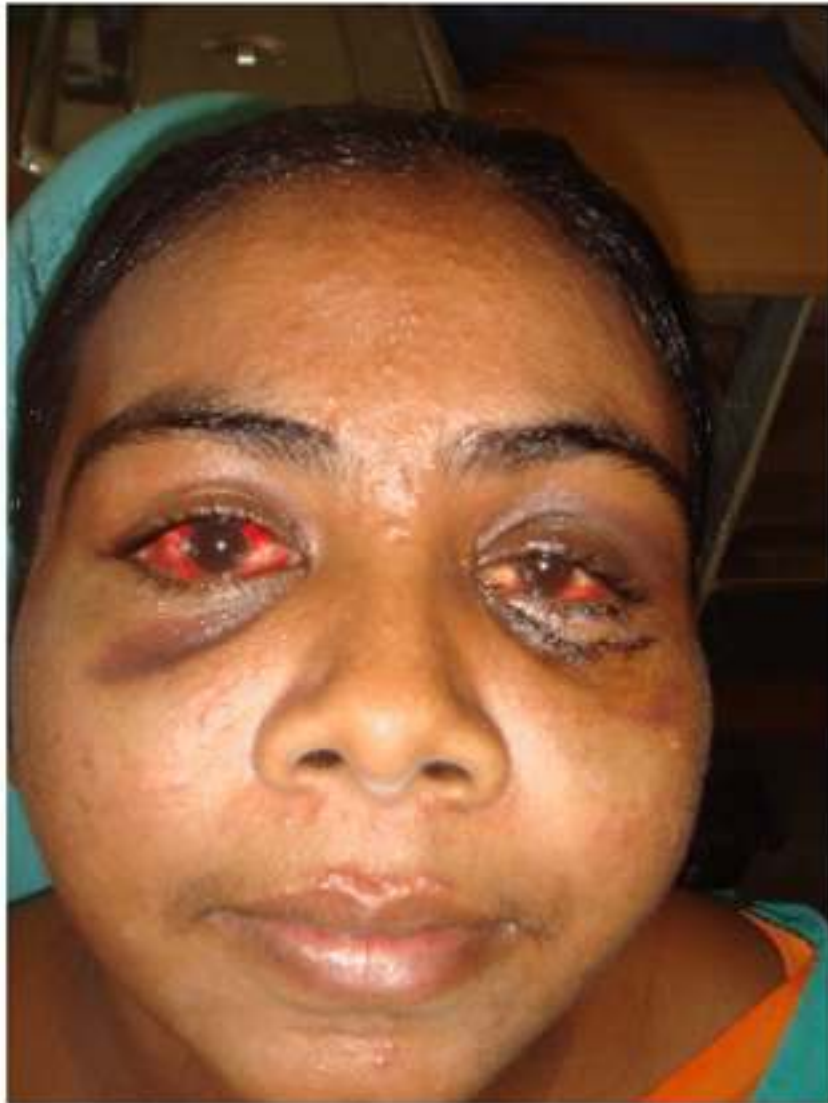PREOPERATIVE



INTRA-OPERATIVE

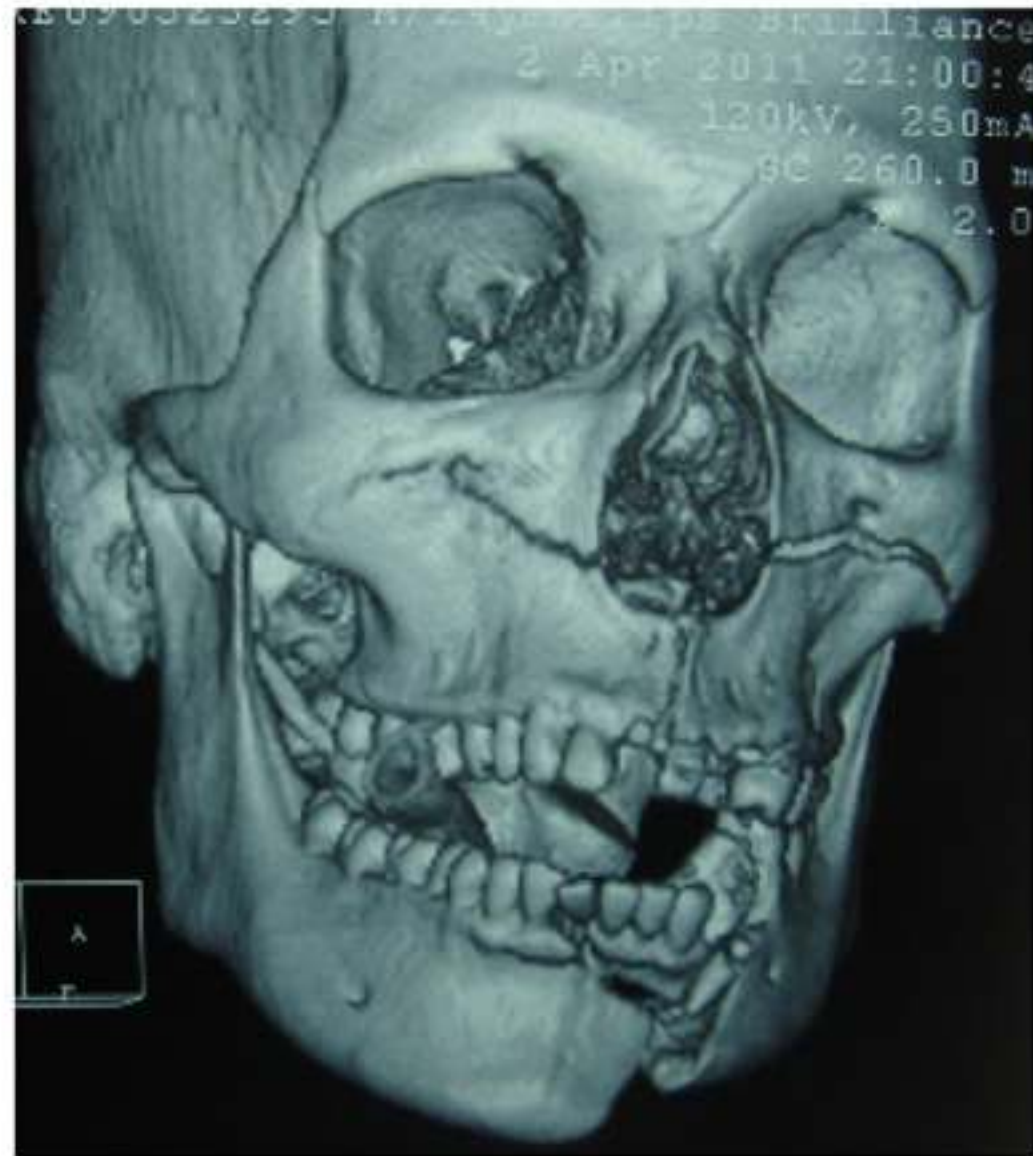
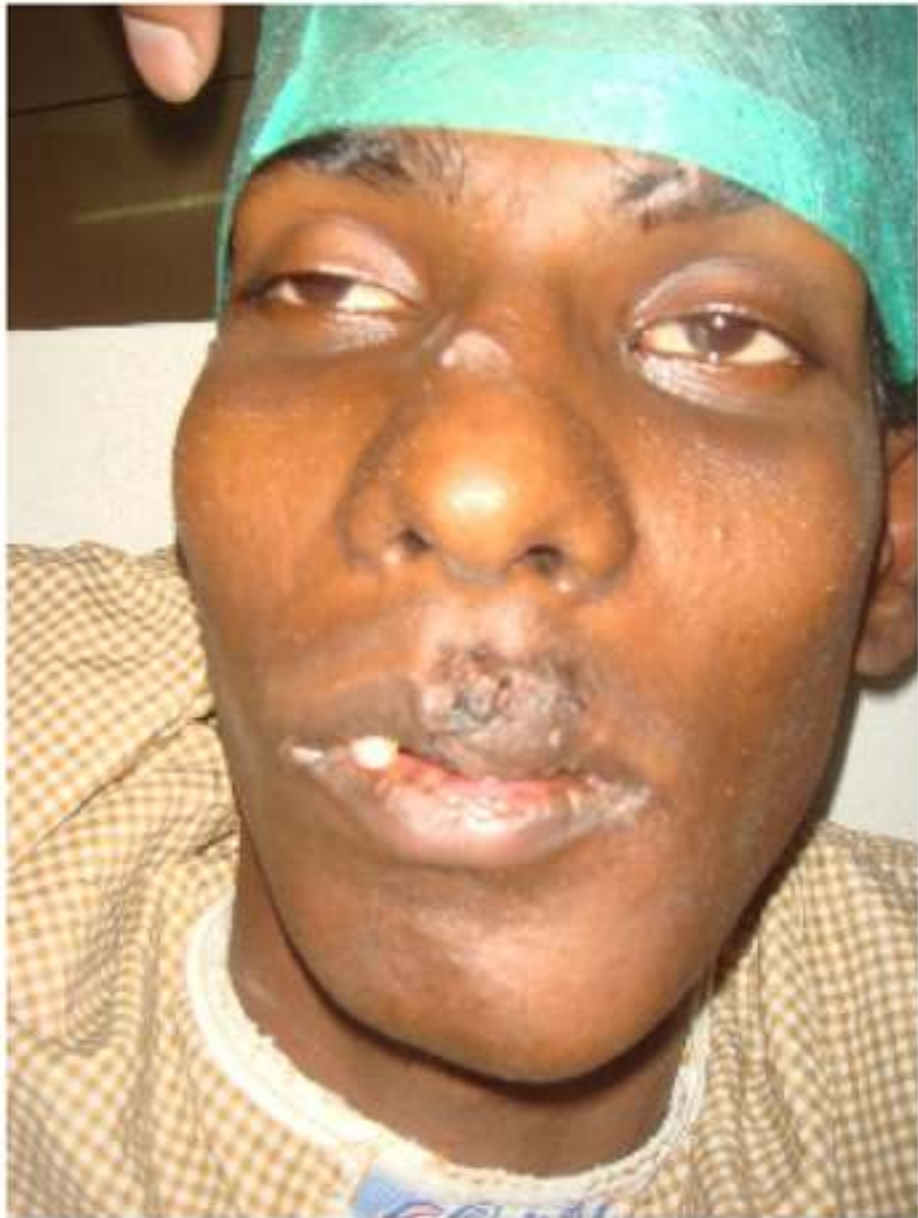
POST-OPERATIVE RECONSTRUCTION WITH TITANIUM MESH

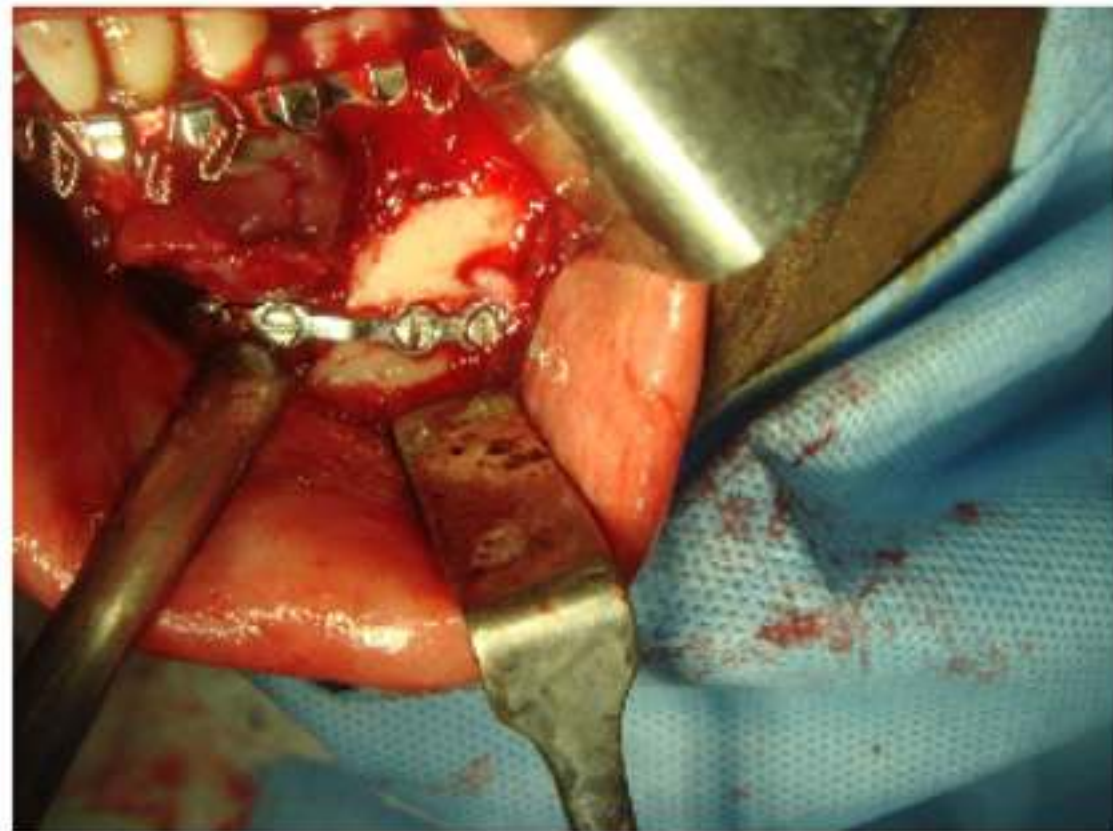
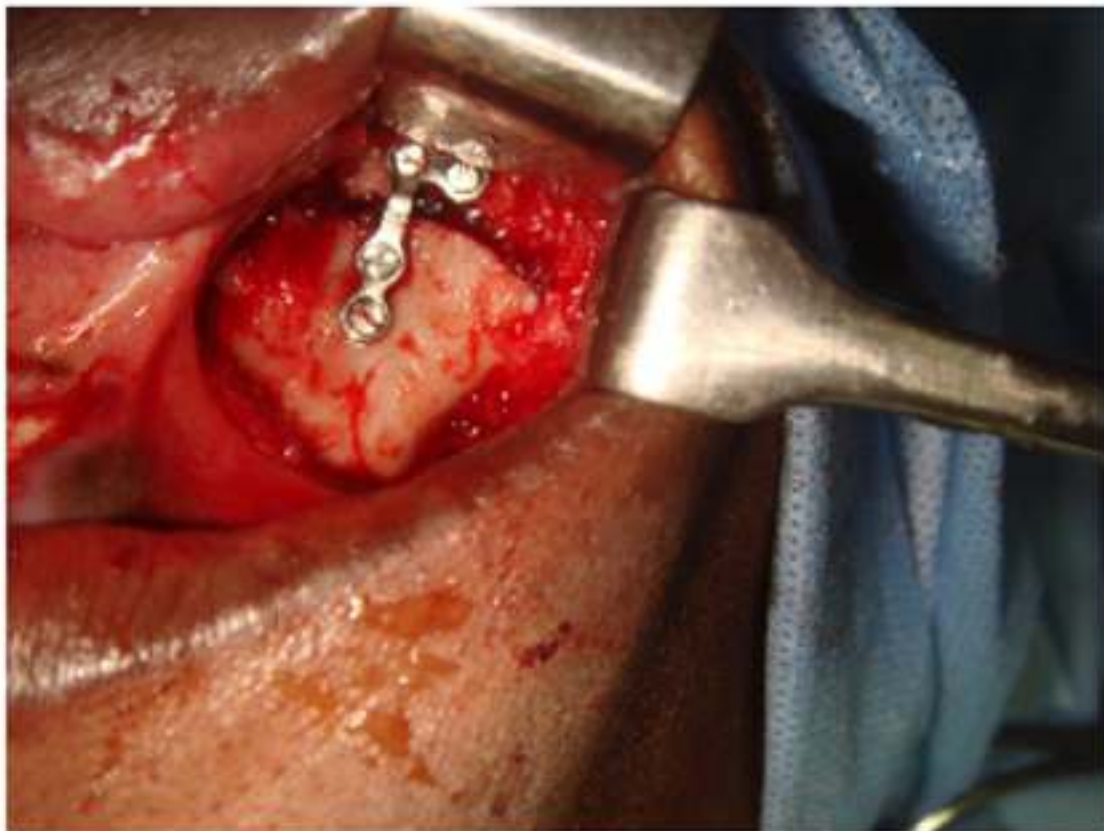


- LEFORT I fracture of maxilla & parasymphysis fracture of mandible
- Patient name- Mr Masilamani
- Age / Sex –
- Hosp no
- Date -

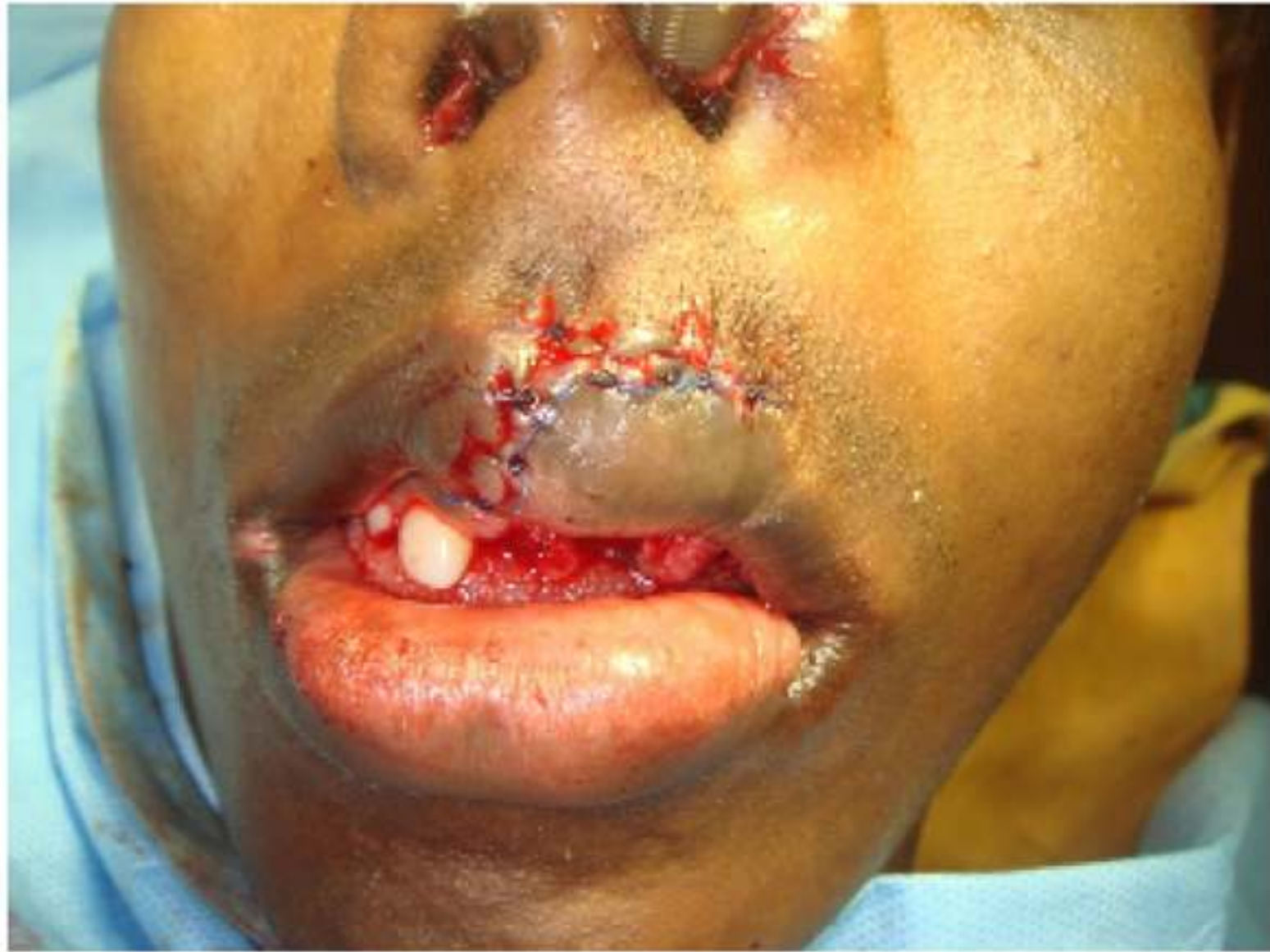PRE-OPERATIVE



INTRAOPERATIVE

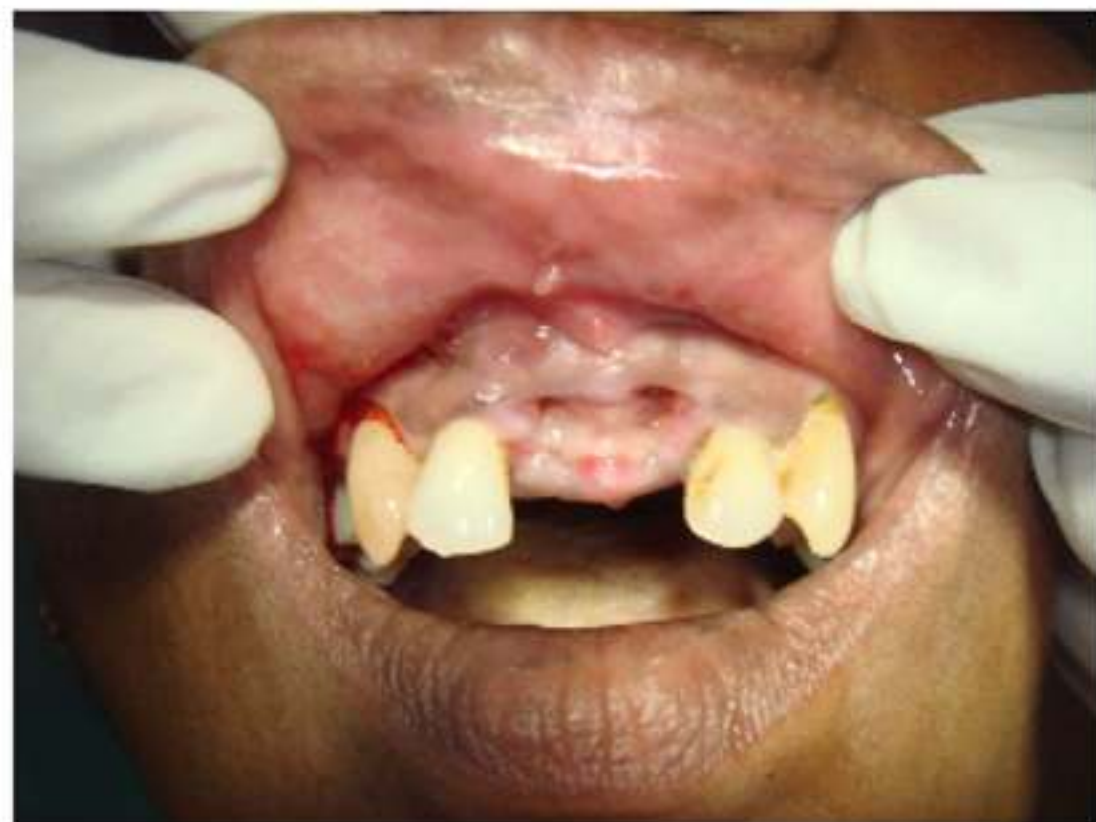
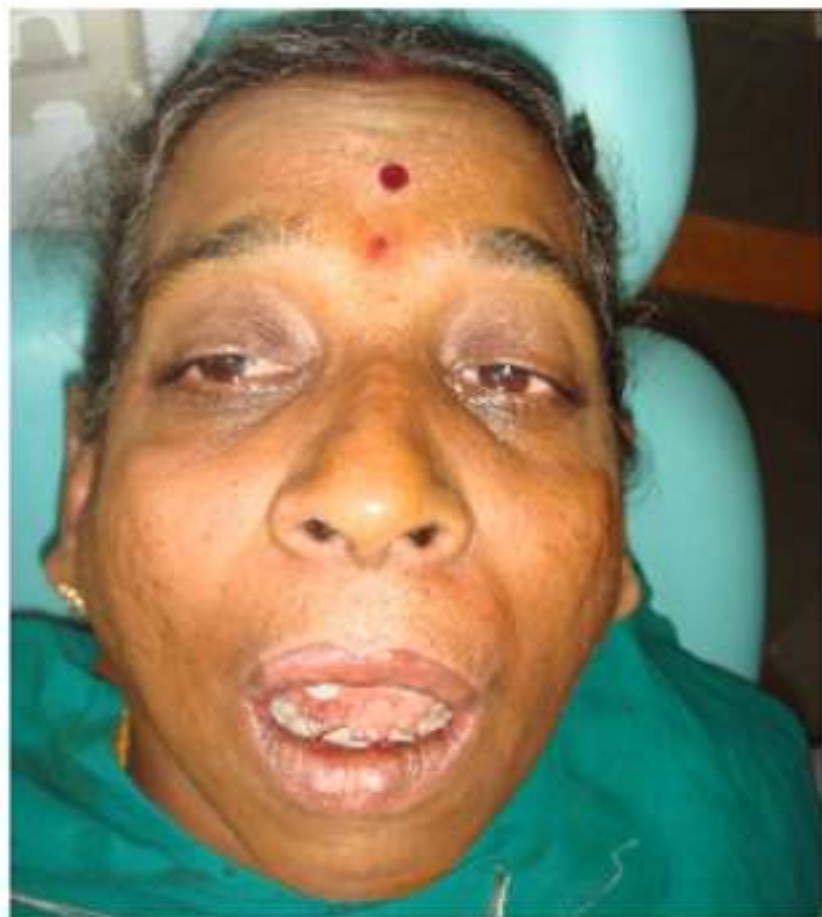
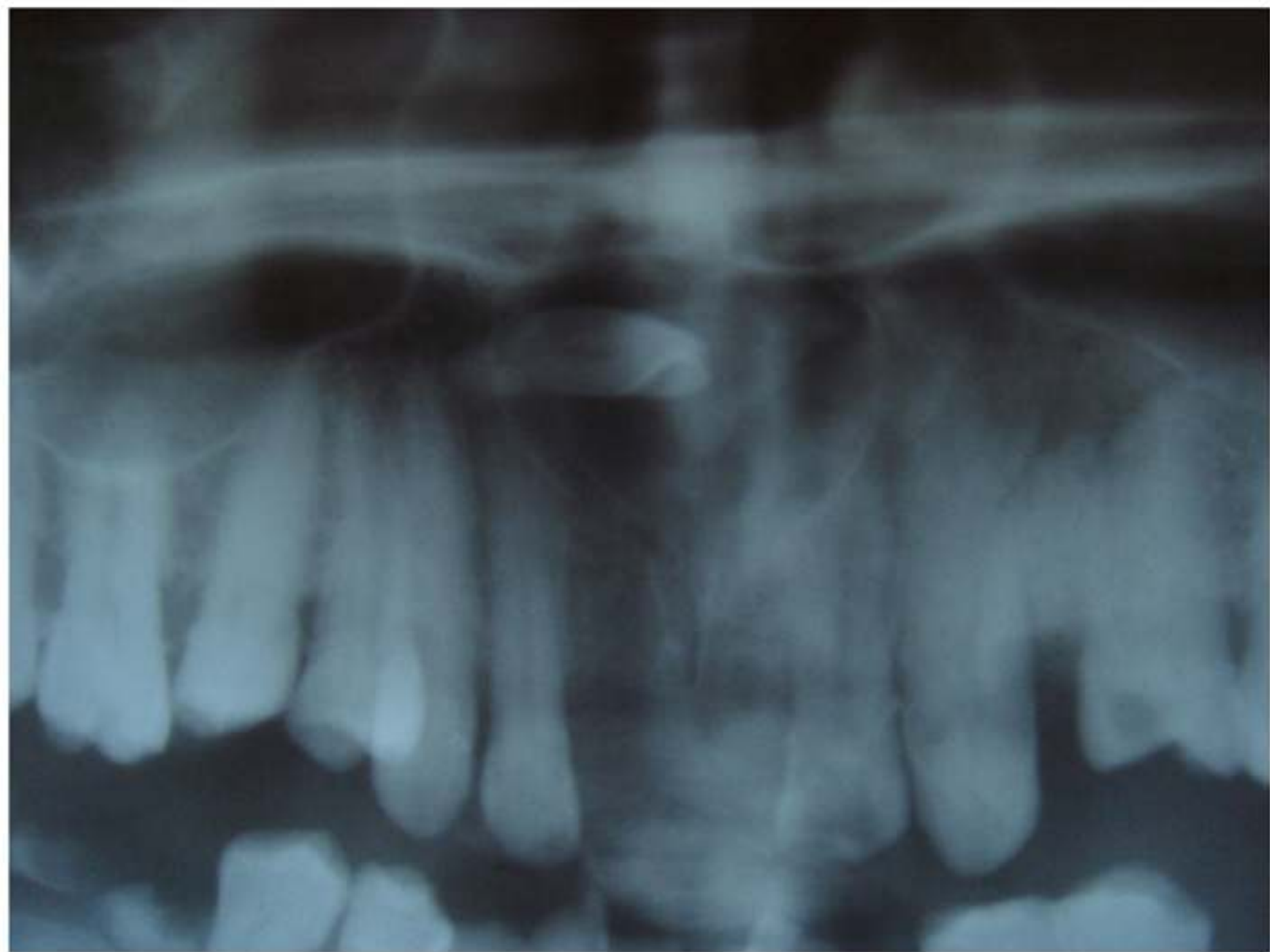POST OPERATIVE VIEW



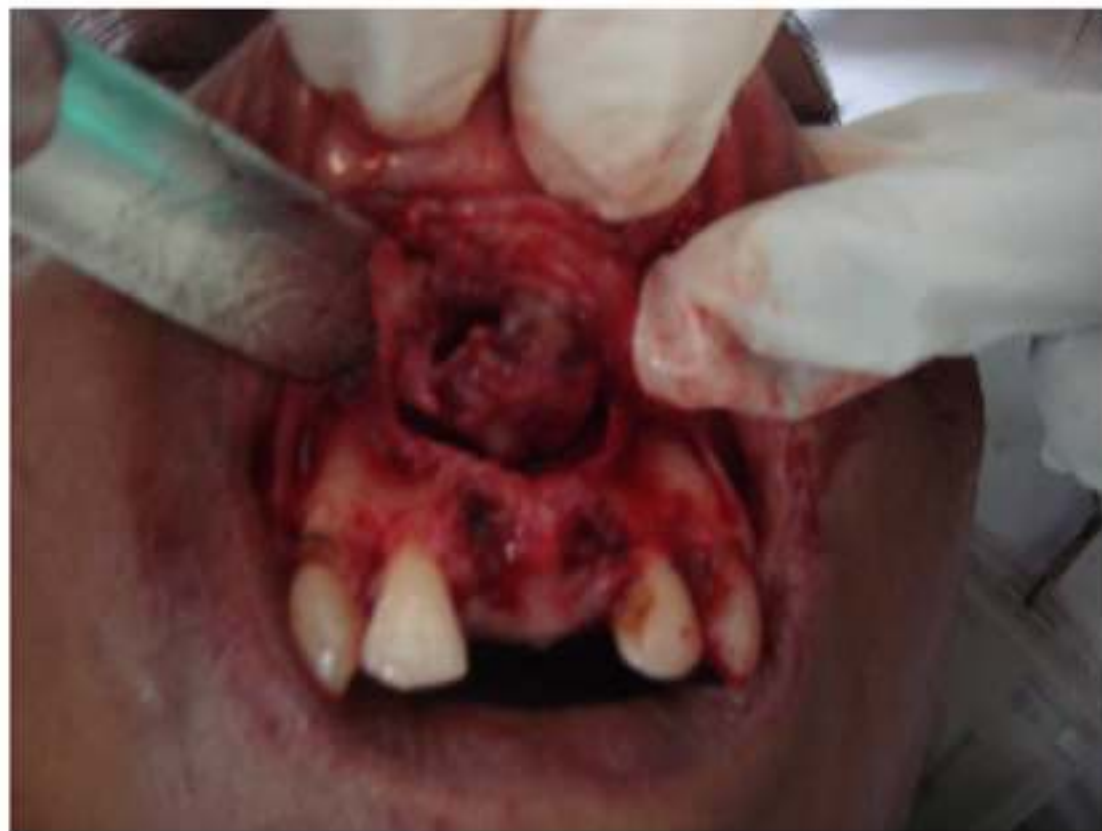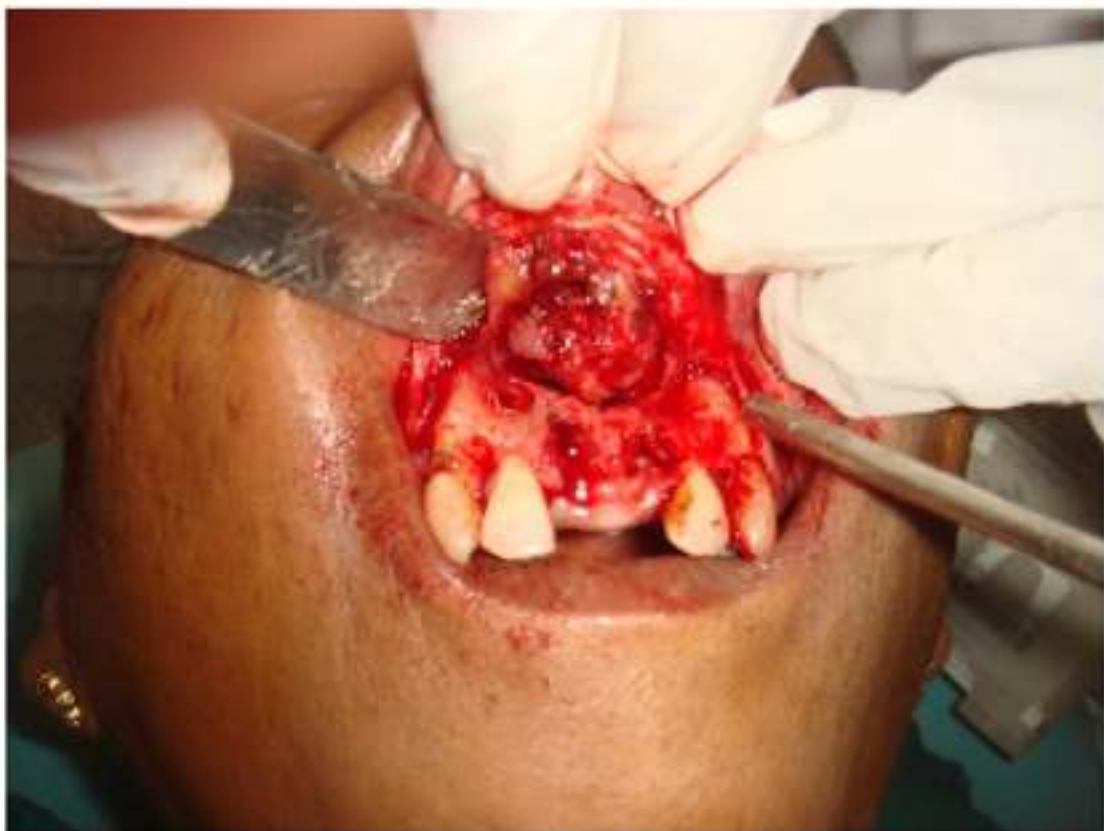Nasopalatine duct cyst

Pre Operative

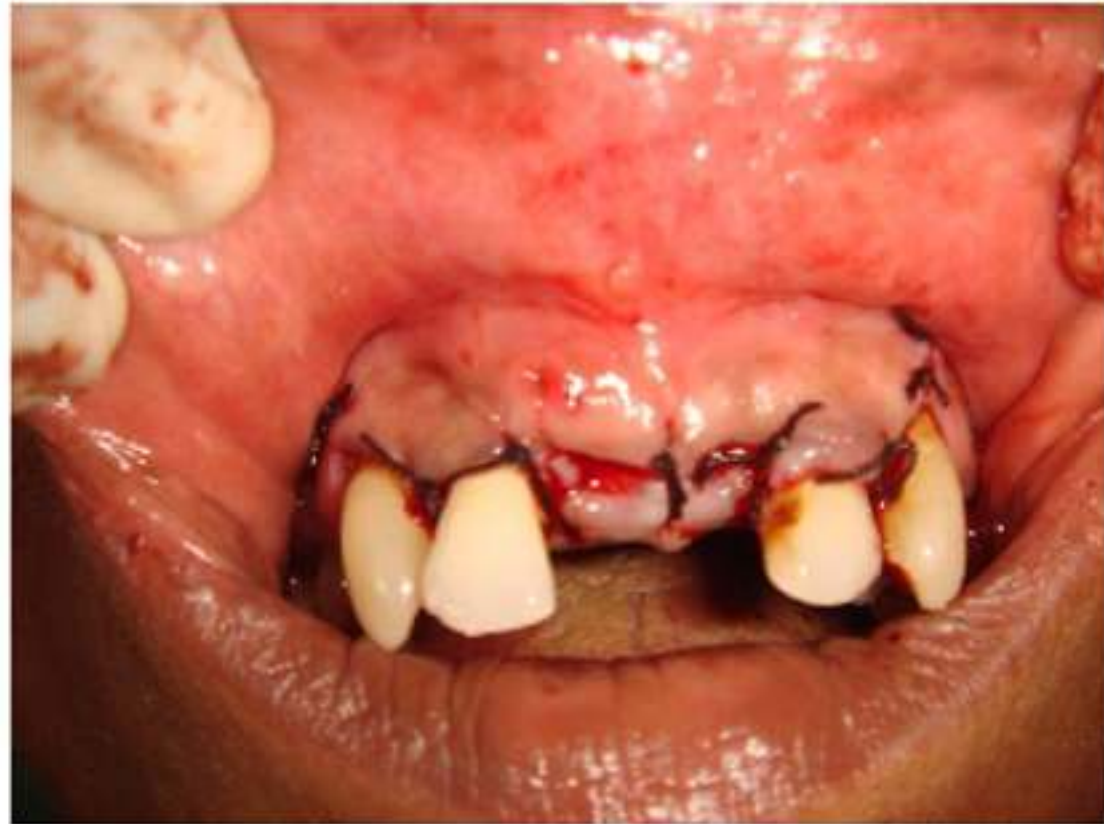
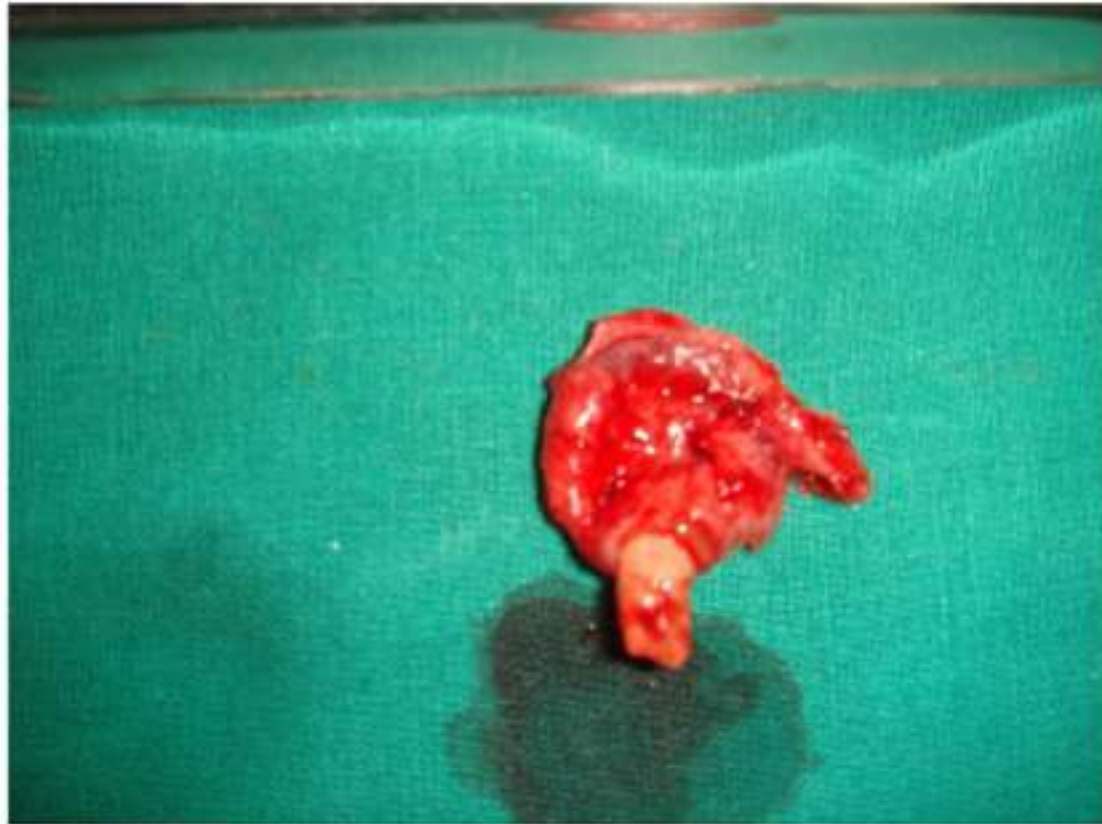


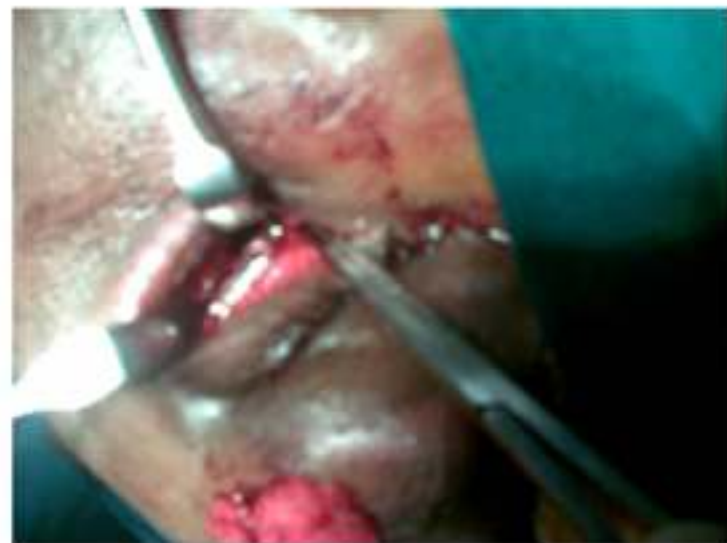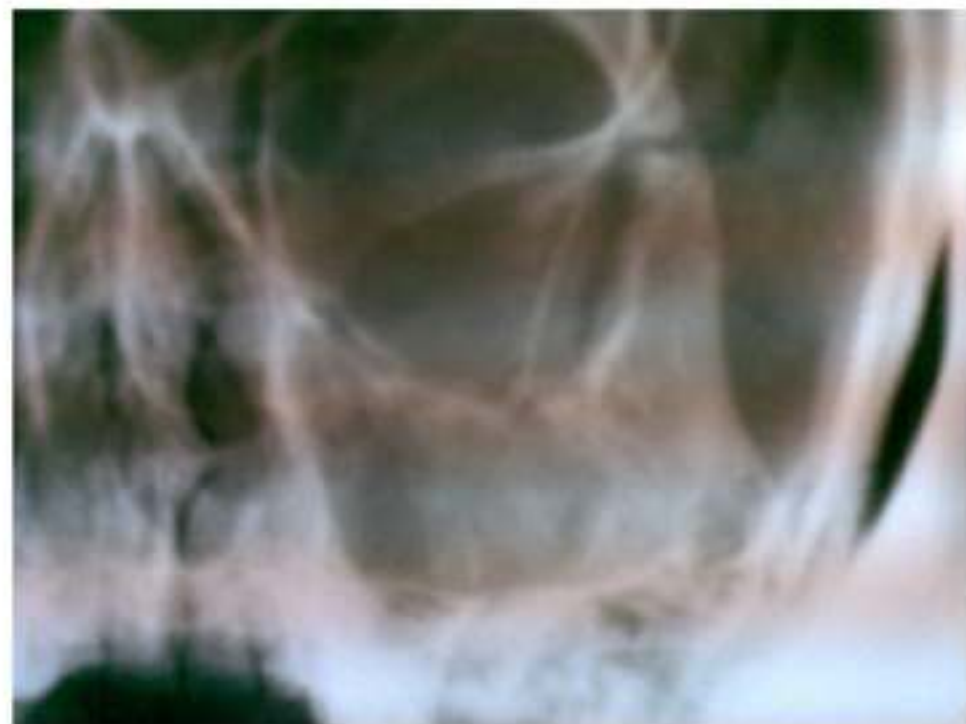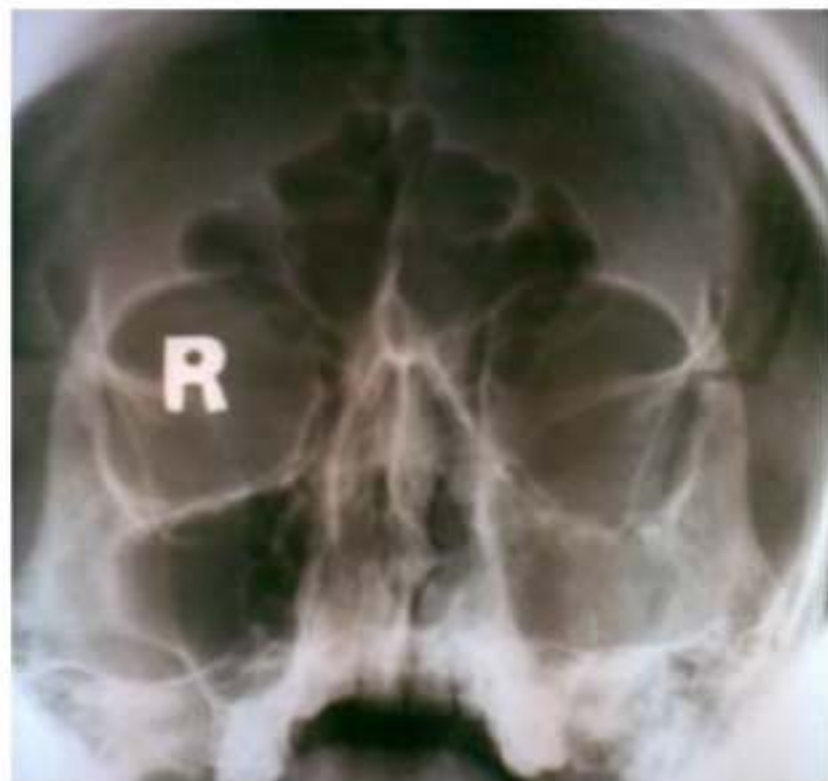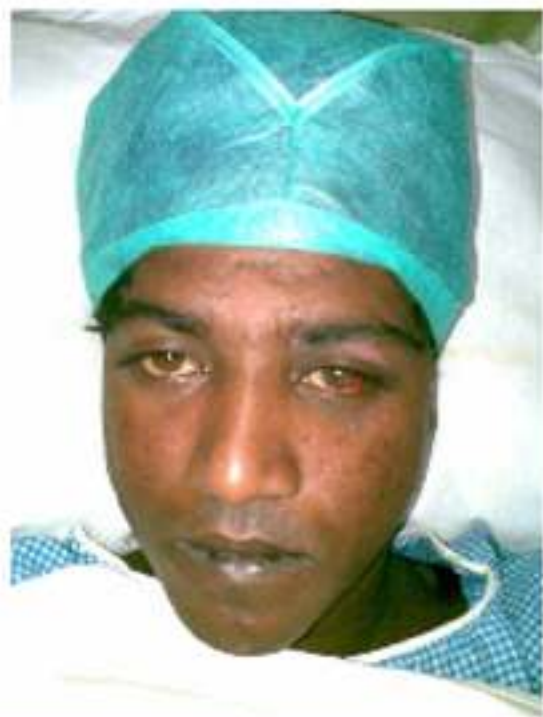Intra operative



Post Operative



- Left Zygomatic complex fracture
- Patient name –Mr Palanivelu
- Age / Sex – 44/M
- Date – 7/3/2009

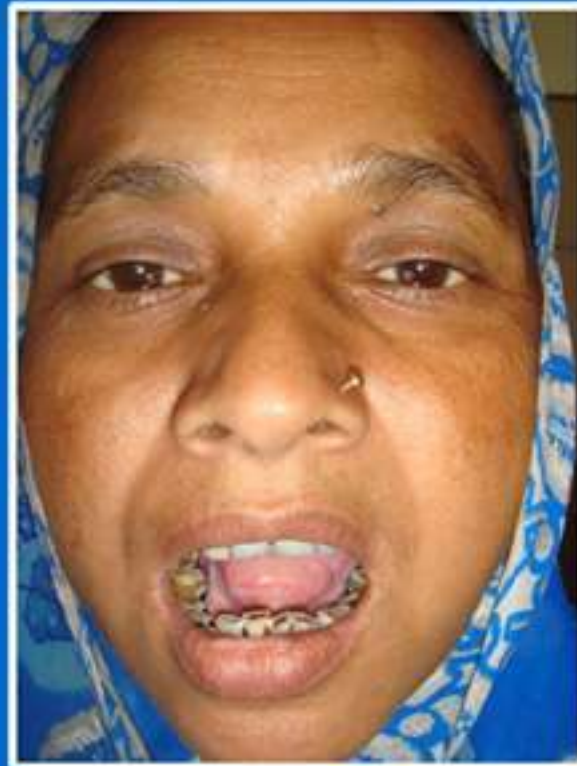

ORAL SUBMUCOUS FIBROSIS

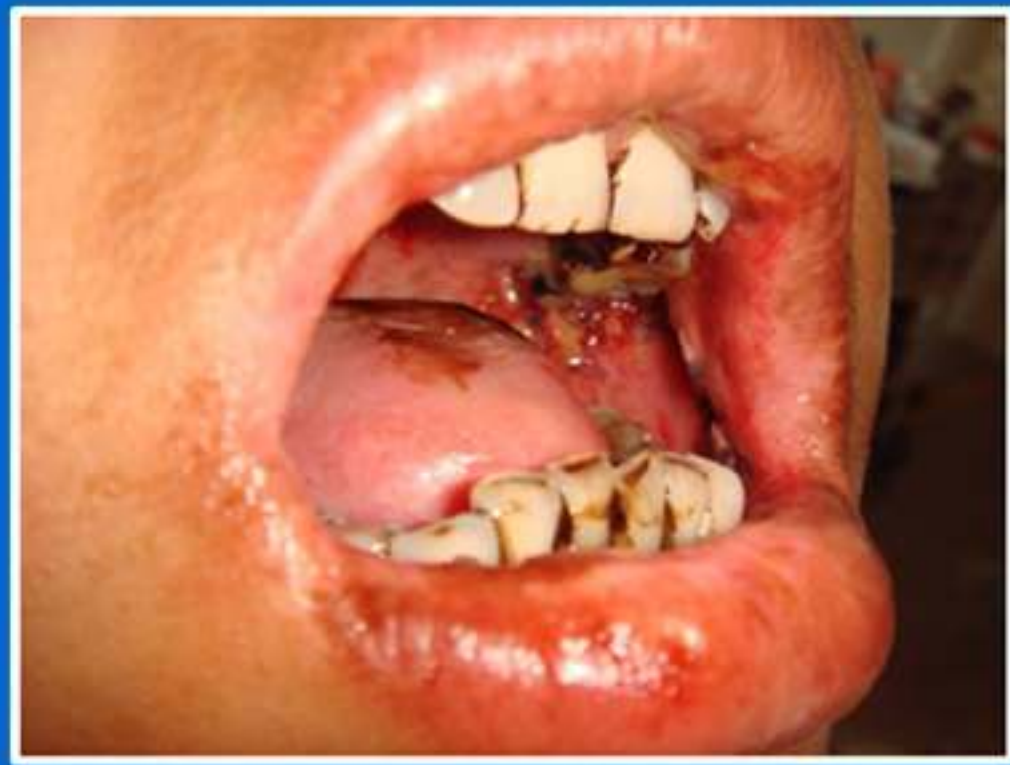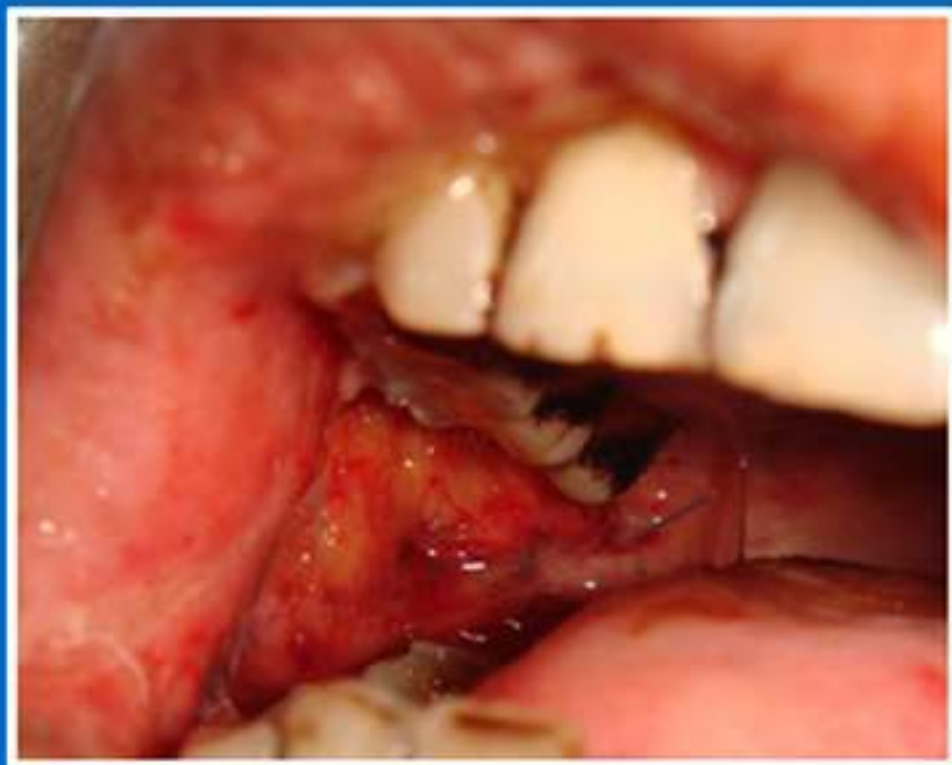Patient Name: Hajeeya Beevi

Treatment Given: Surgical release of fibrous bands, Buccal pad of fat grafting over raw area, bilateral coronoidectomy and extraction of all third molars

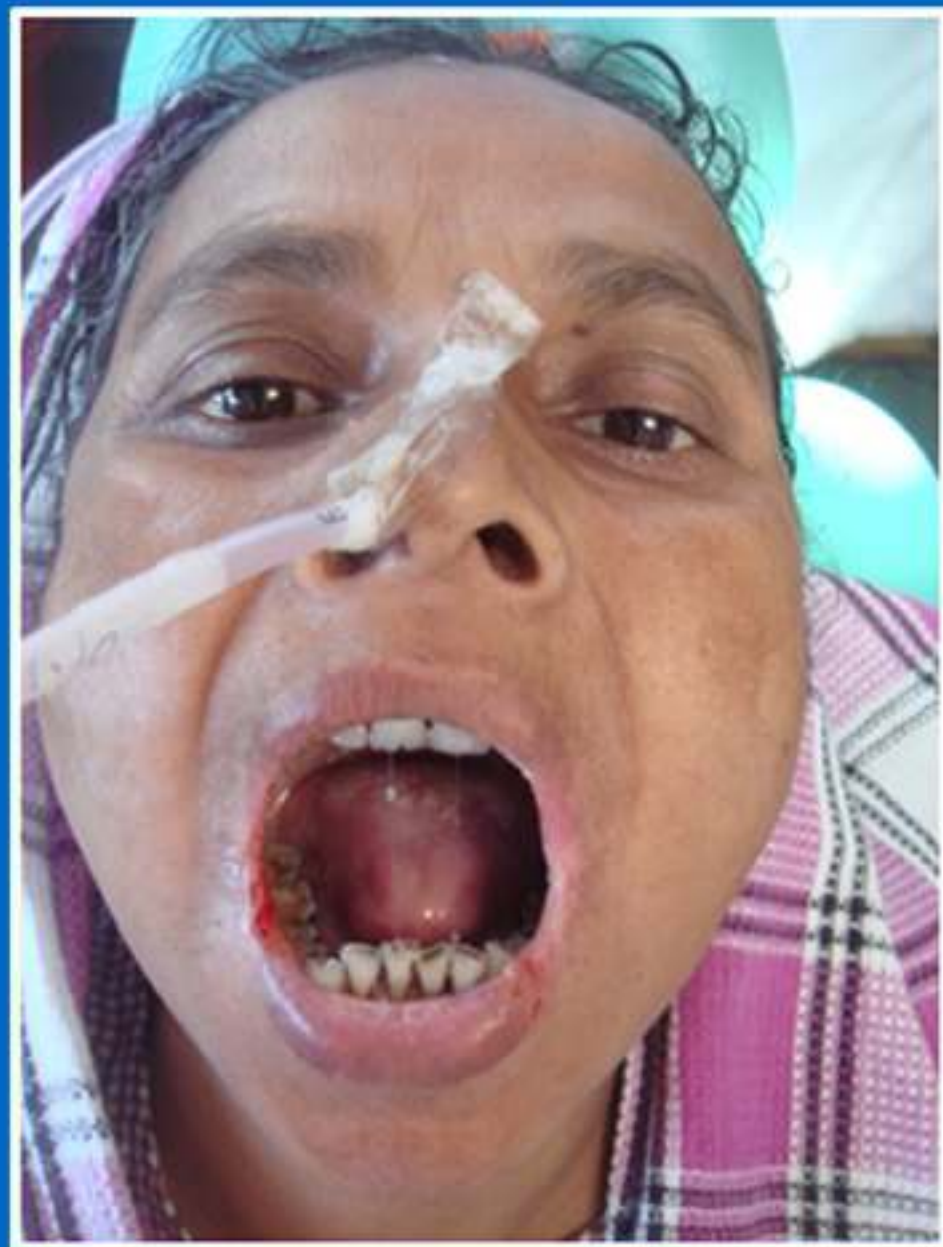Preoperative:



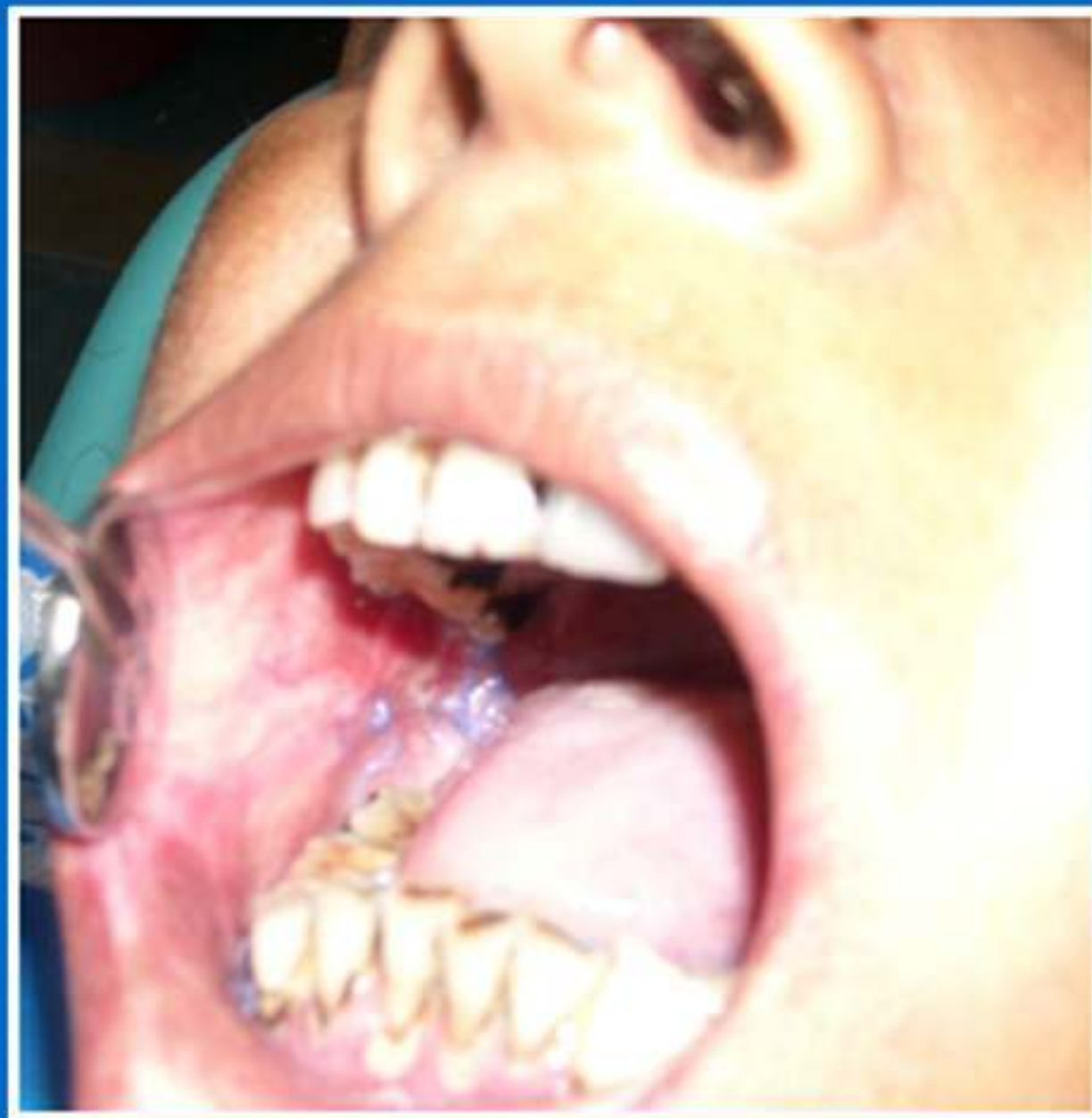Intra operative: (Surgical release of bands and buccal pad of fat grafting)



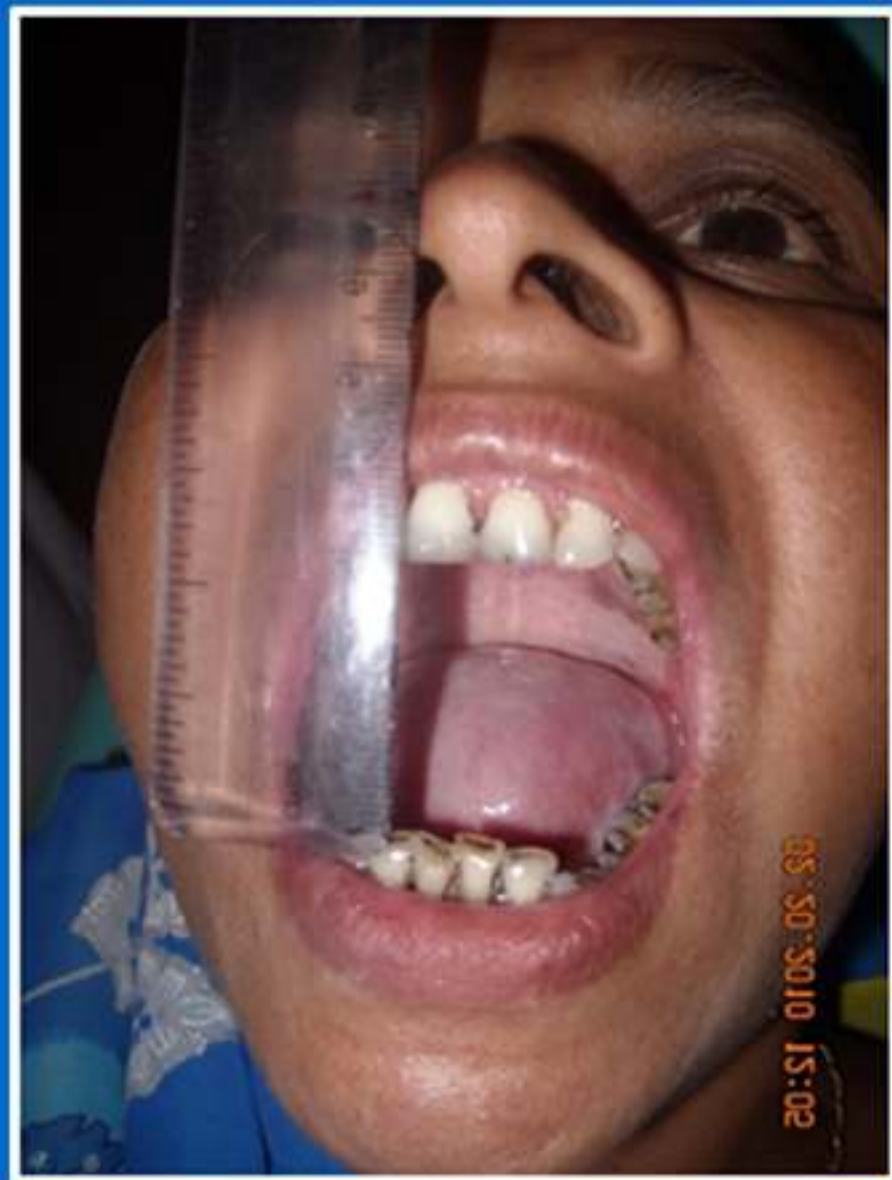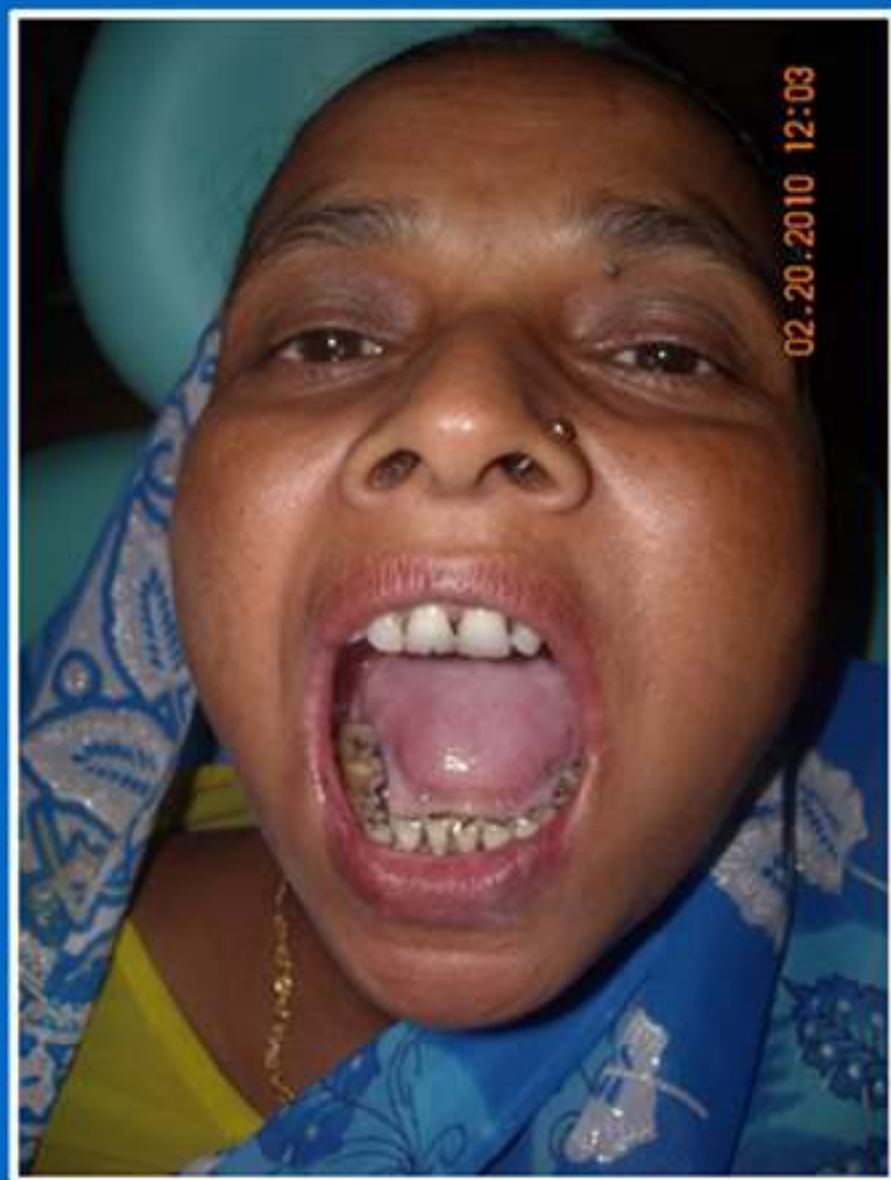Immediate postoperative:



Intra oral view showing good take up of Buccal pad of fat:

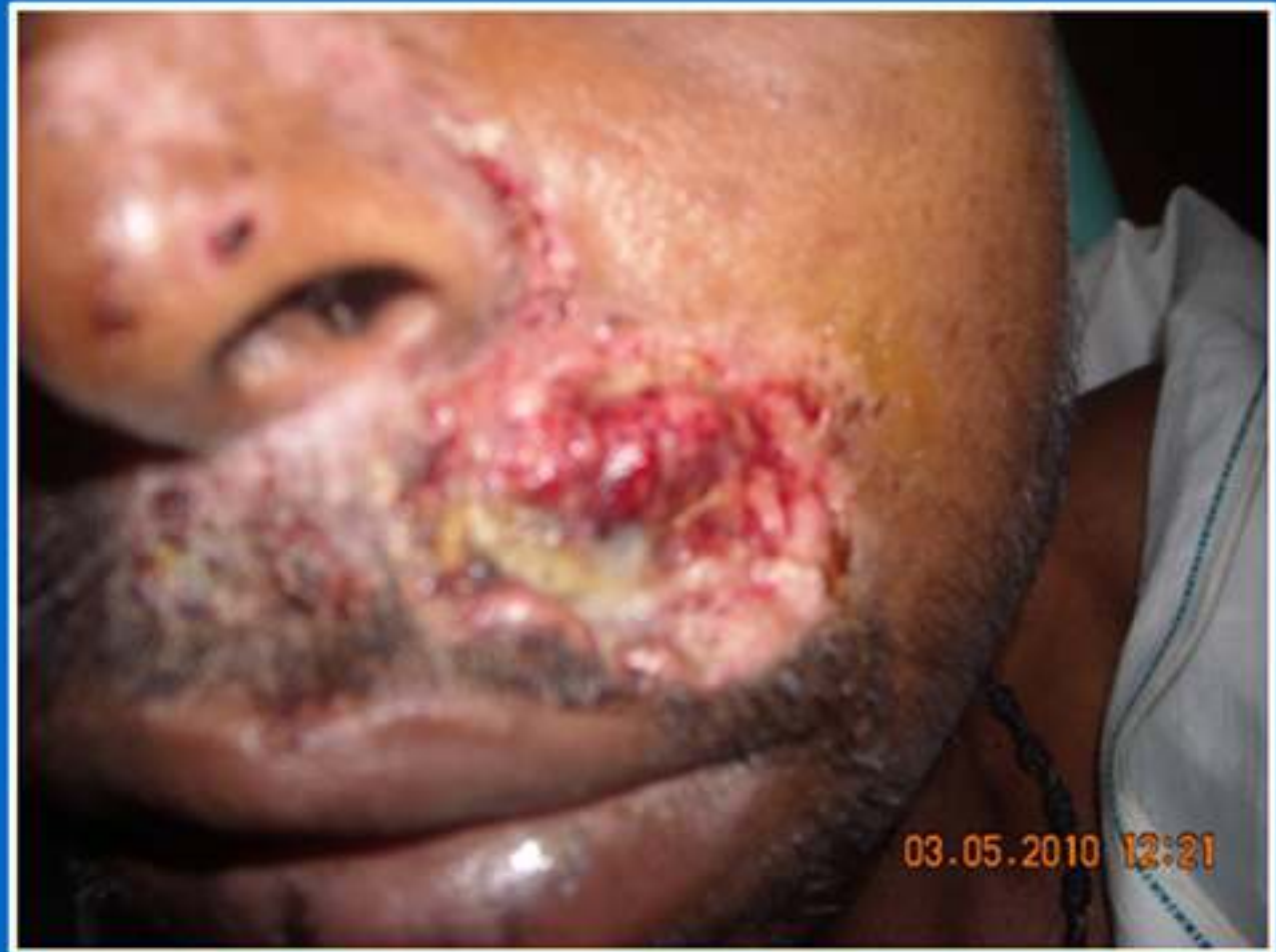
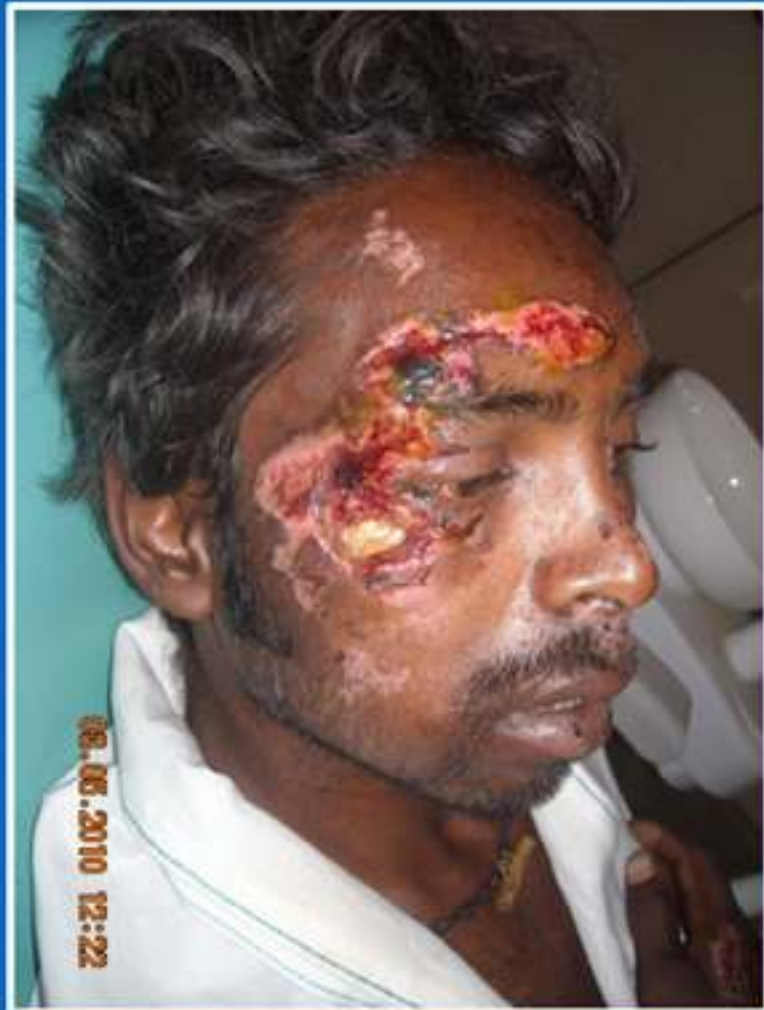
Post operative (6months):

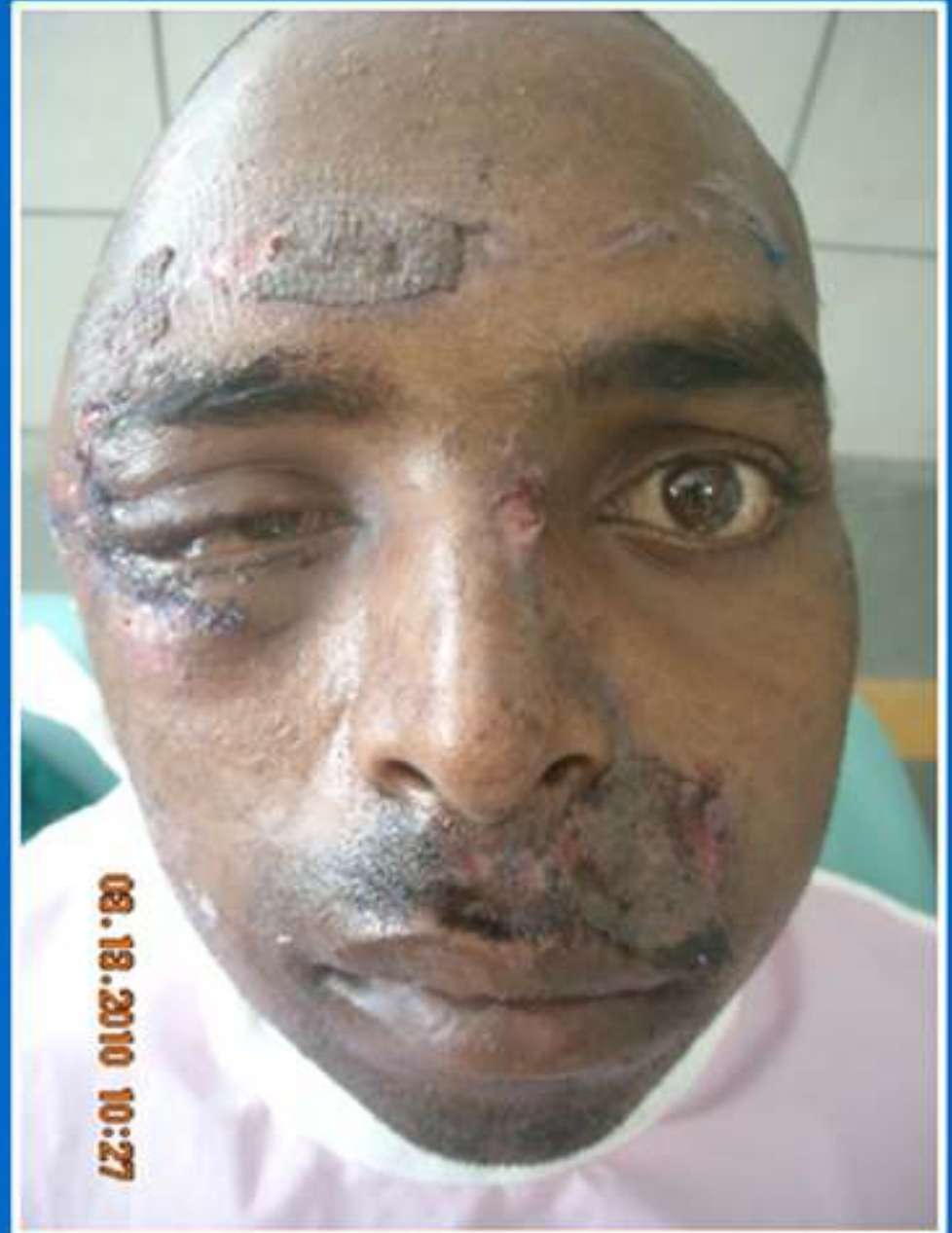
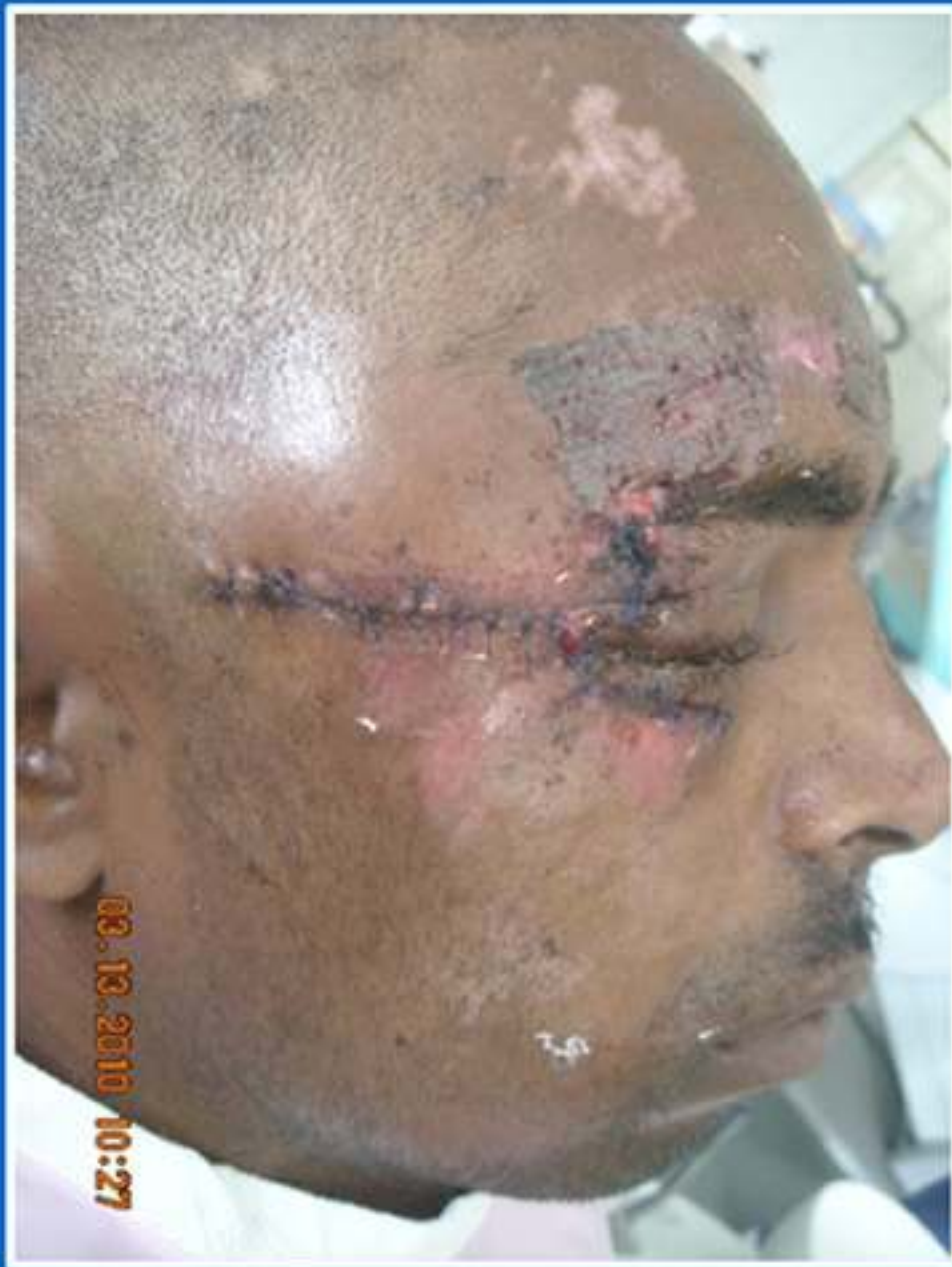
SOFT TISSUE INJURY OF FACE

Preoperative:

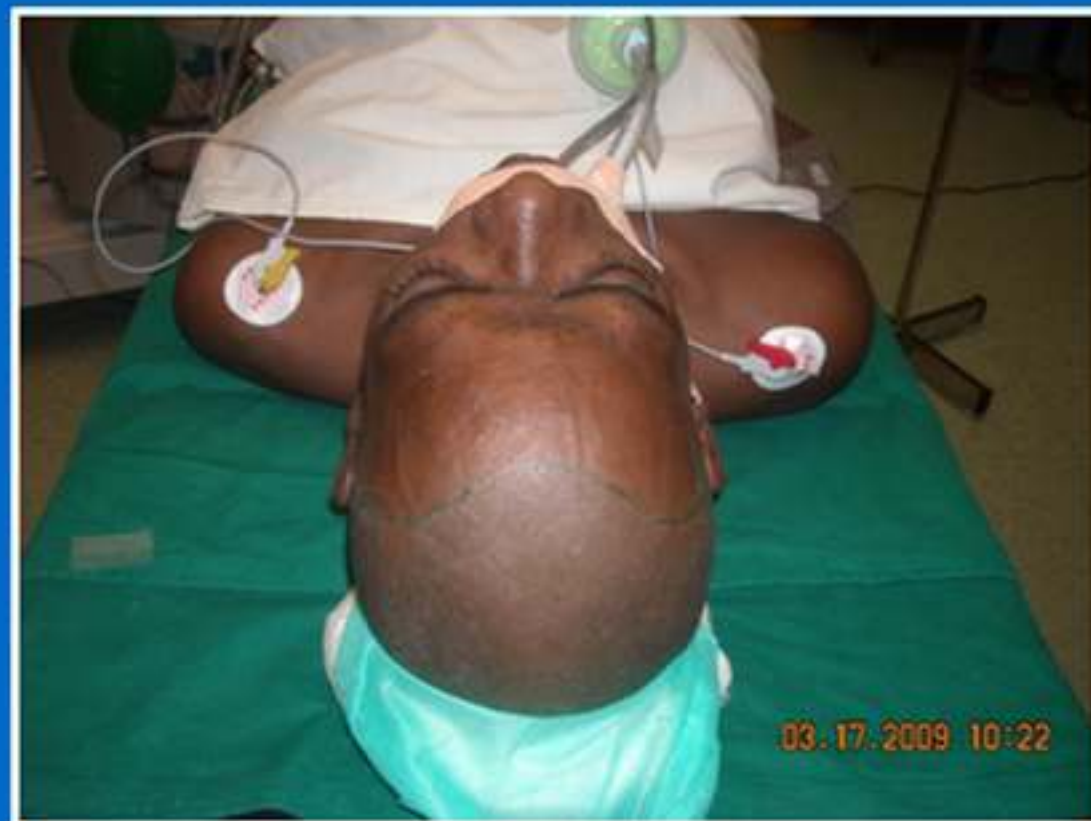
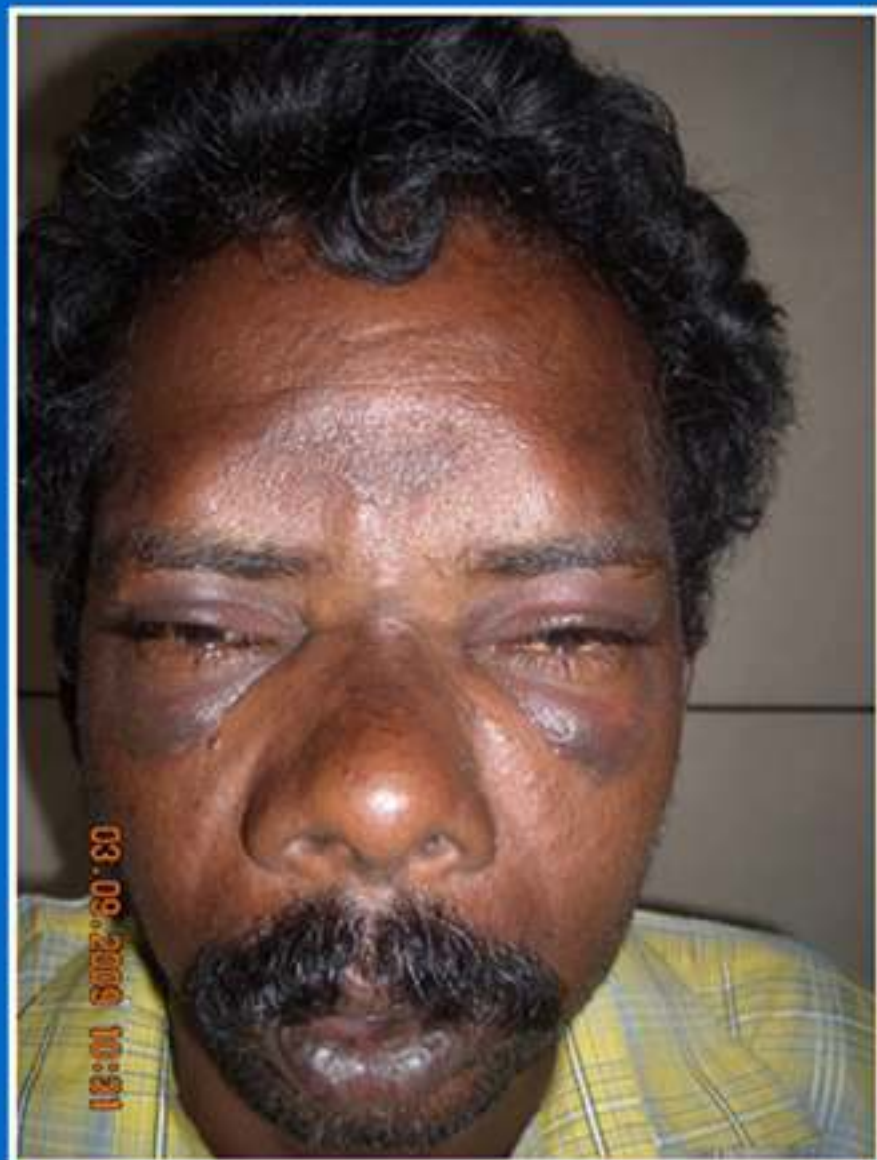
Postoperative (after suturing and split skin grafting):

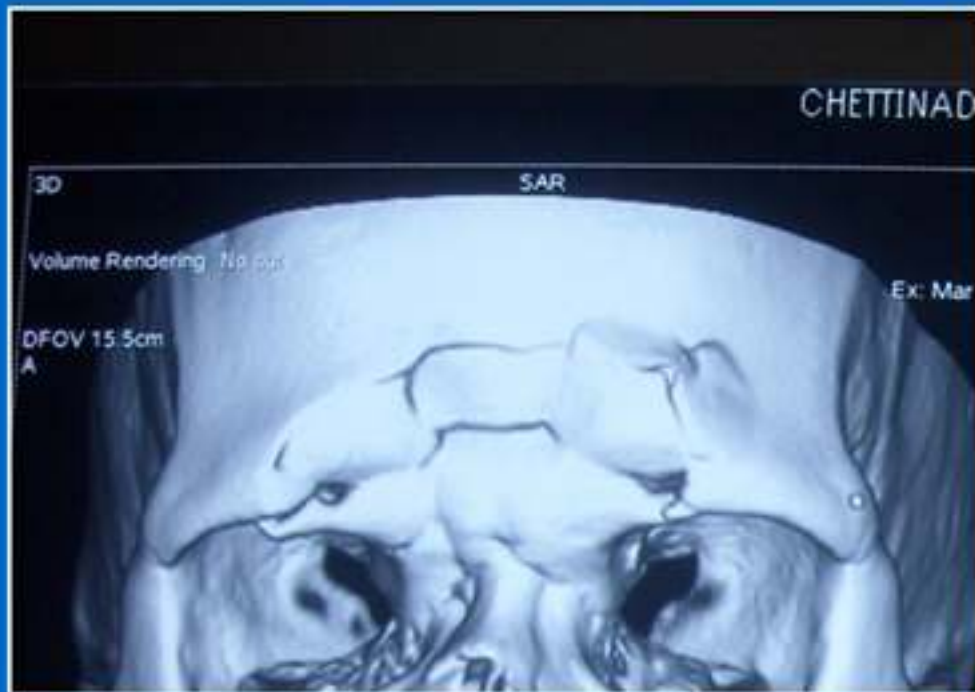

FRONTAL BONE FRACTURE

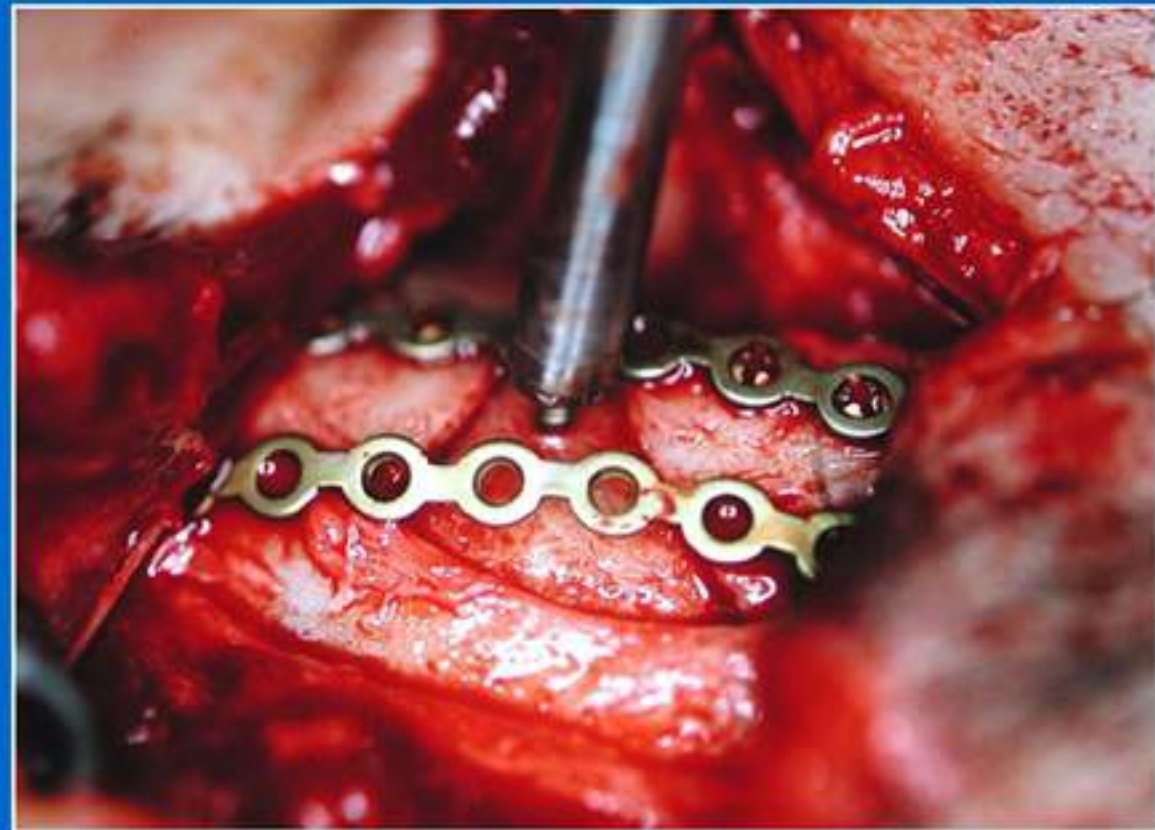
Preoperative:



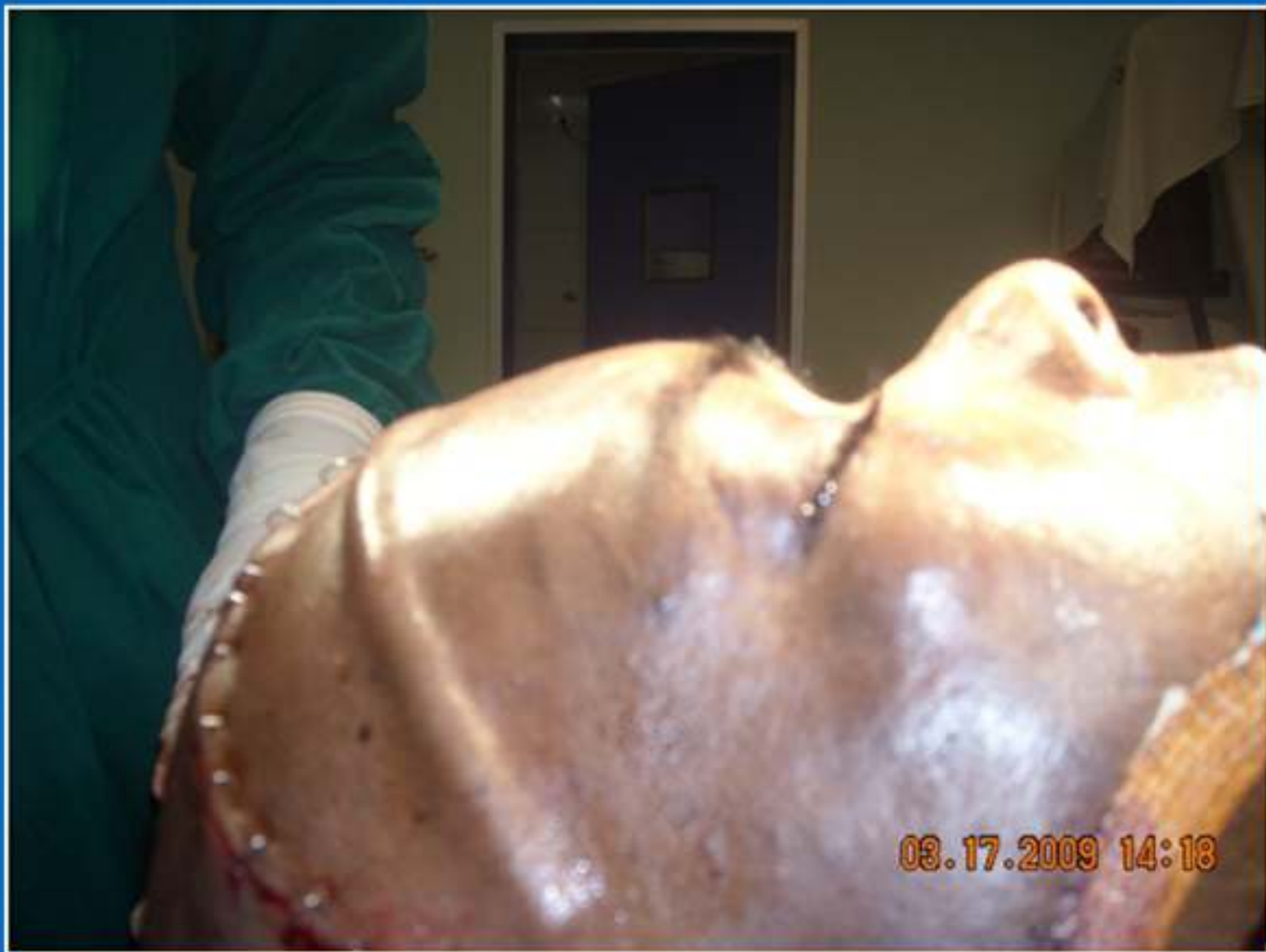CT scan picture:



Intra operative: (Fracture reduction and fixation)

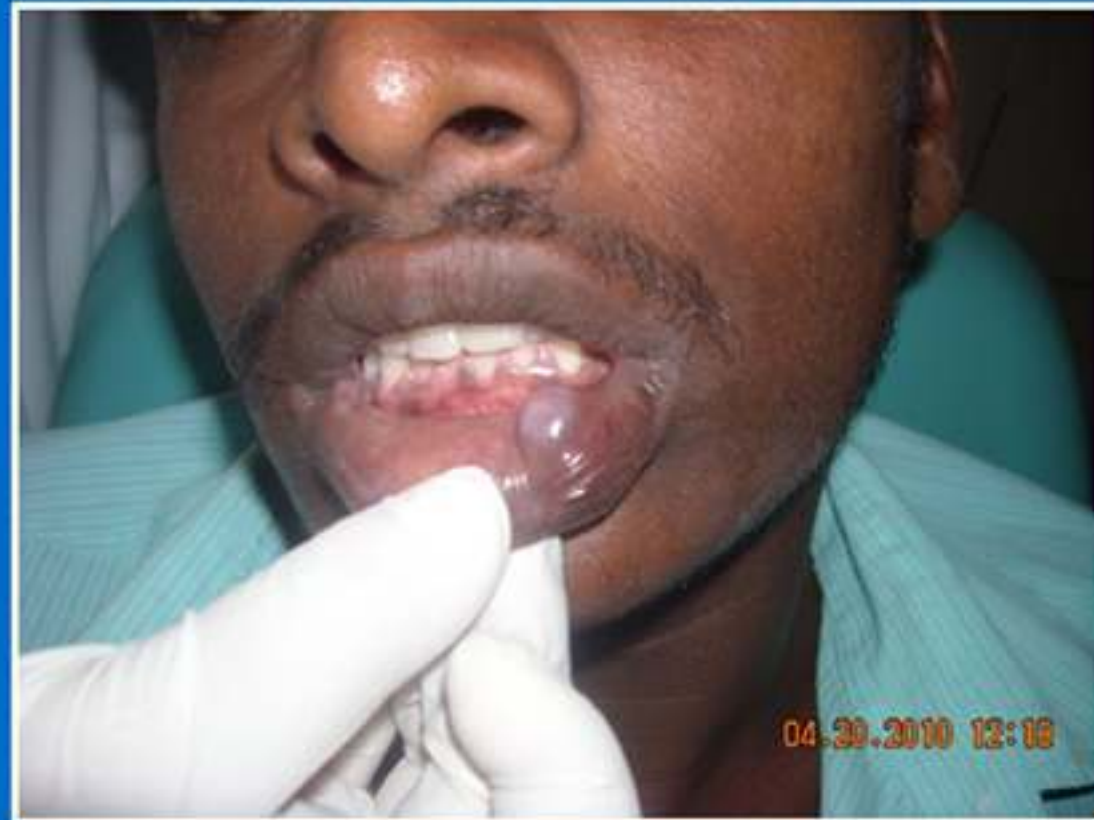
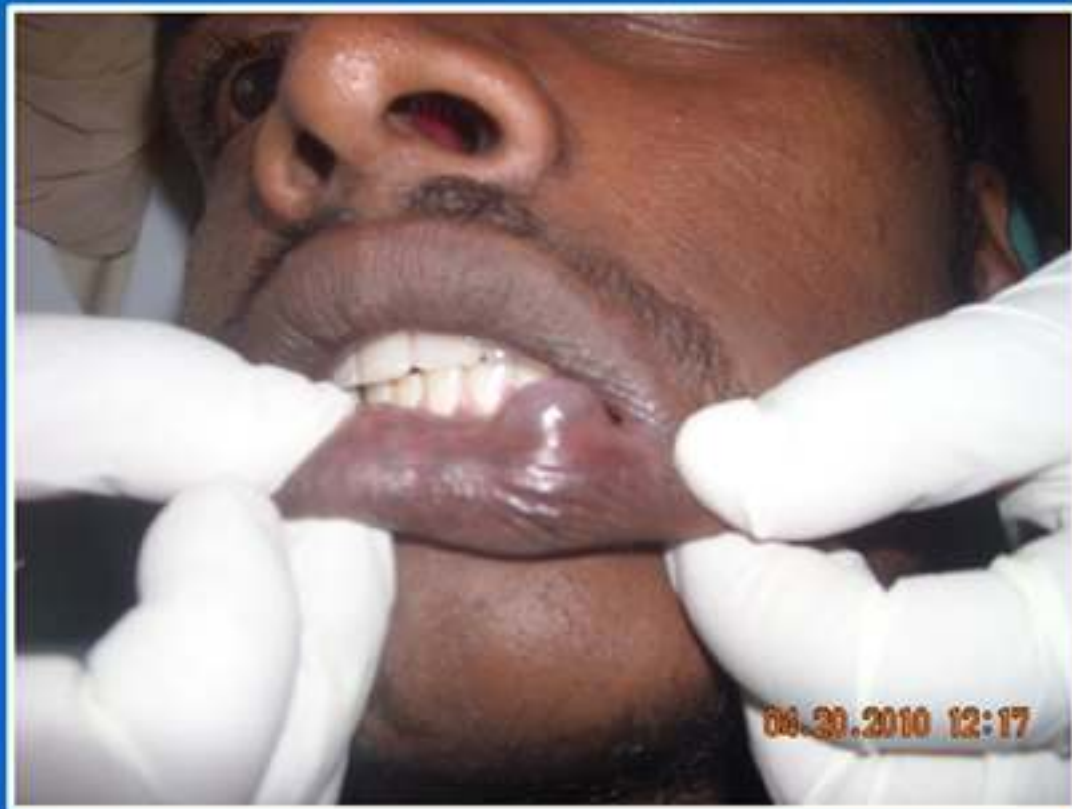
Postoperative:

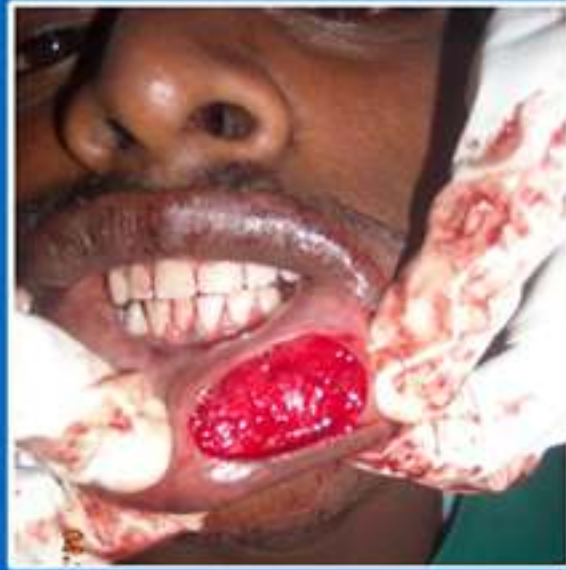

MUCOCELE OF LOWER LIP

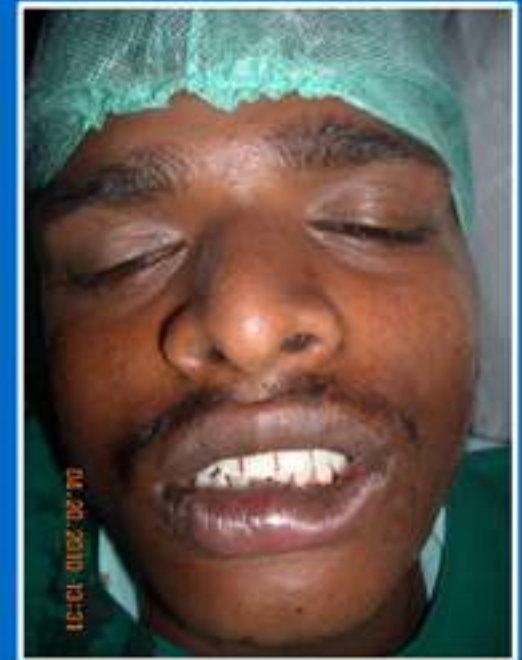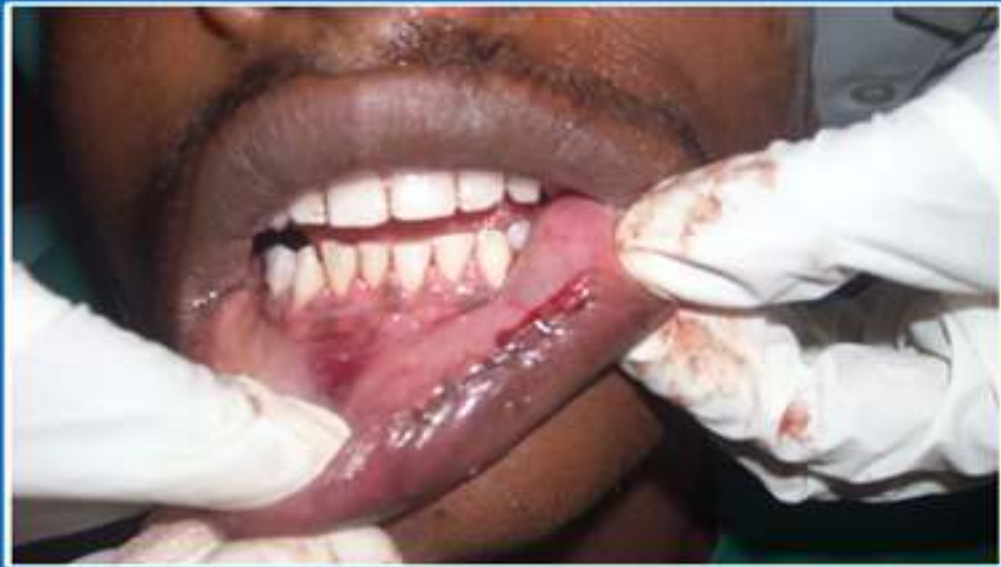Preoperative:



Intra operative (after excision):

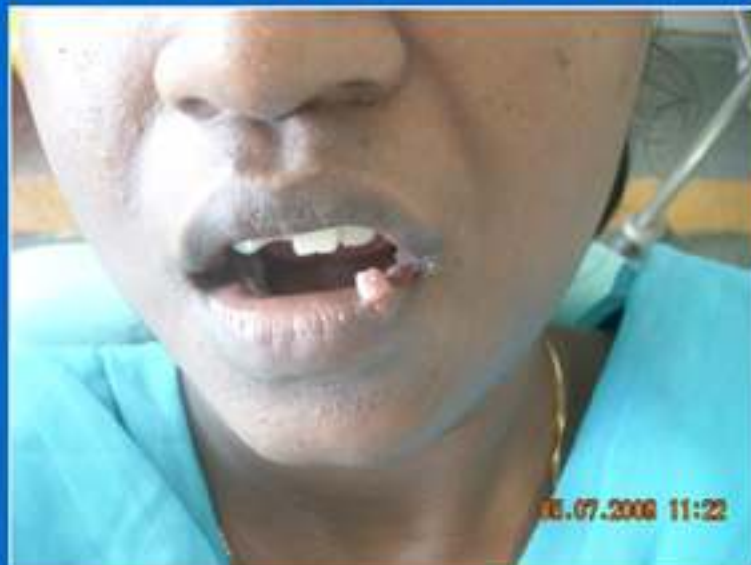

Postoperative:

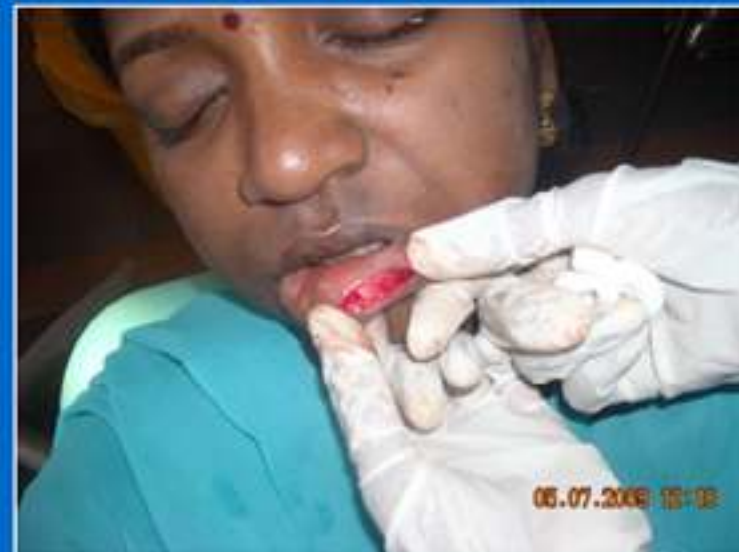

CAPILLARY HEMANGIOMA OF LOWER LIP

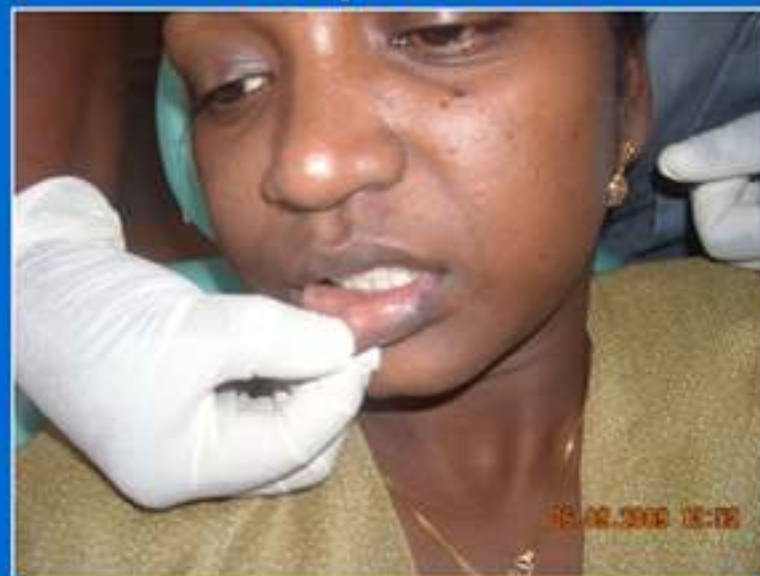Preoperative:



Intra operative:

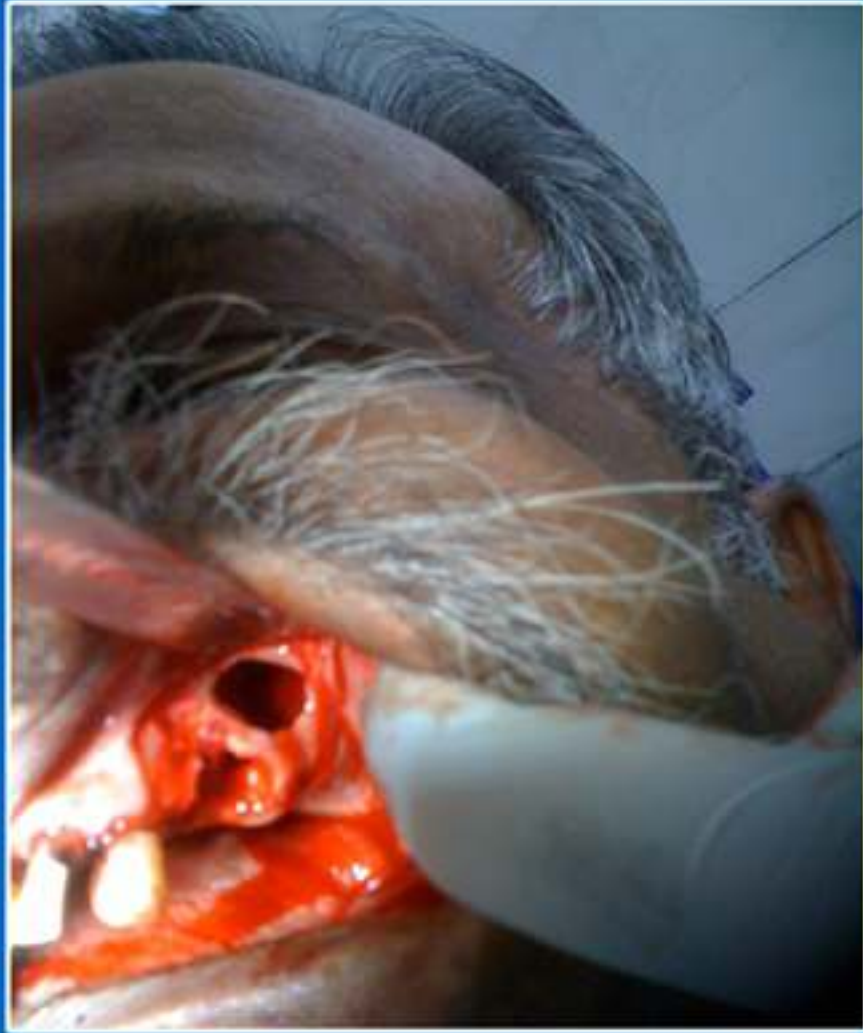

Postoperative:

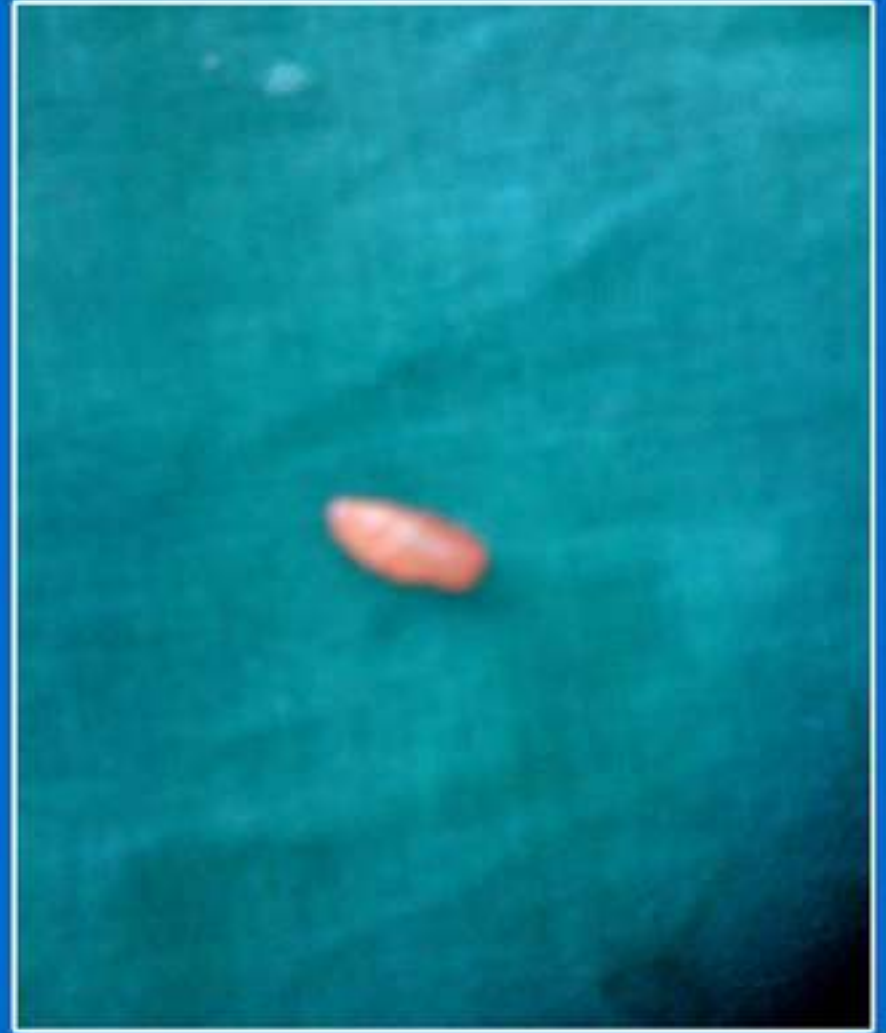

CALDWELL-LUC APPROACH

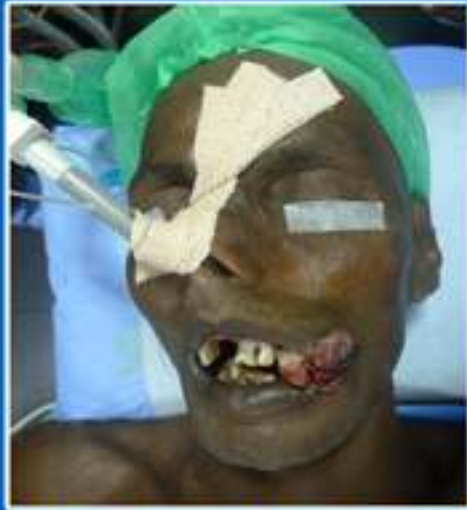Caldwell Luc Procedure



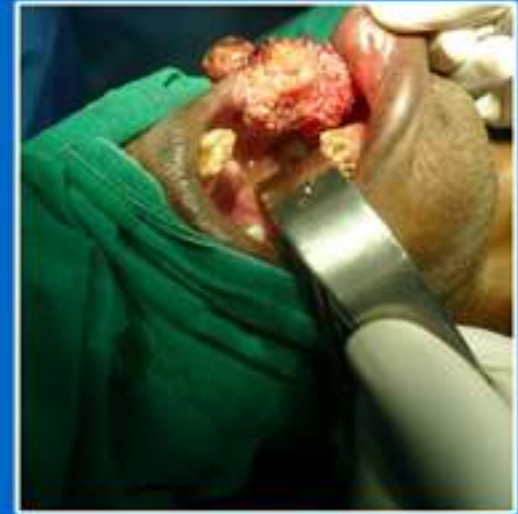Retrieved Root Of Premolar



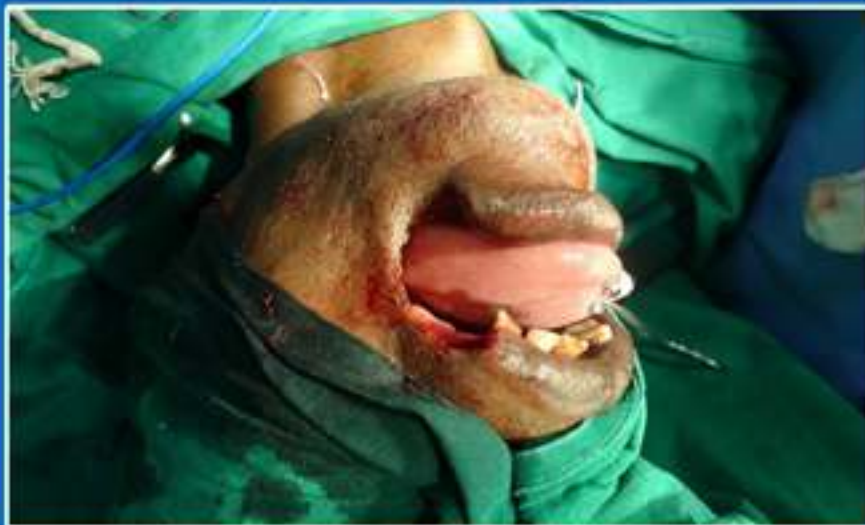CARCINOMA CHEEK



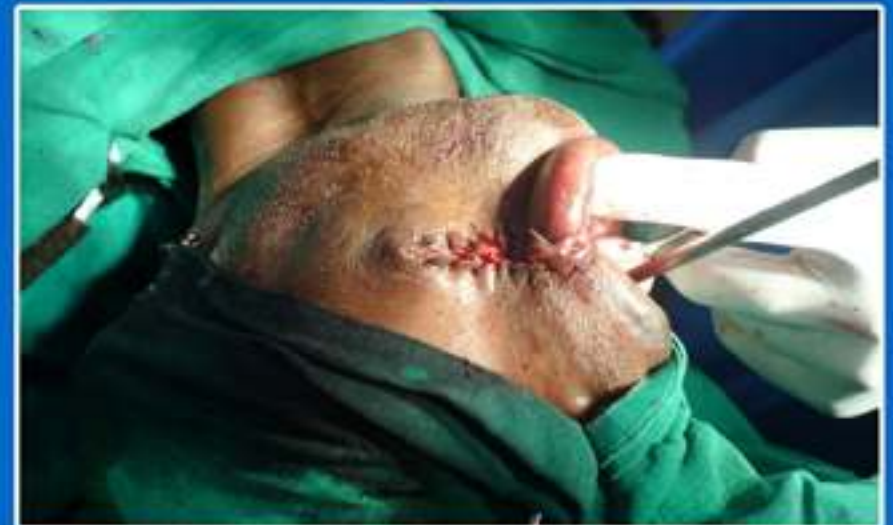Skin Involvement



Mucosal Involvement

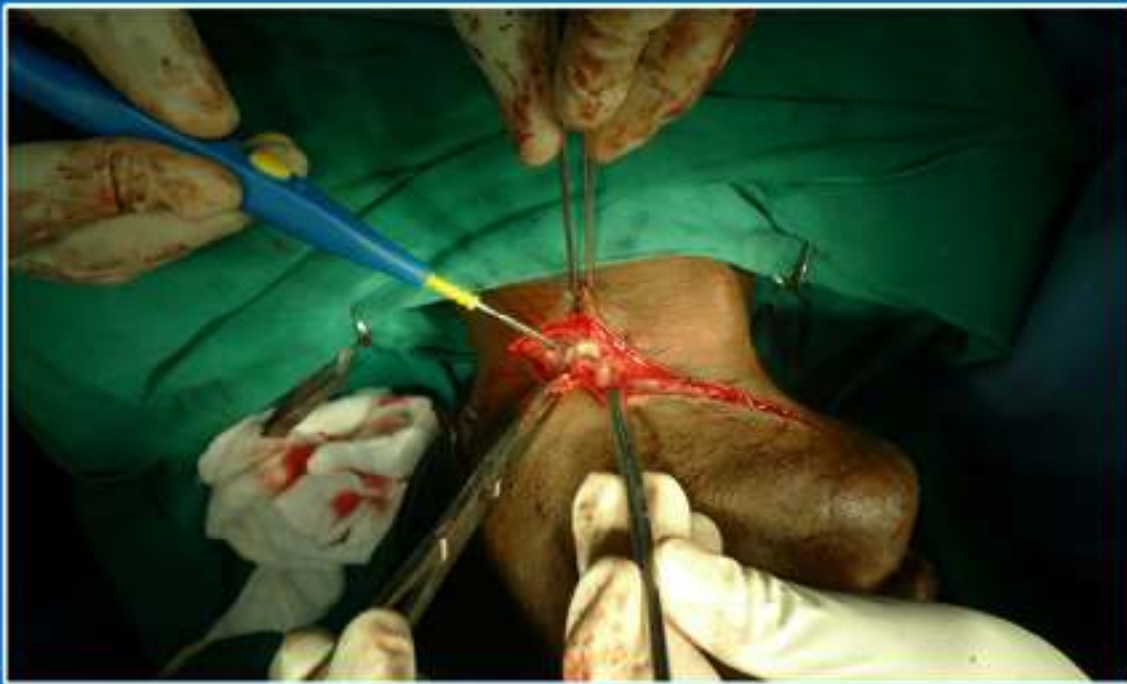

Excision

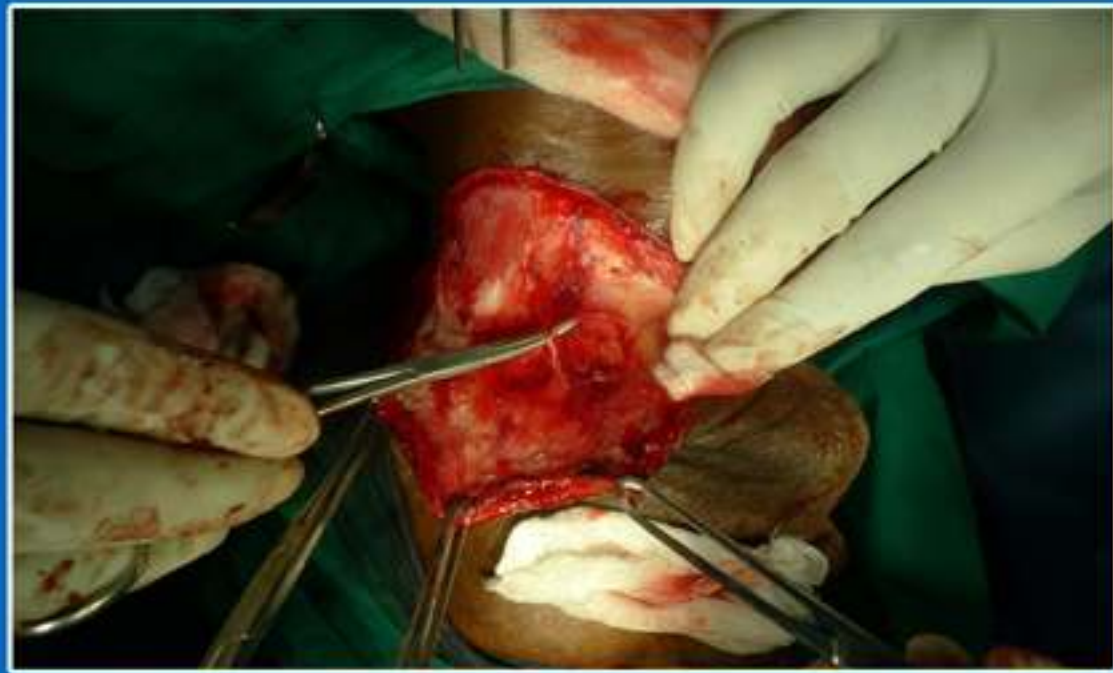

Wound Closure

CARCINOMA CHEEK

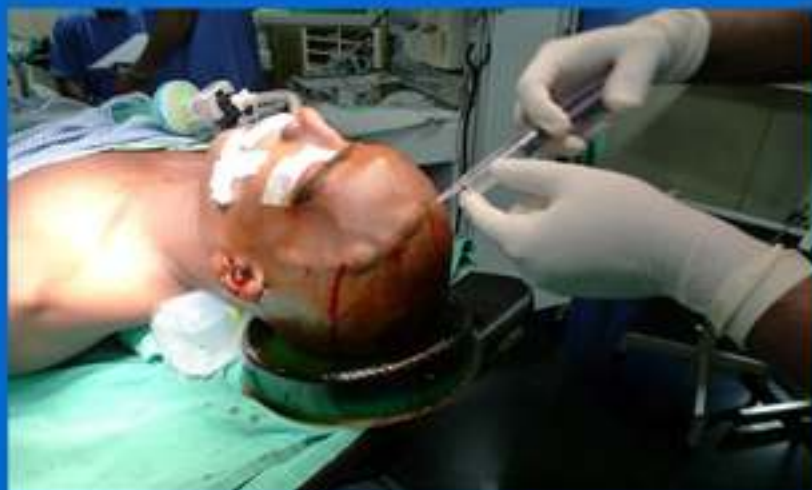

Neck Incision

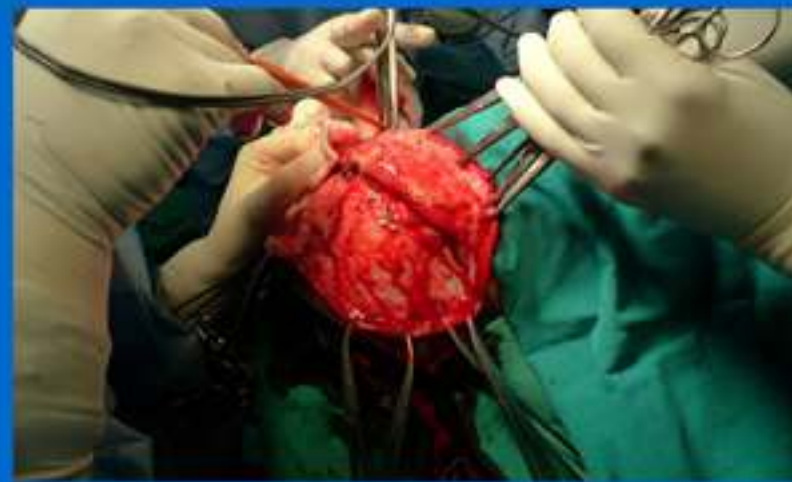


Supra Omohyoid Dissection

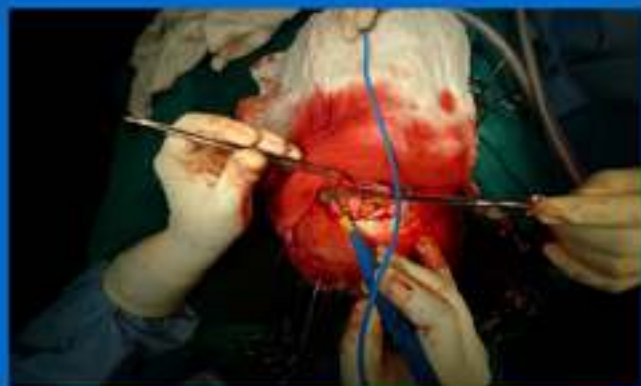FRONTAL BONE FRACTURE



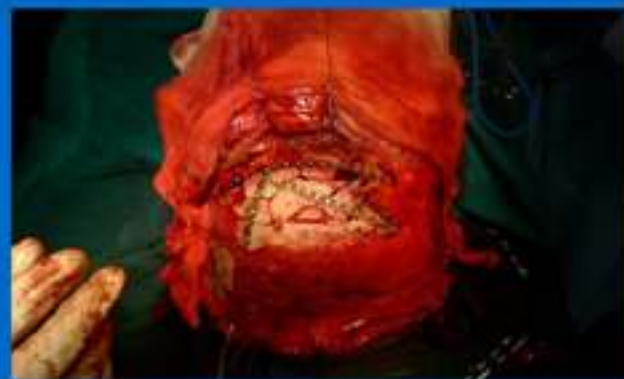LA administration



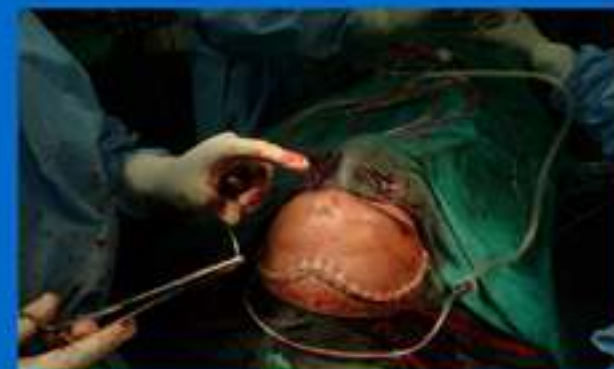Bicoronal Flap



Hemostasis



Frontal Bone Fixation



Wound Closure

GENIOPLASTY



PreOpeartive



PostOpeartive

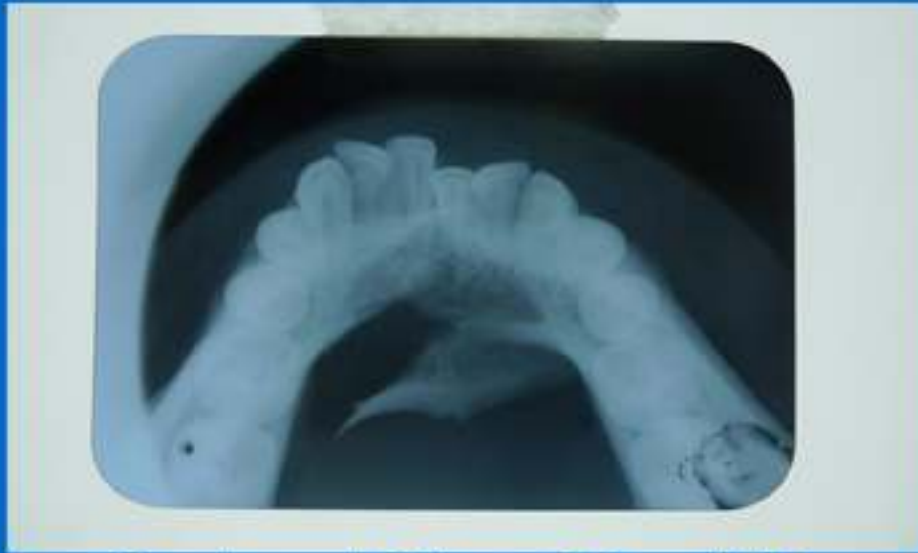

PreOpeartive

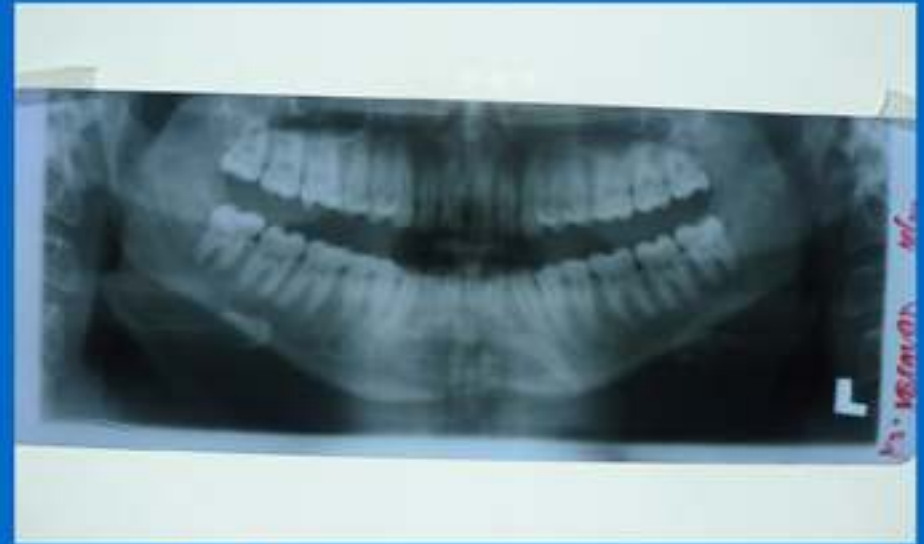

PostOpeartive

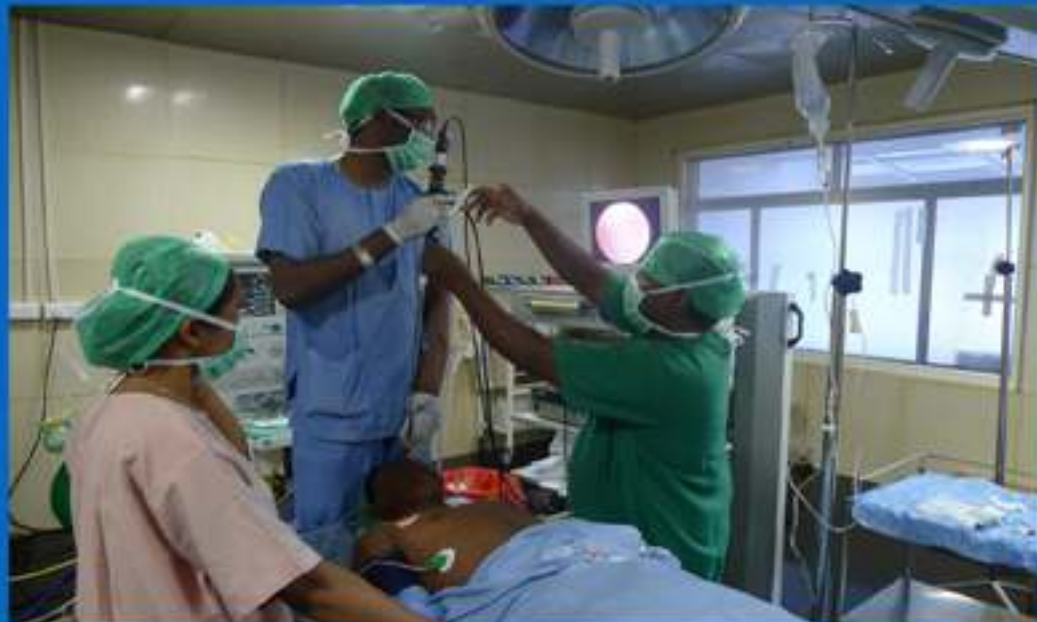MANDIBULAR SYMPHYSIS FRACTURE



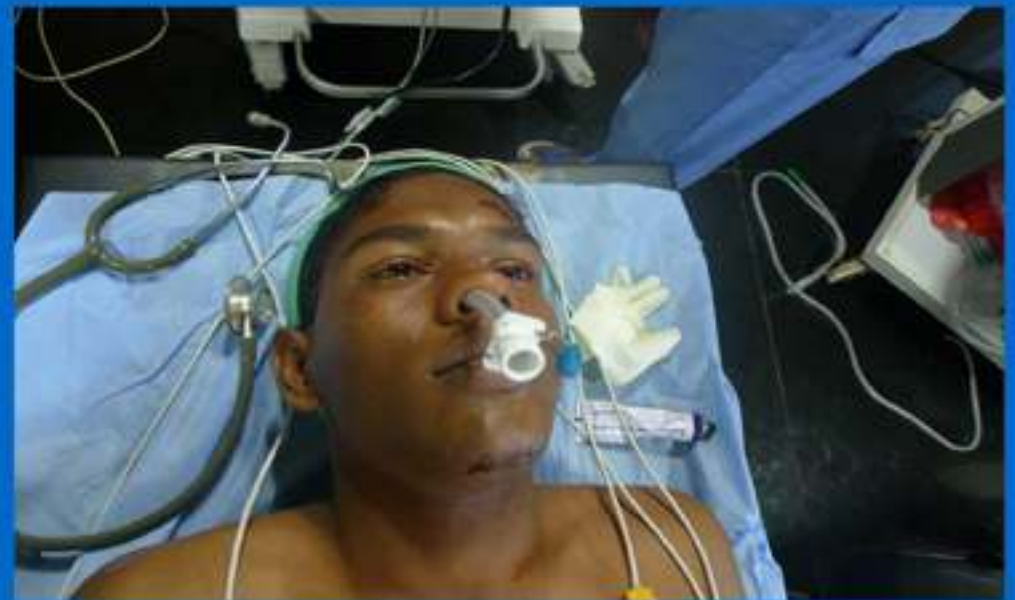Occlusal View Mandible



Orthopantomogram

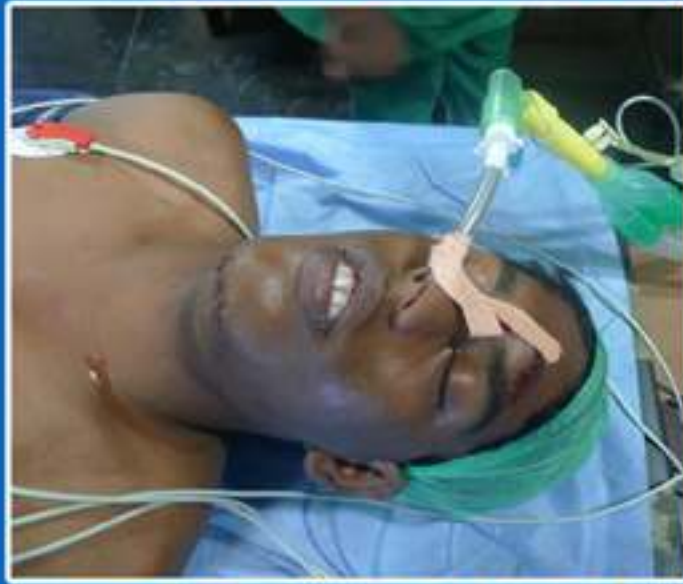

Awake Fiberoptic Intubation

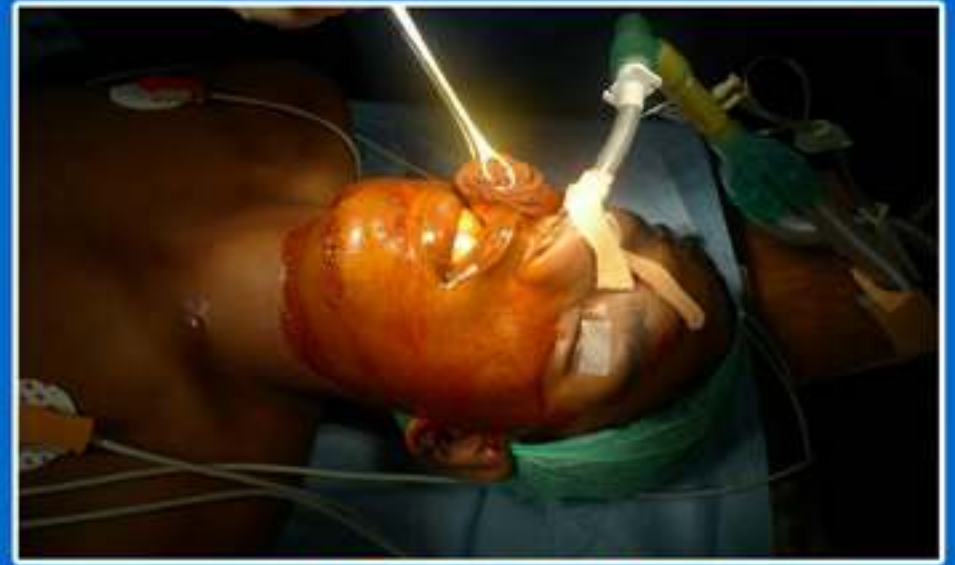

ET tube in place

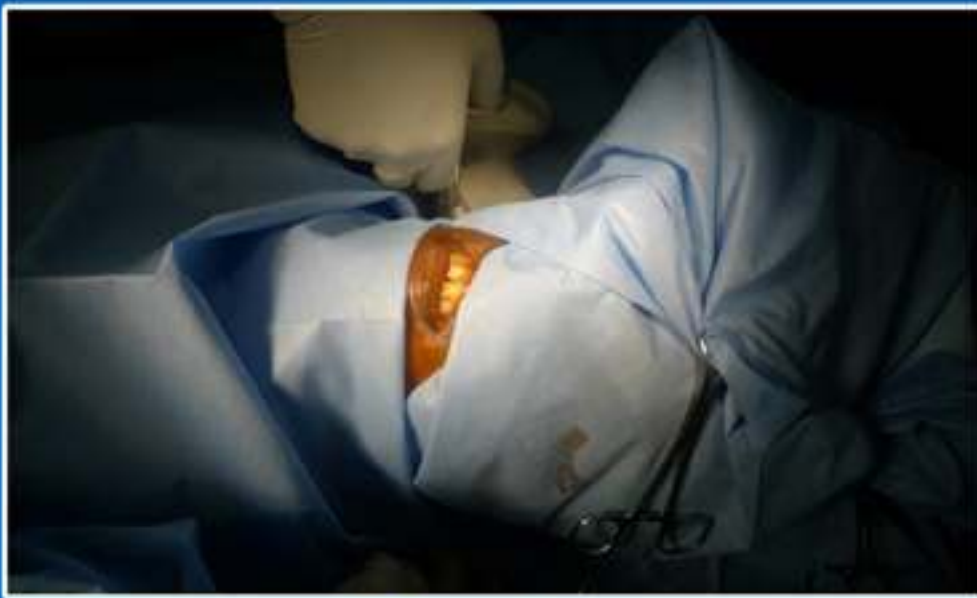MANDIBULAR SYMPHYSIS FRACTURE



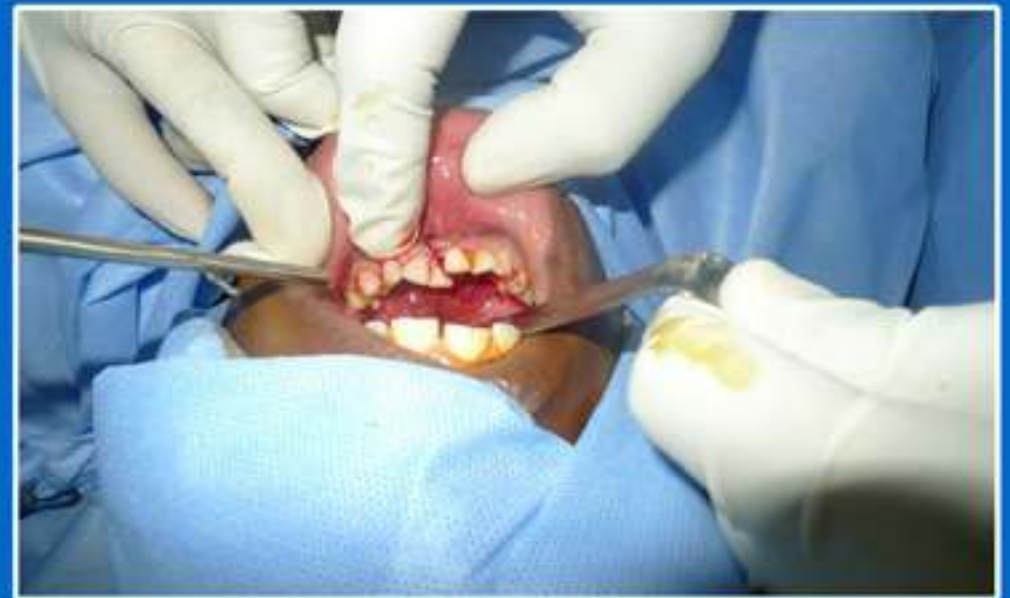GA Administered



Preparation

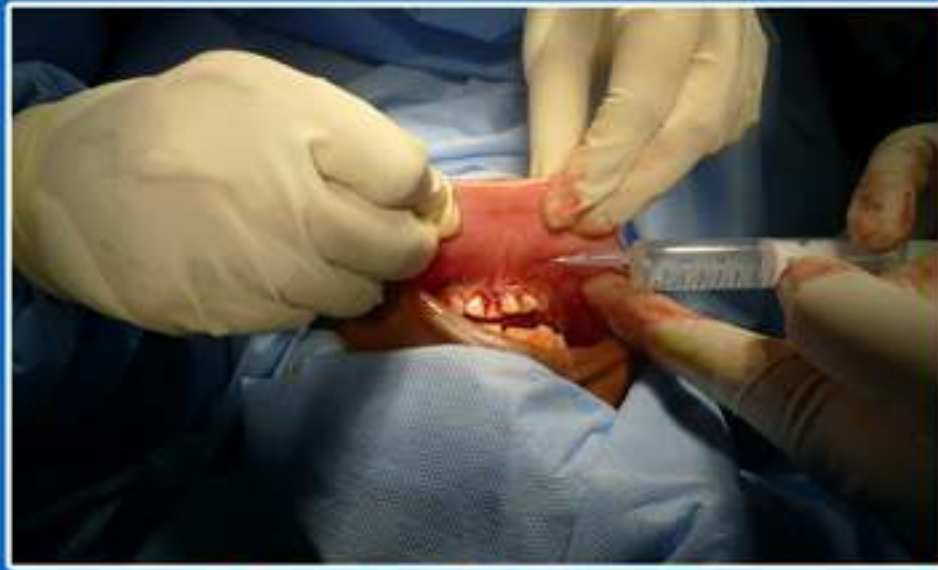

Draping

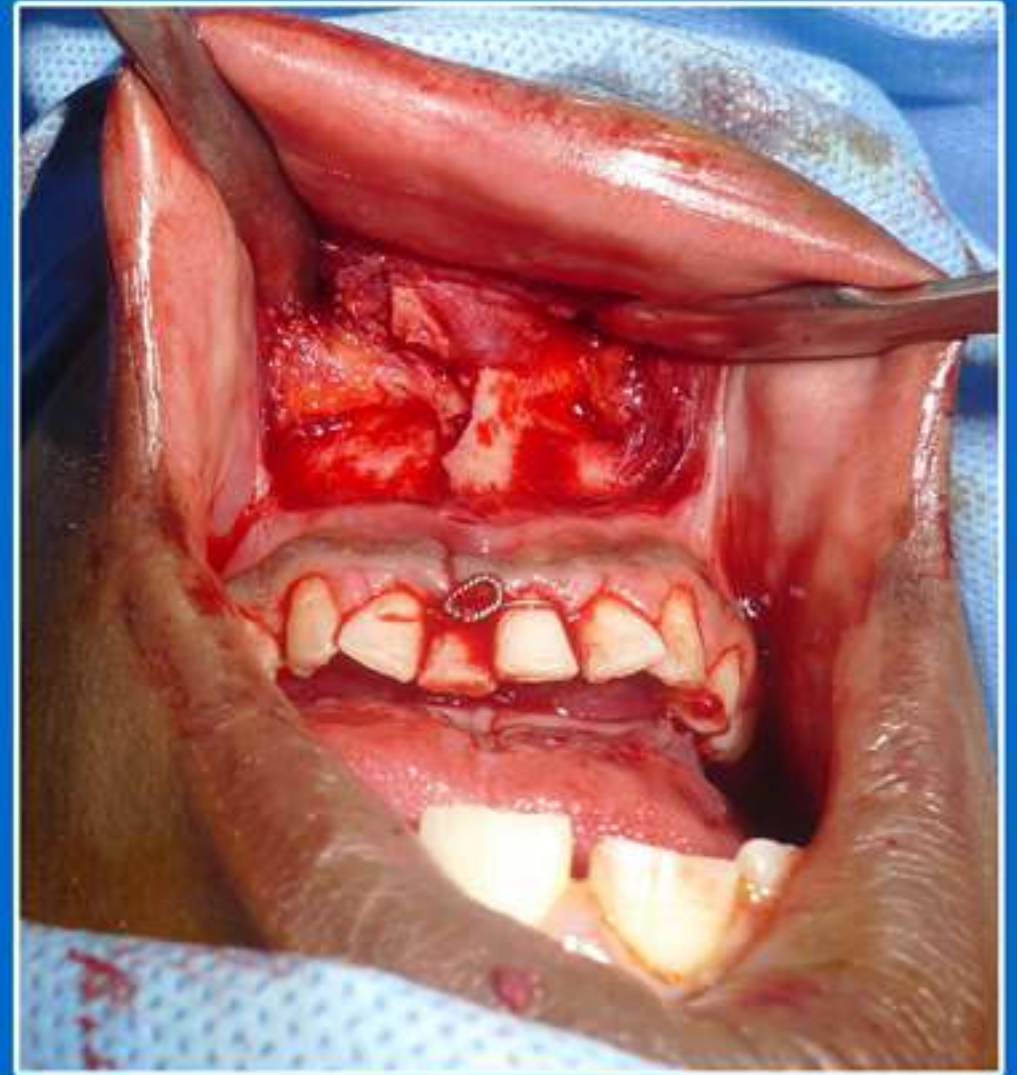

Symphysis Fracture

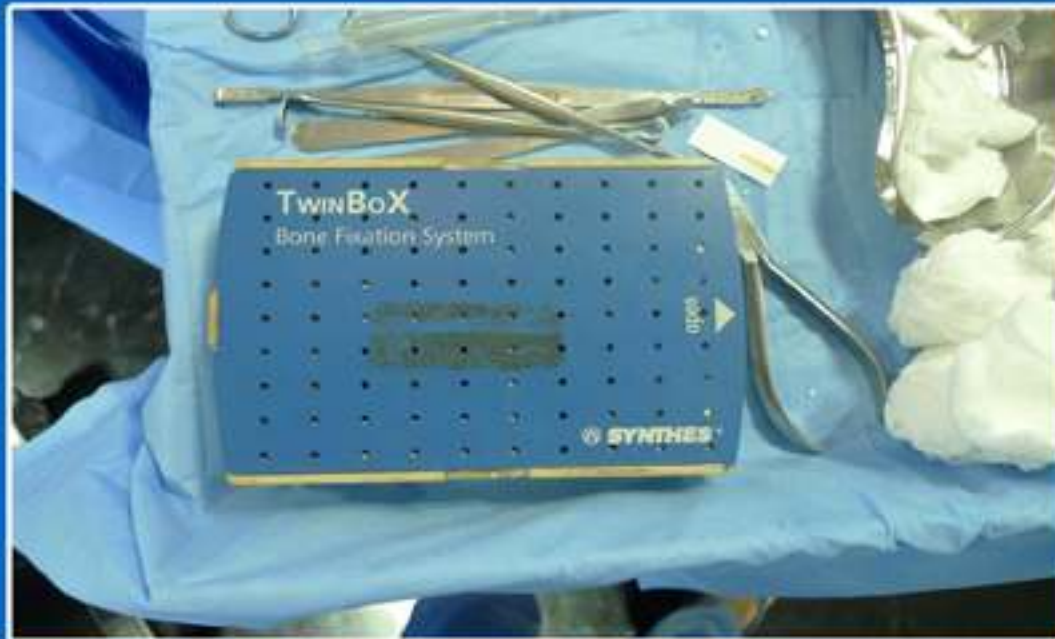
MANDIBULAR SYMPHYSIS FRACTURE



Tension Wiring

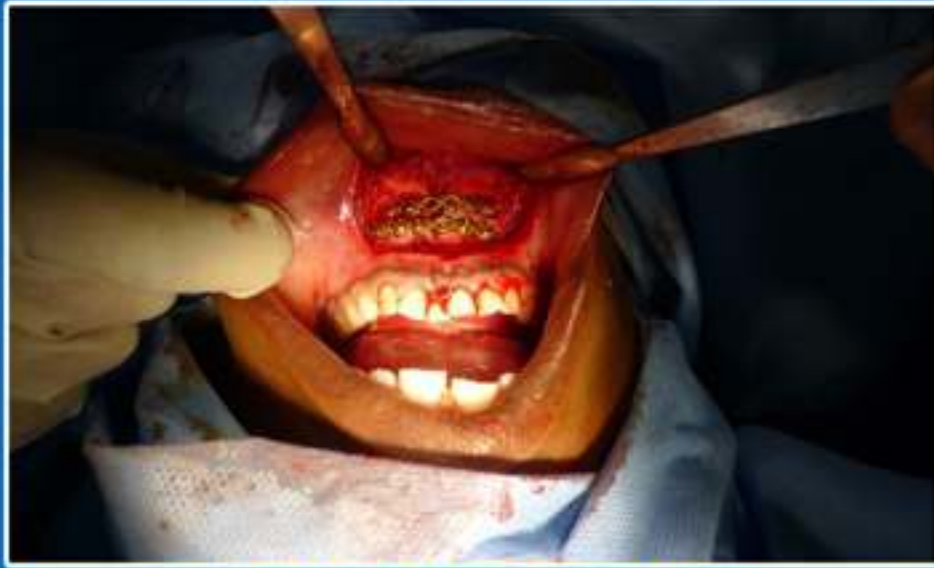

Fracture Exposure

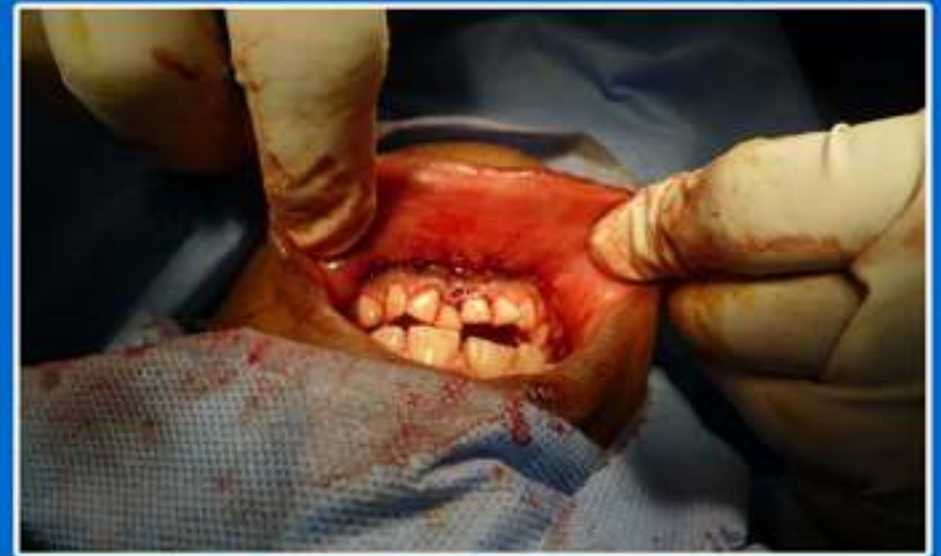

Miniplates & Screws

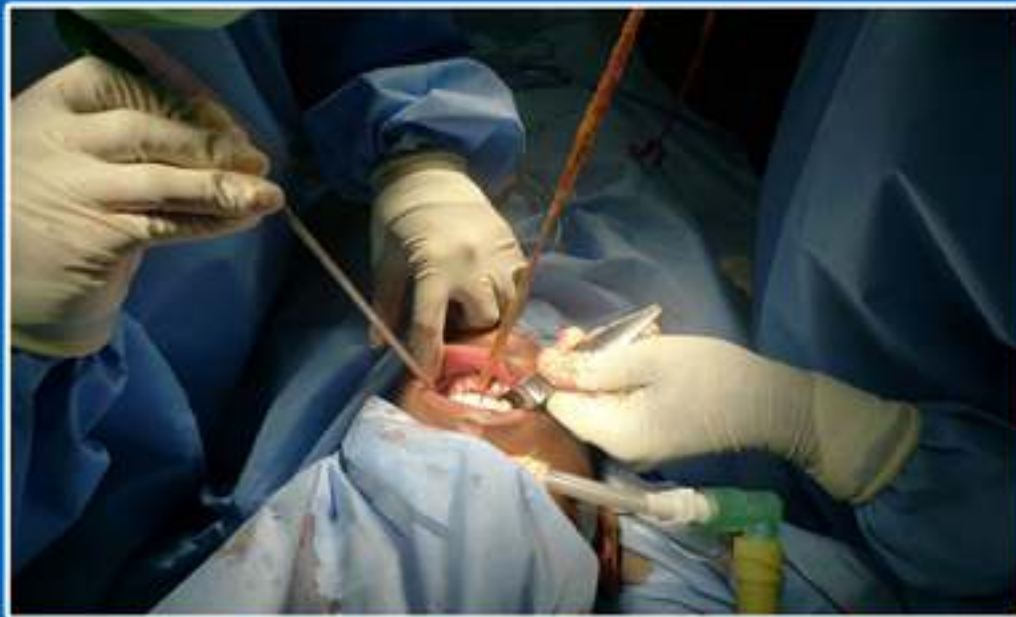MANDIBULAR SYMPHYSIS FRACTURE



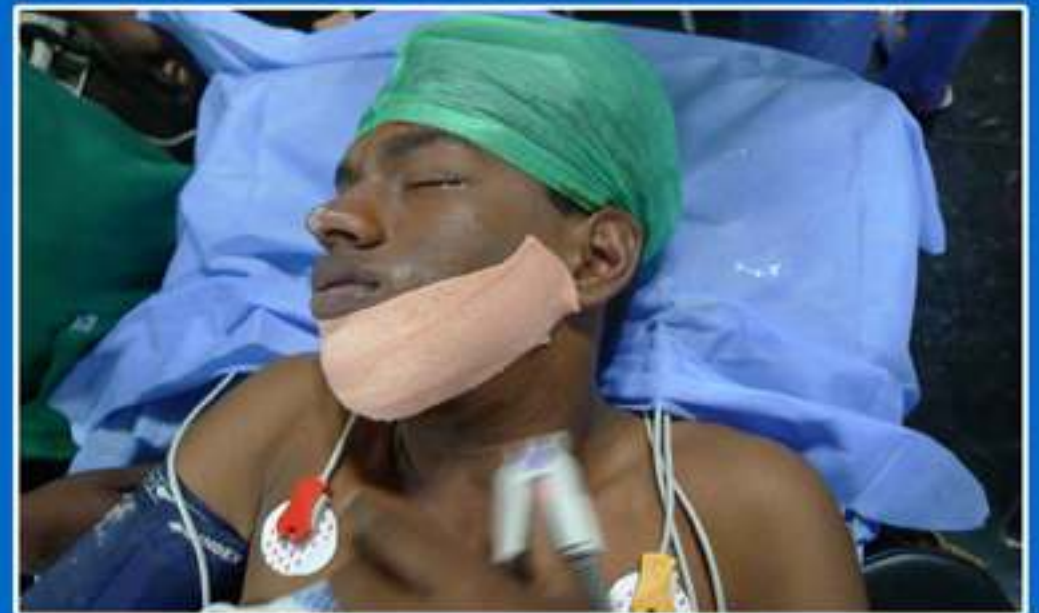Miniplate Fixation



Wound Closure

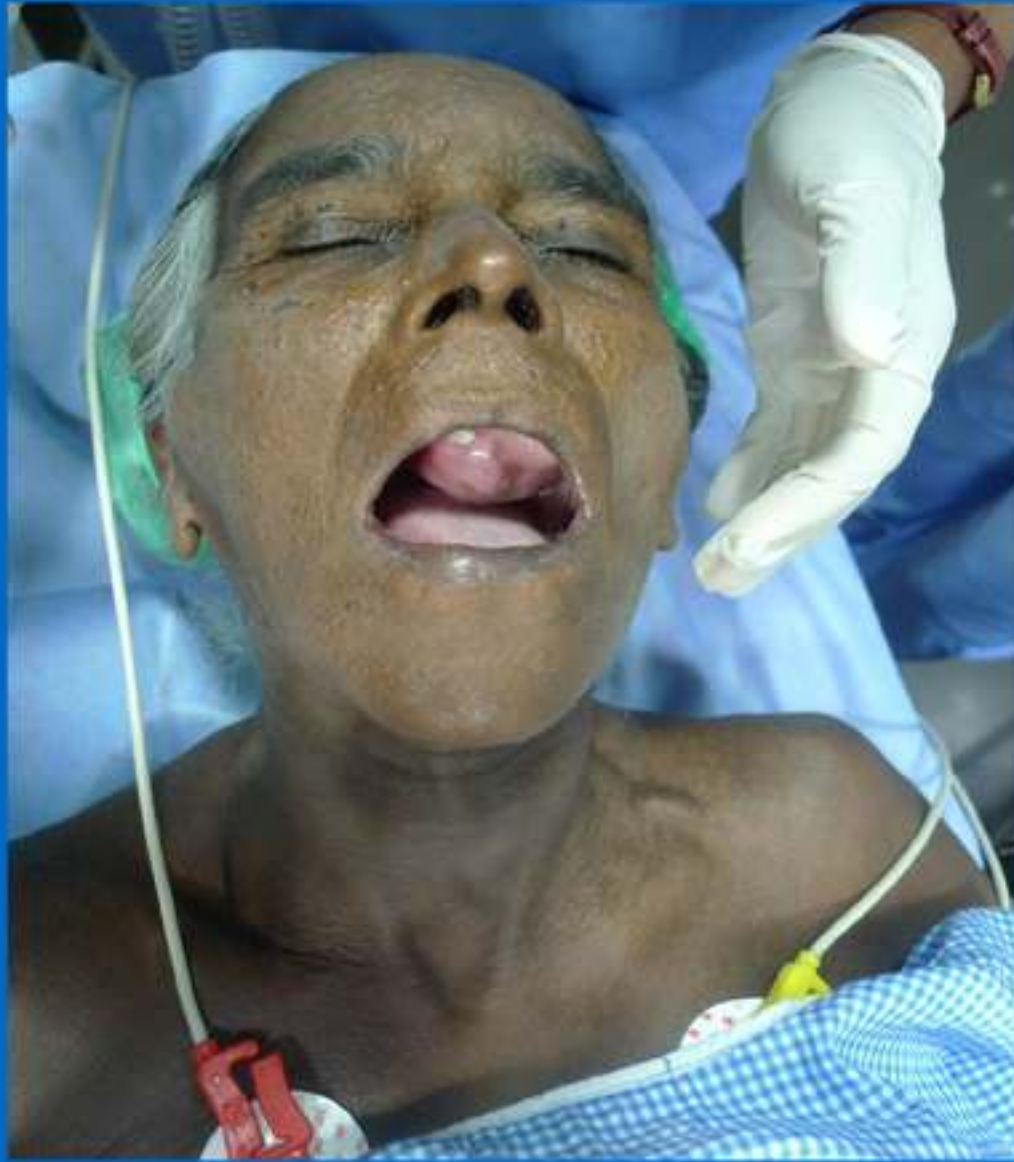

Throat Pack Removal

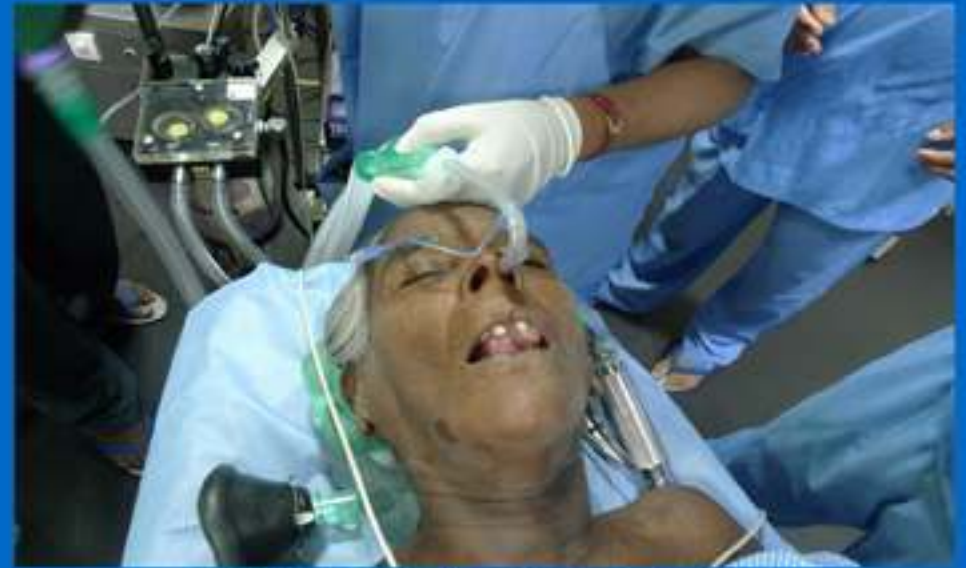

Adhesive Bandage

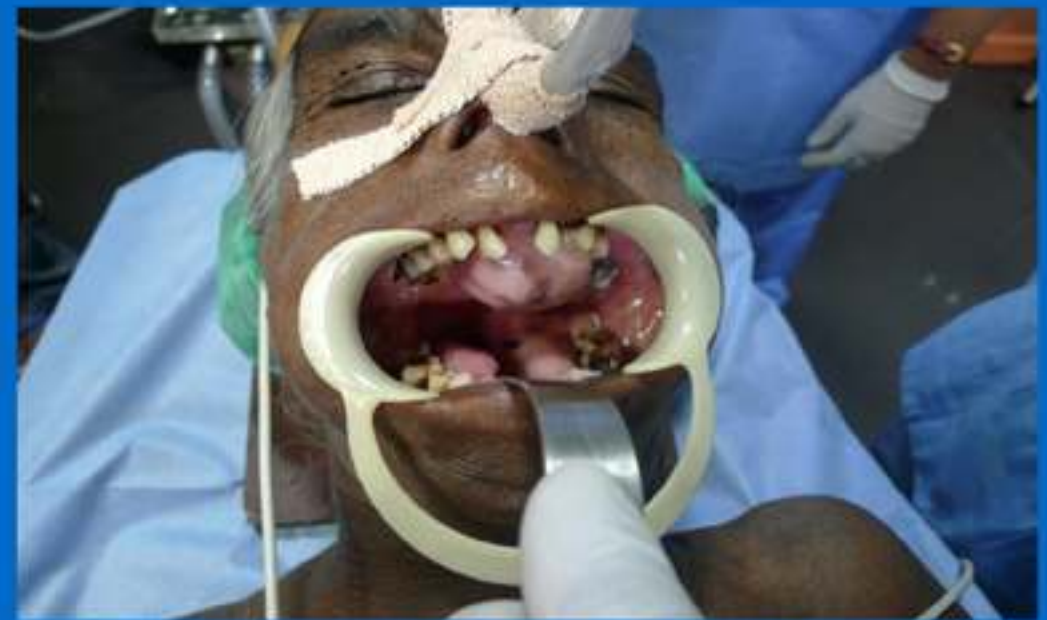PLEOMORPHIC ADENOMA



Pleomorphic Adenoma

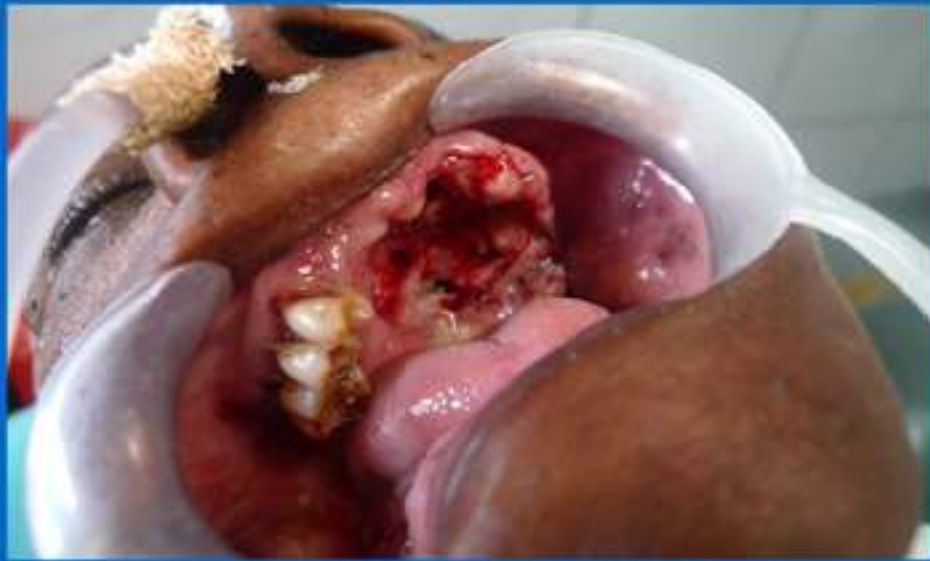

ET TUBE IN PLACE

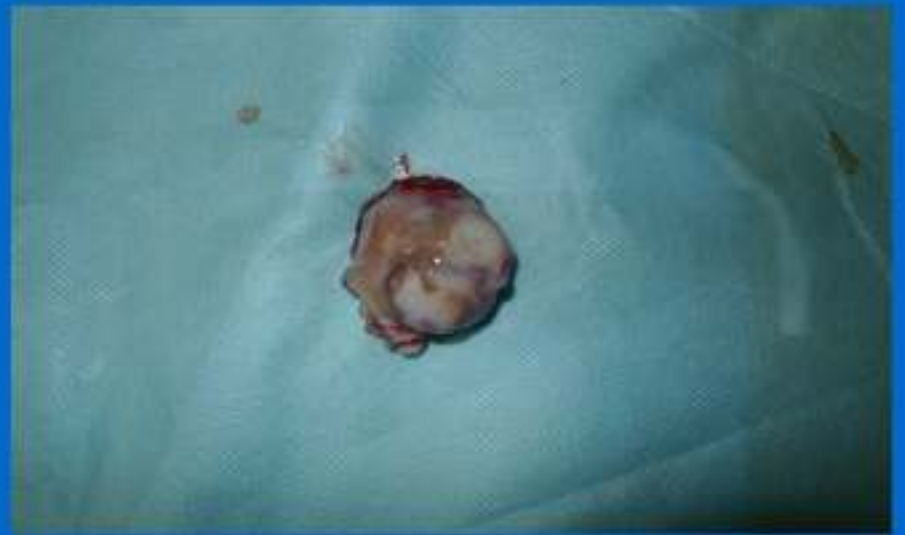

Extent Of The Lesion

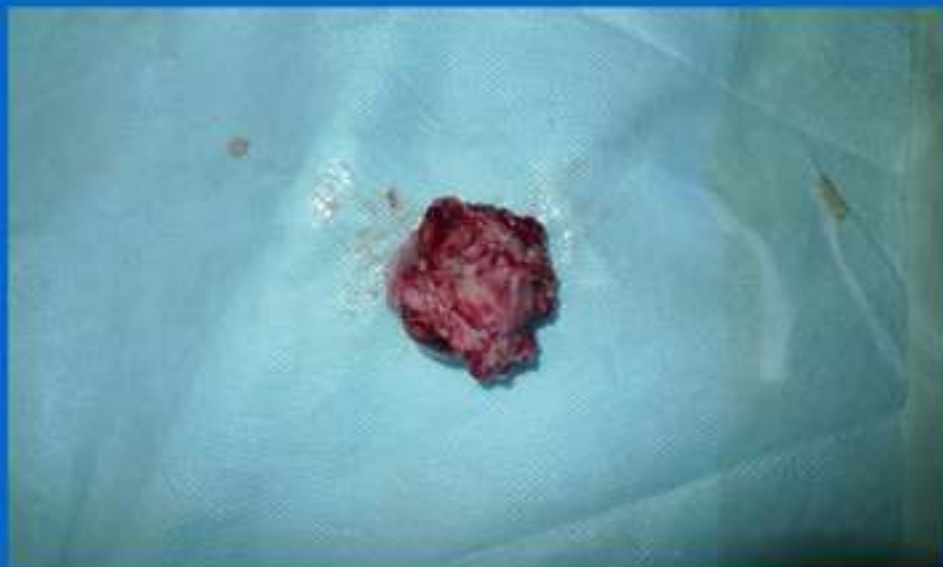PLEOMORPHIC ADENOMA



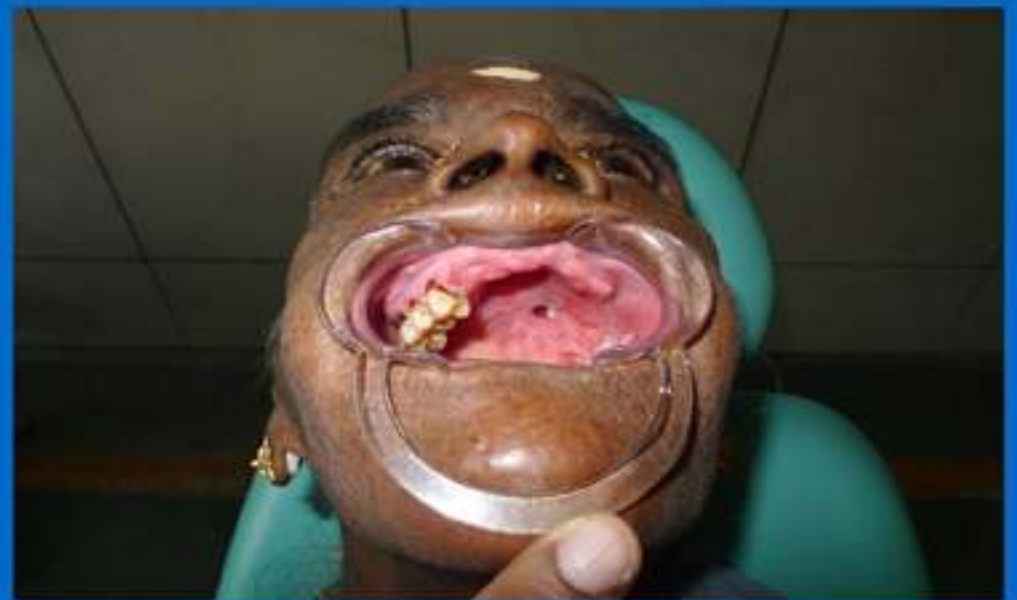Removal



Excised Lesion

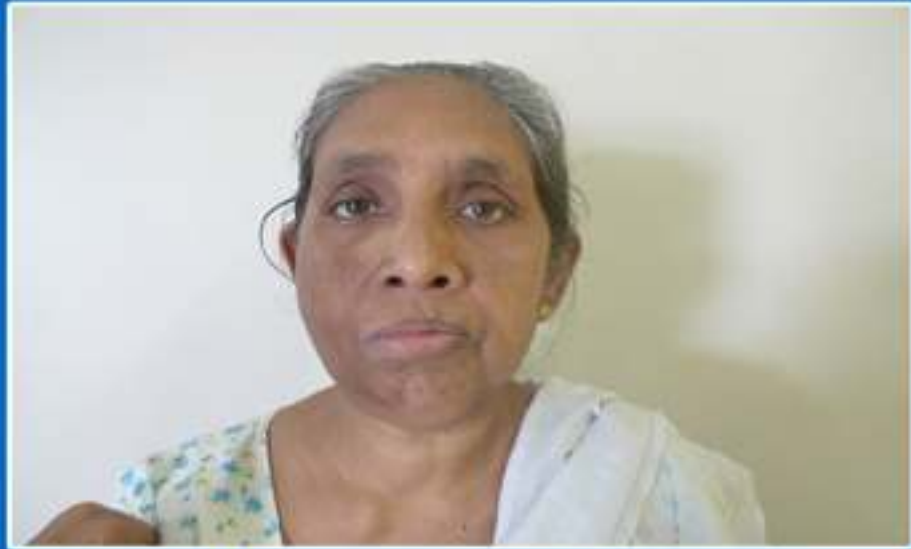

Excised Lesion

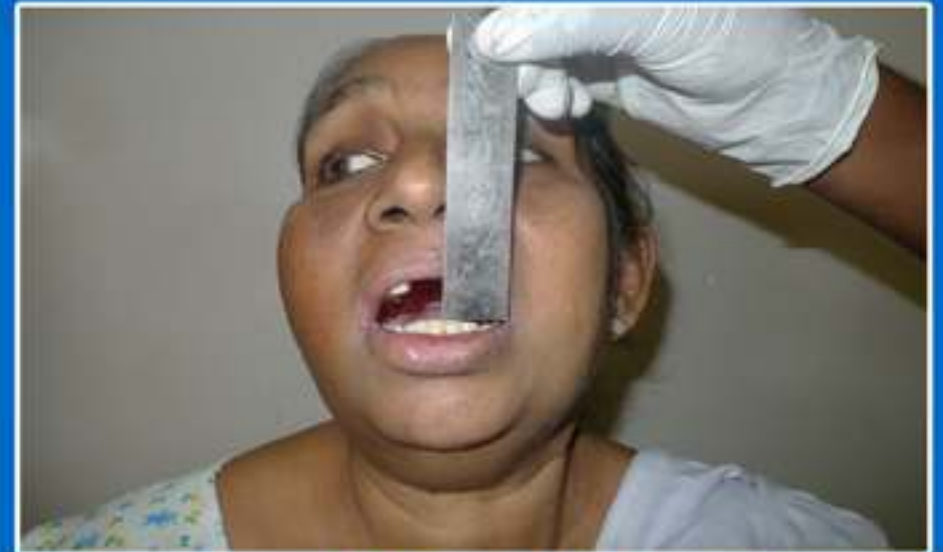

Post Operative

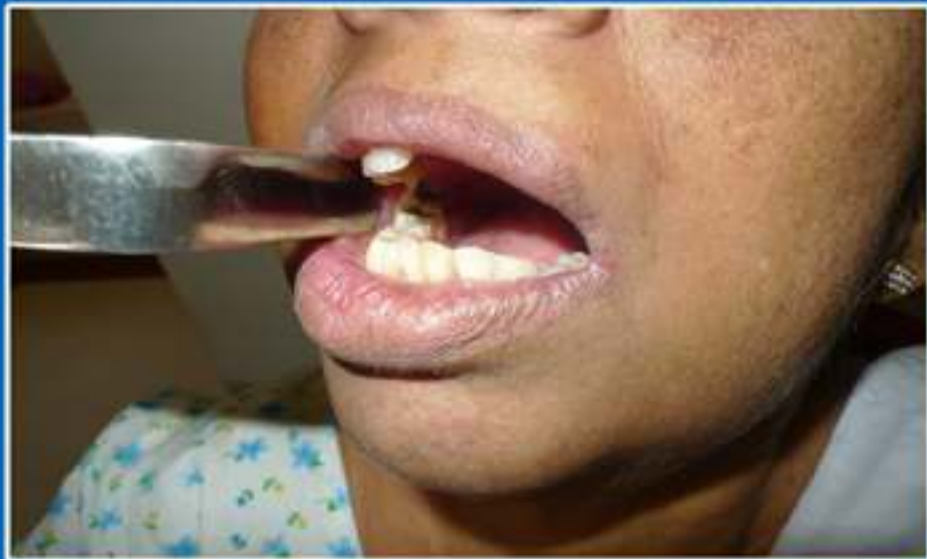POST RADIATION FIBROSIS CA CHEEK



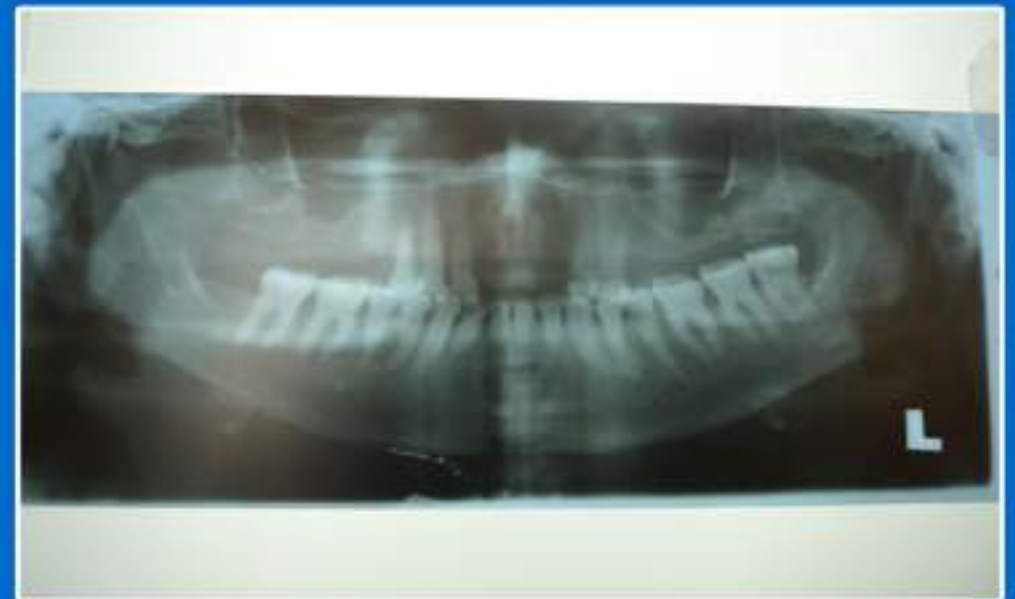Pre-Operative



Reduced Mouth Opening

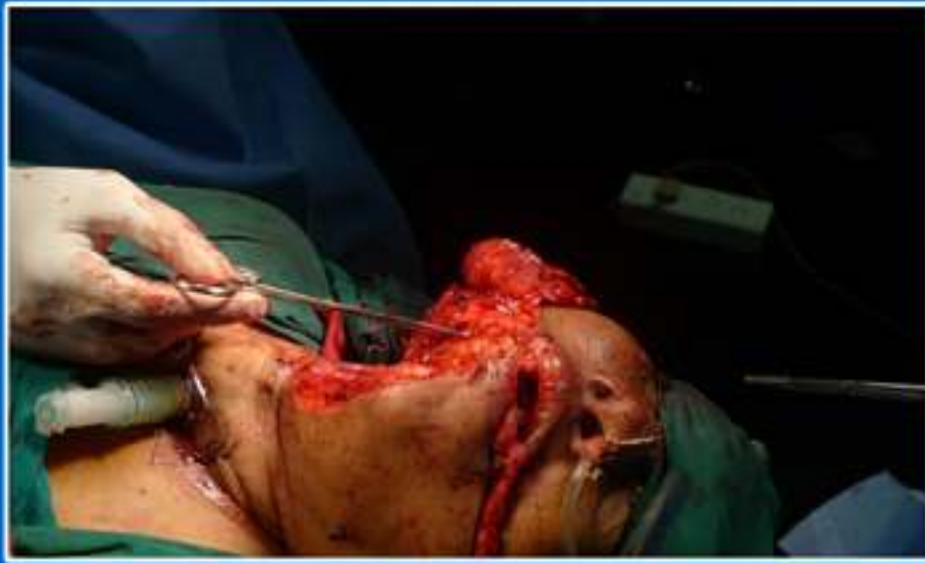

Lesion

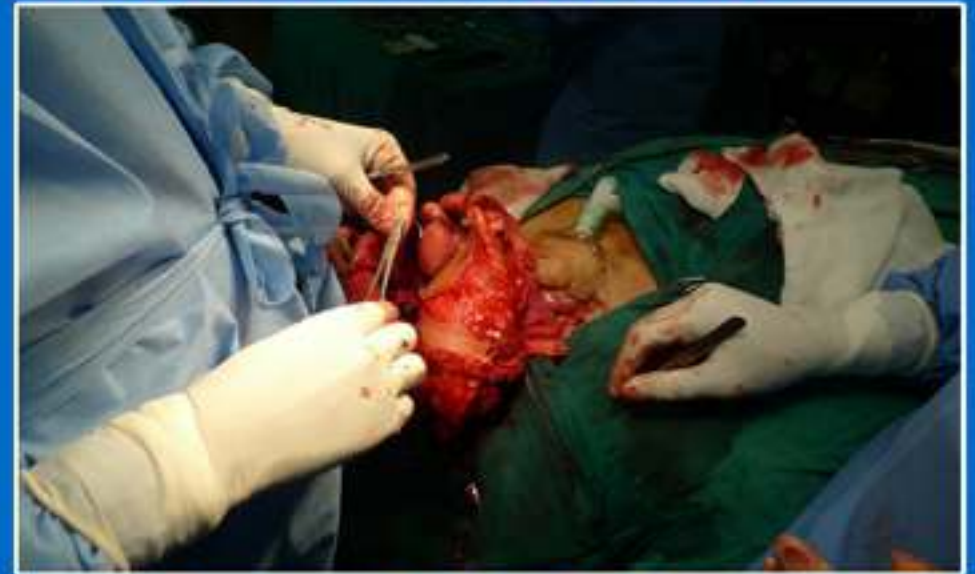

Orthopantomogram

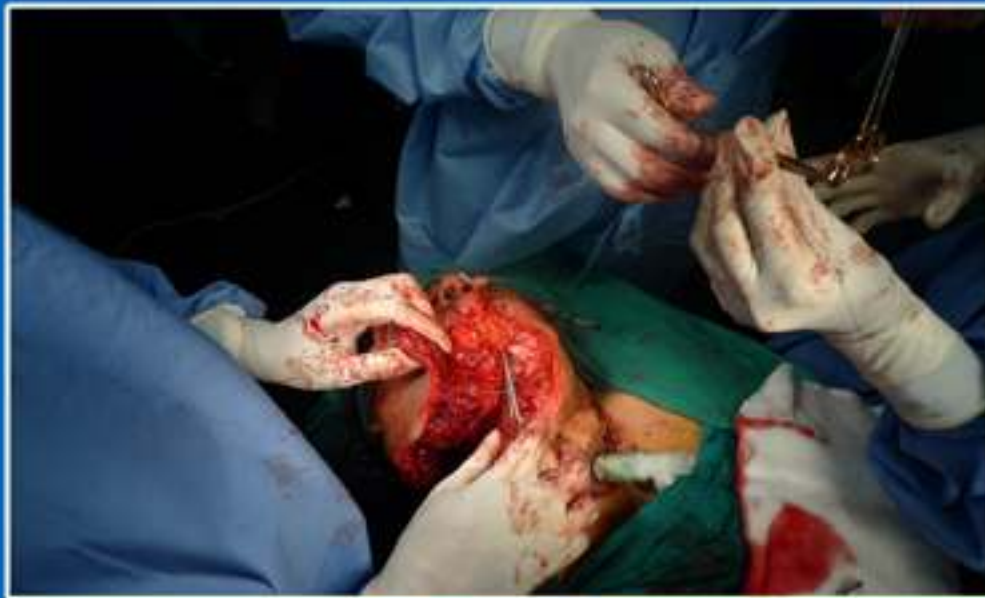POST RADIATION FIBROSIS CA CHEEK



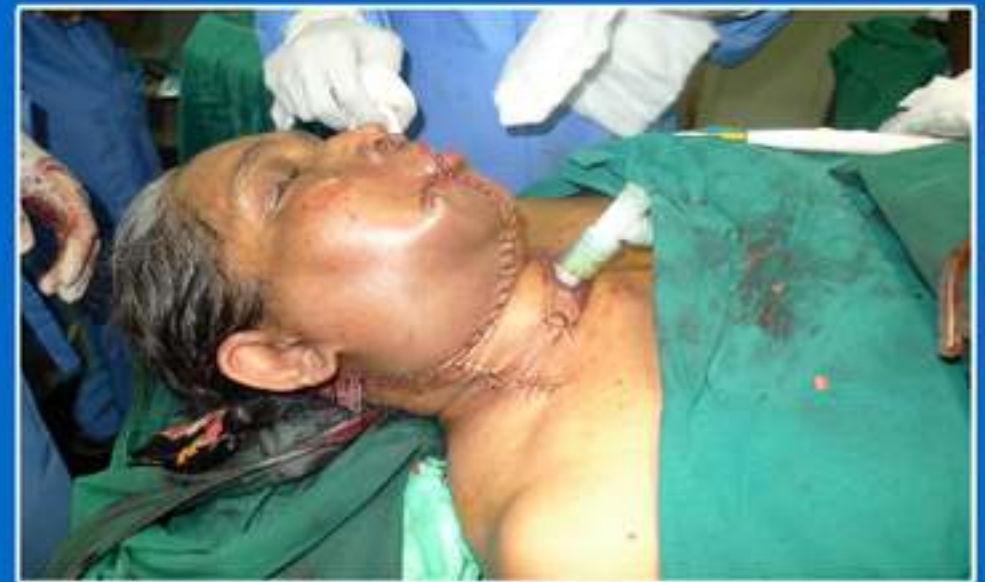Composite Resection



Anterolateral Thigh Flap Transfer

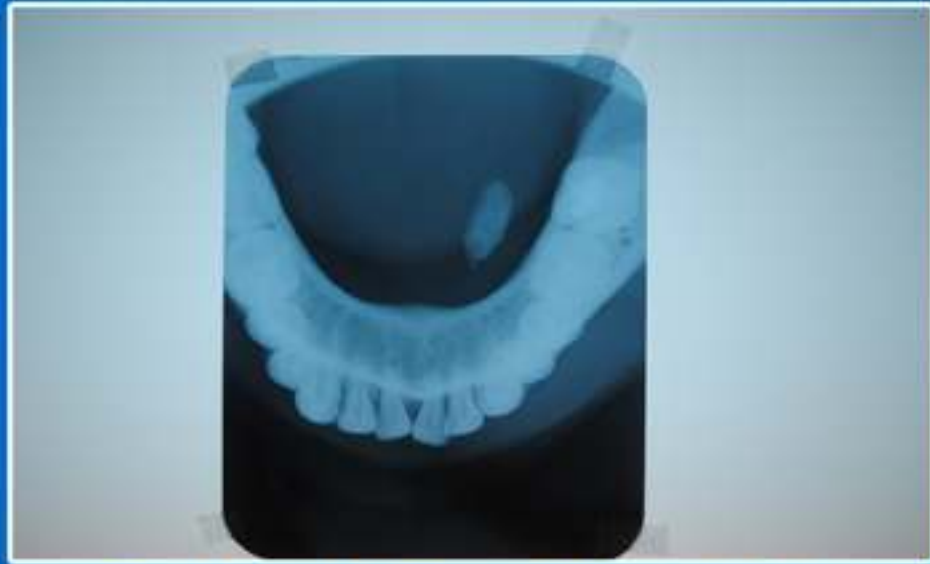

Suturing

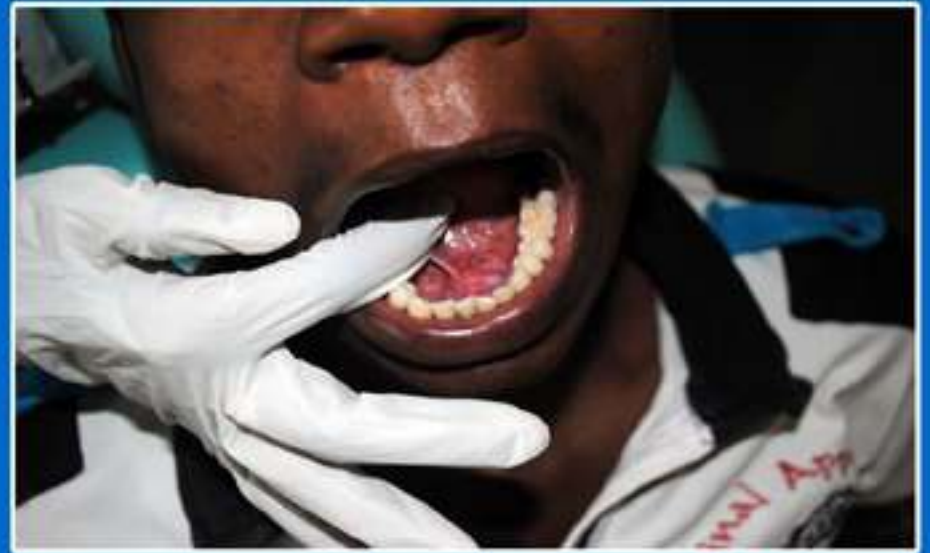

Wound Closure

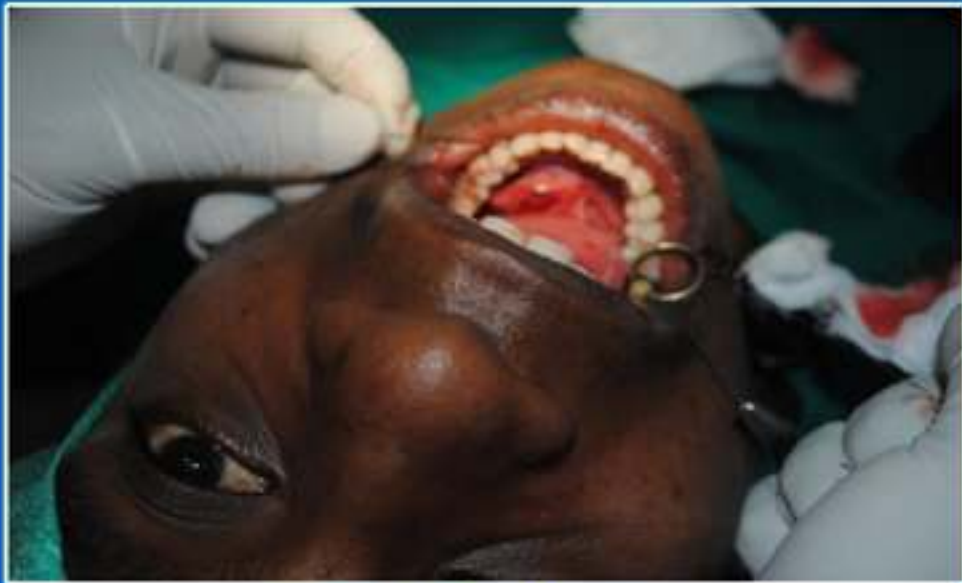SIALOLITH REMOVAL



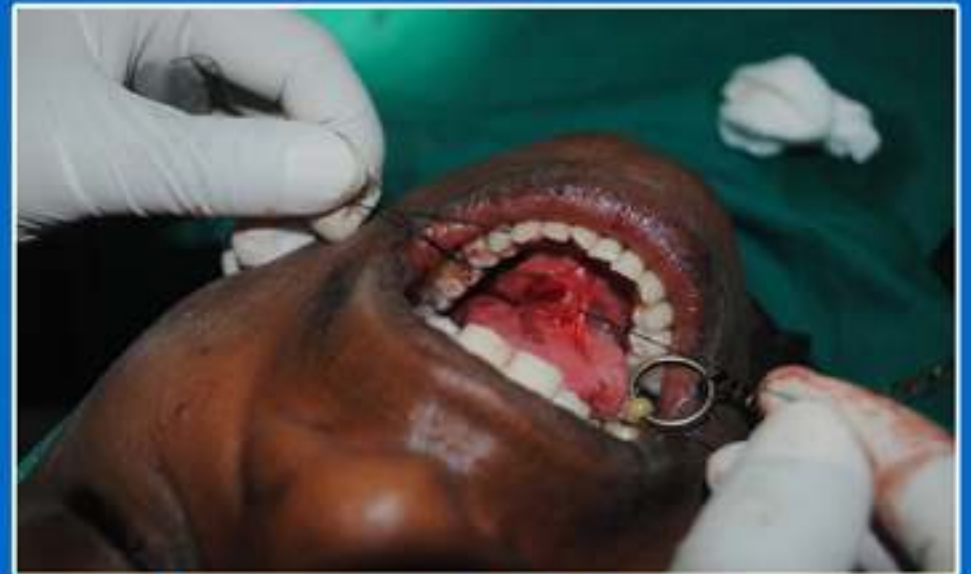Occlusal View Mandible



Intraoral View



Stay Suture

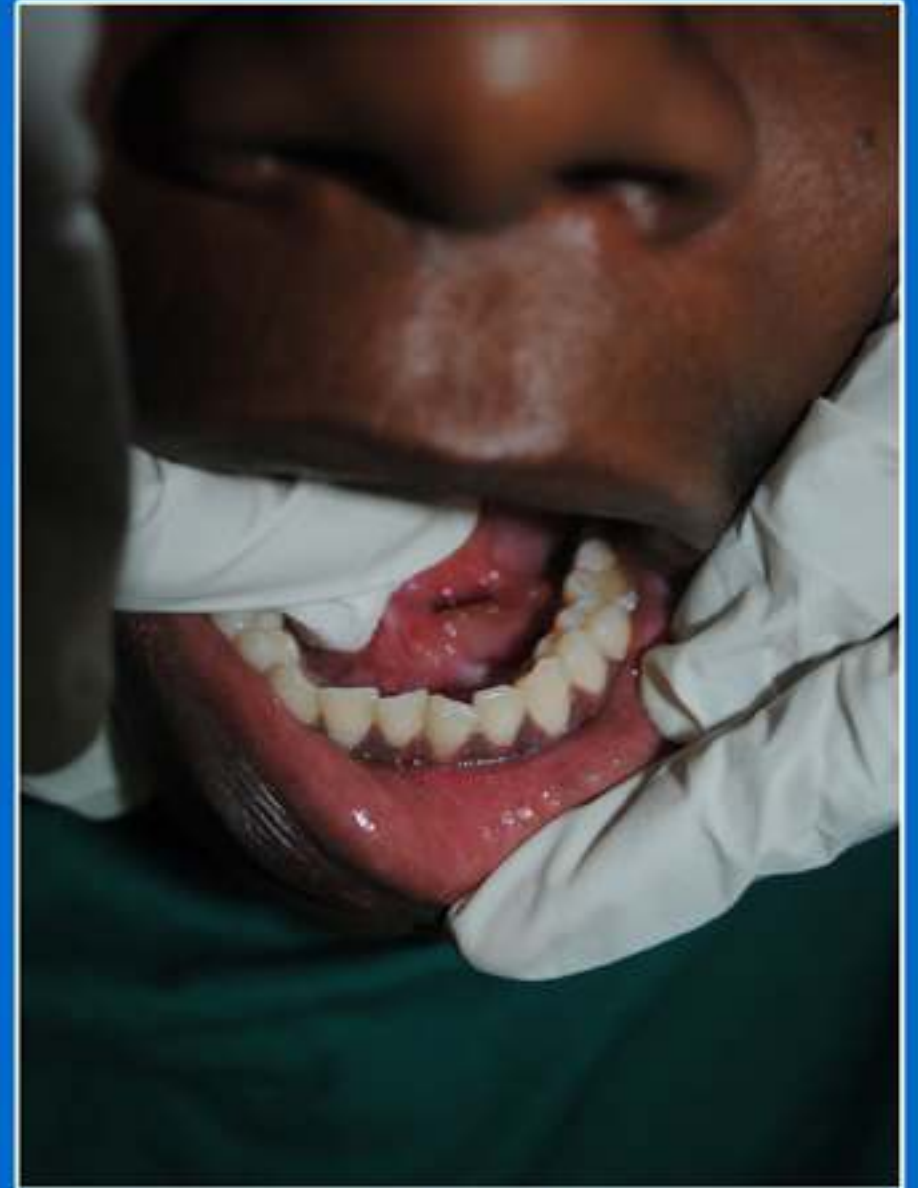

Removal Of The Stone

SIALOLITH REMOVAL

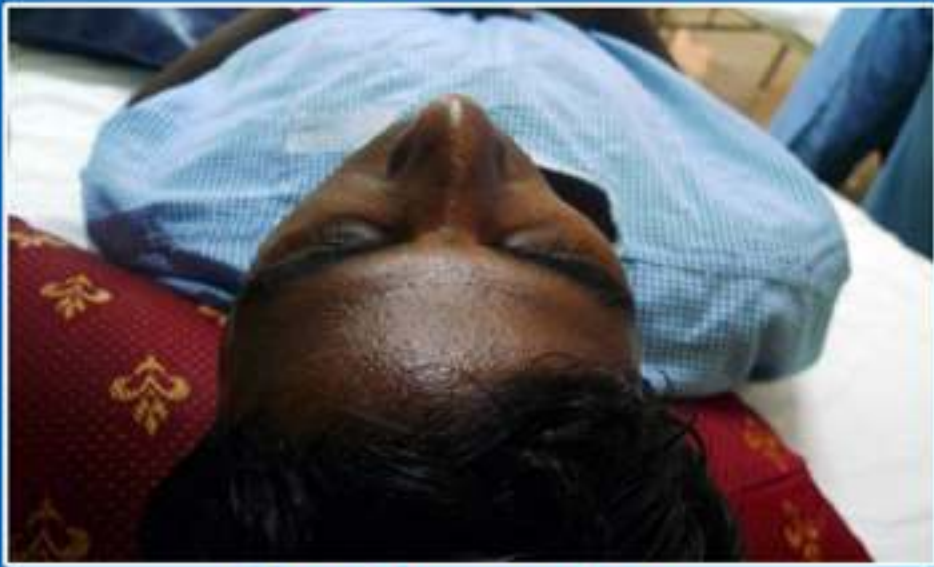

Removed Stone

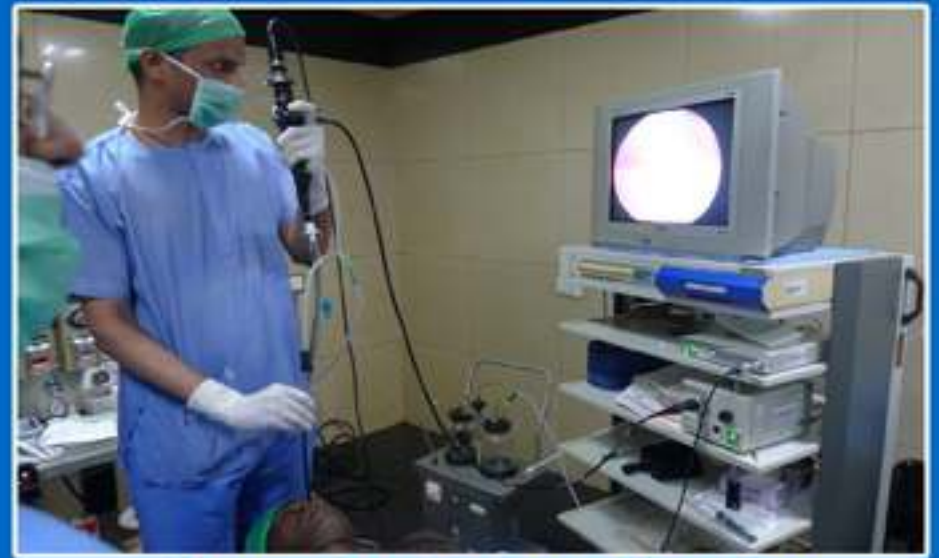

Sutured Duct Lining

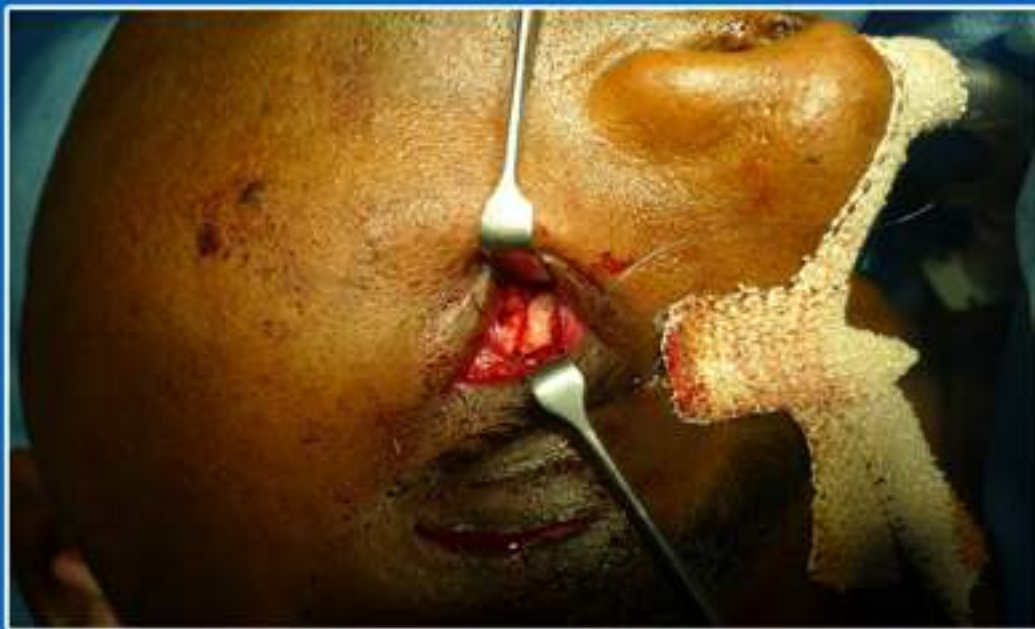ZYGOMATIC COMPLEX FRACTURE



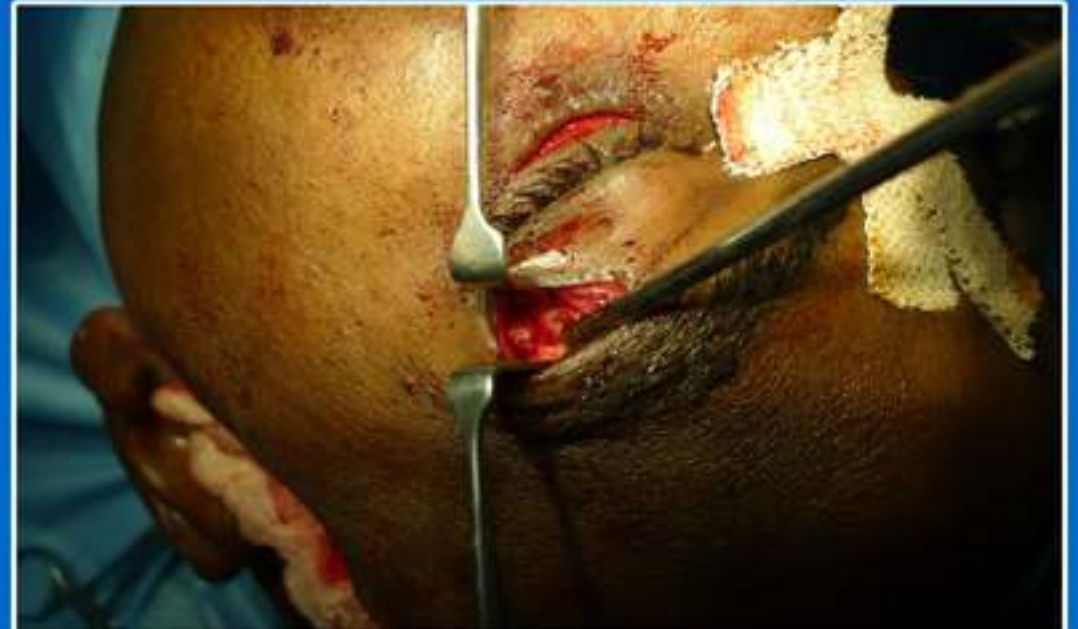Pre Operative



Fiber Optic Intubation

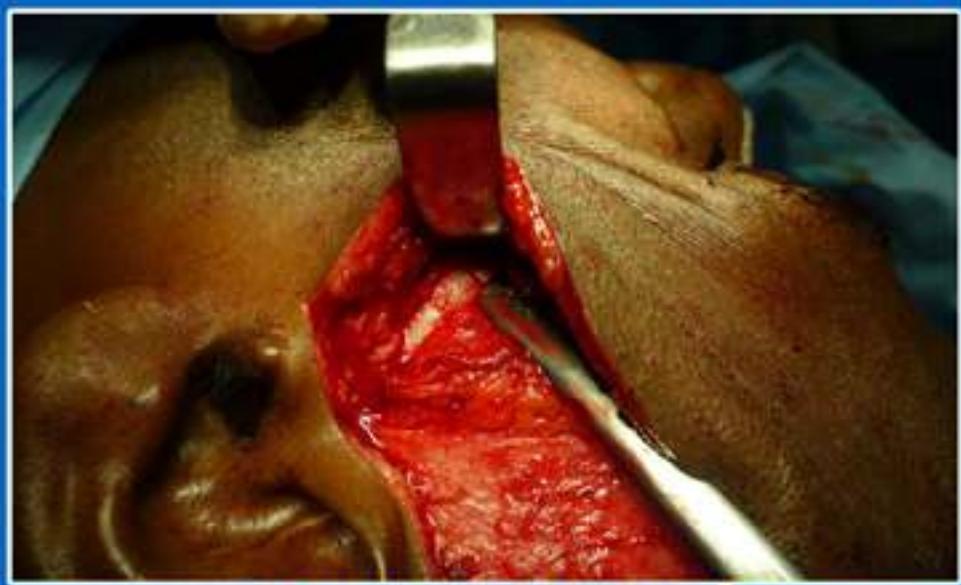

Infraorbital Rim

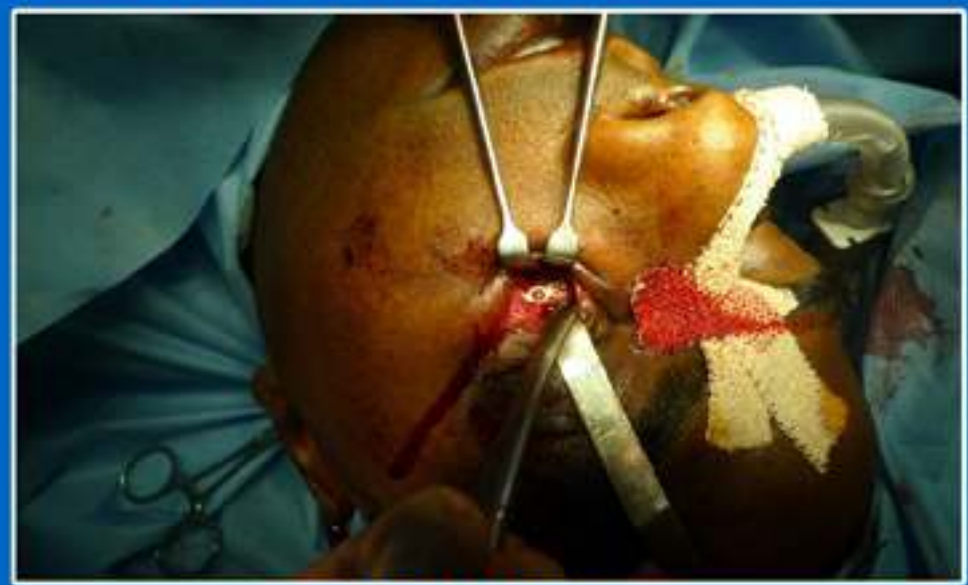

FZ Suture

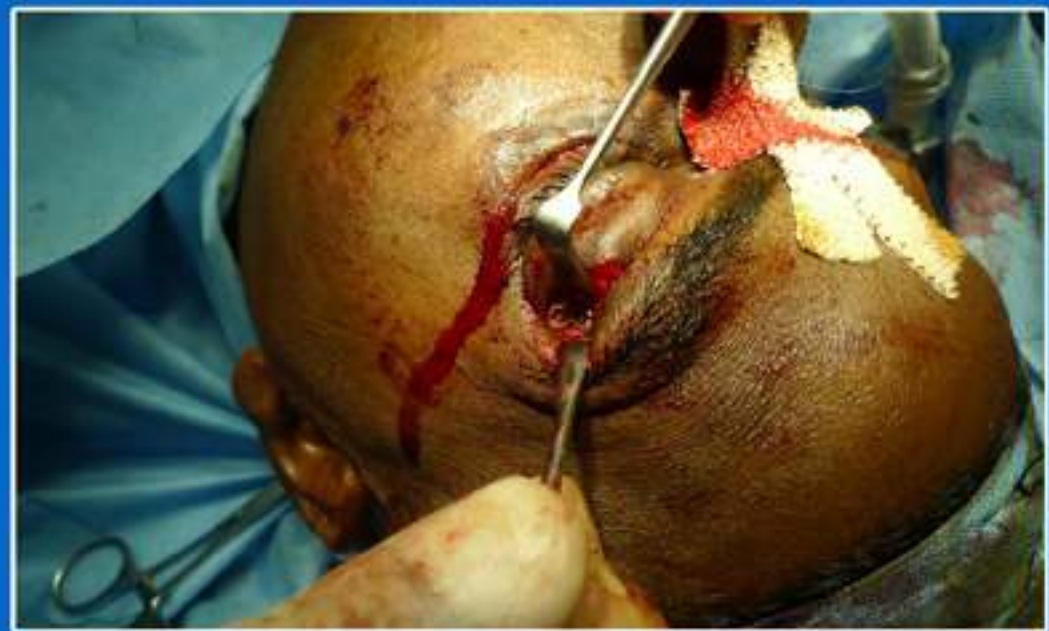ZYGOMATIC COMPLEX FRACTURE



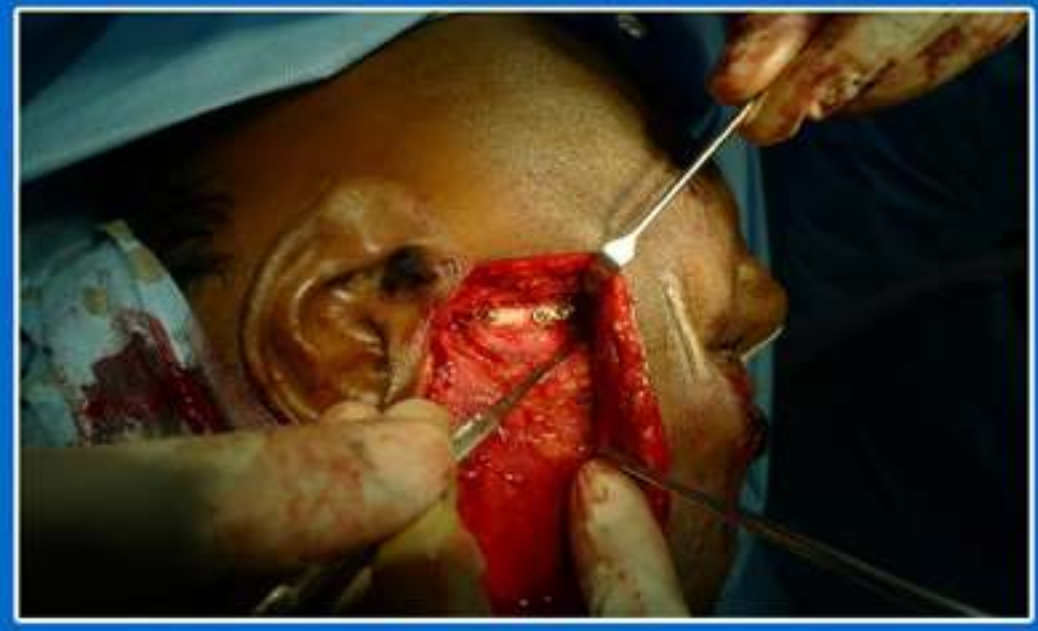Zygomatic Arch



Fixation



Fixation



Fization