



Chettinad
Dental College & Research Institute



Department of
PERIODONTICS
SURGICAL CASE ALBUM



Flap Surgery

Case: Flap Surgery

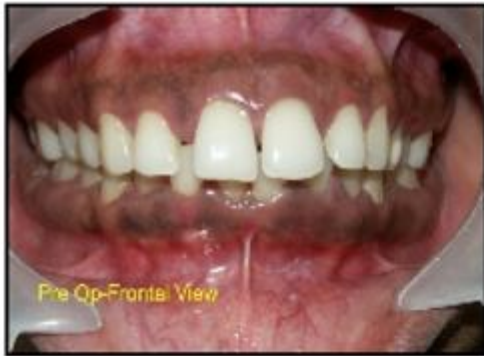Patient Name: Mr.Prakash

Age/sex: 27y/M

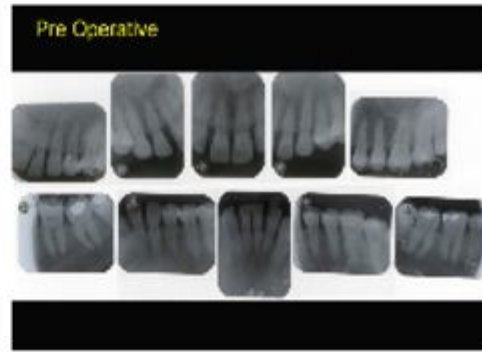OP No: 201106 110036

Date: 2/7/2011

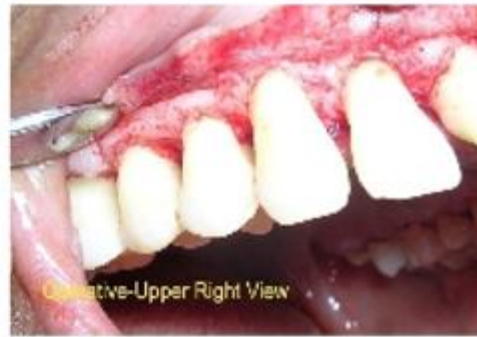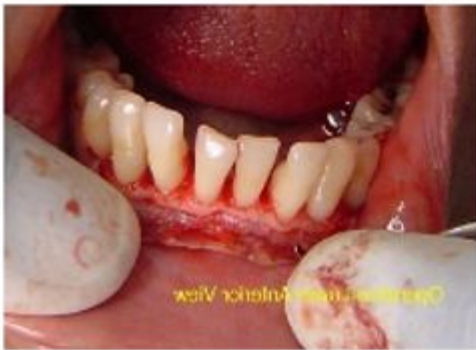Flap surgery



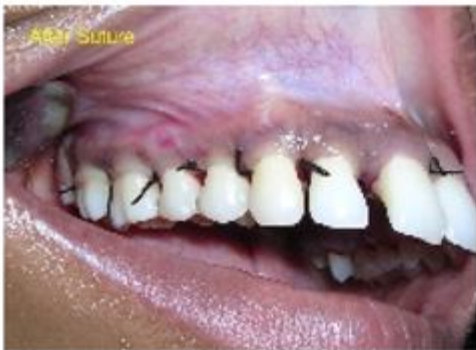Pre operative



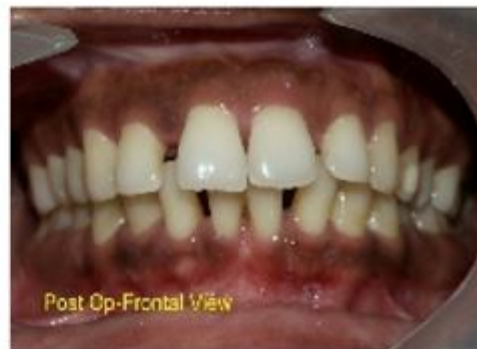Pre Operative Radiographs



Flap elevation & curettage



Flap Sutured



Post Operative



Bone grafting

Case: Bone Grafting with
Platelet Rich Fibrin

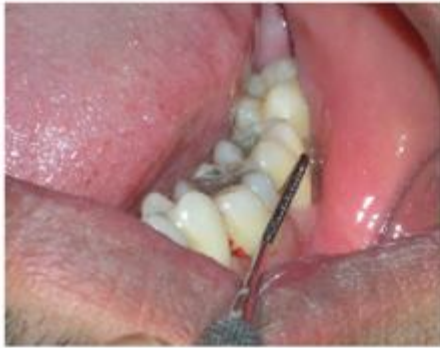Patient Name: Mrs.Lalitha

Age/sex: 40y/F

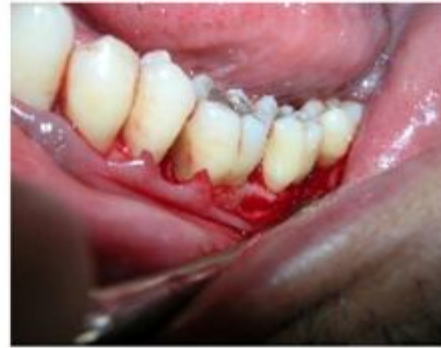OP No: 201105 160028

Date: 2/6/2011

Bone Grafting with Platelet Rich Fibrin



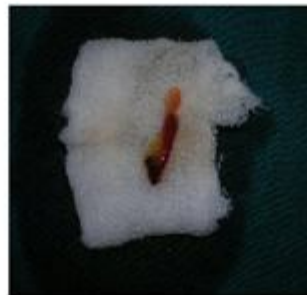Pre-operative



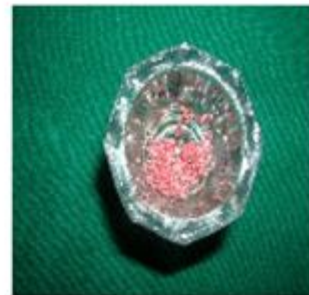
Full Thickness flap elevated



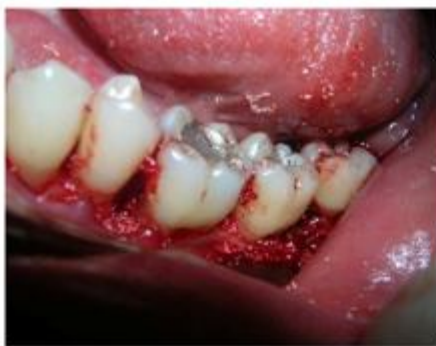PRF Preparation



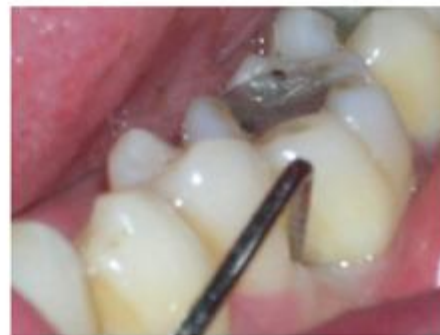PRF Gel



PRF and Bone graft



**Bone Graft Placed
In Defect Site**



Post Operative

Case- Bone Grafting with Allograft
(Perio glass)

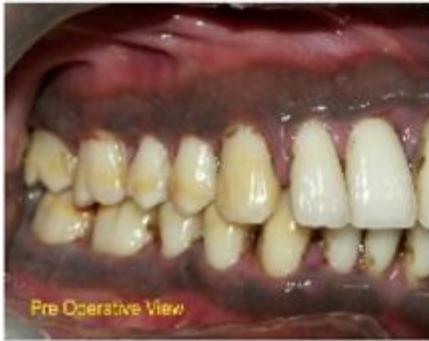Patient Name: flap surgery

Age/sex: 28y/M

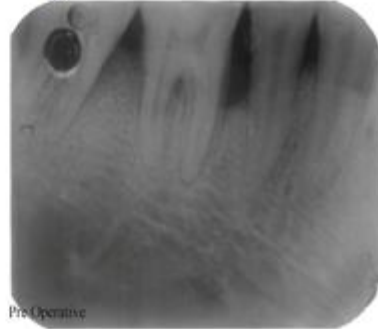
OP No: 200903 070002

Date: 19/3/2009

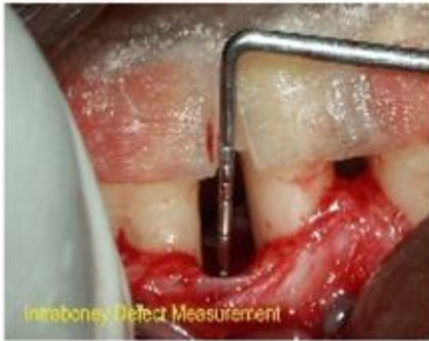Bone Grafting with Allograft (Perio glass)



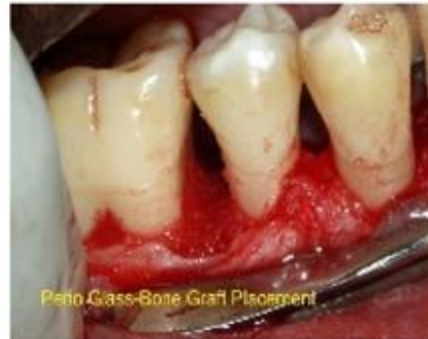Pre-operative



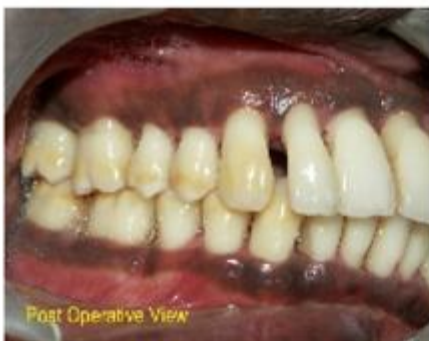Pre-operative Radiograph



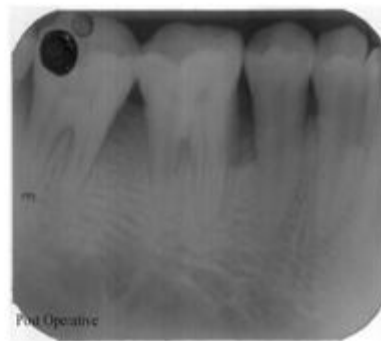
**Infra bony defect
measurement**



Perio glass bone graft placed



Post operative



Post operative Radiograph



*Mucogingival
Surgery*

Case: Bone Grafting with
Allograft (Perio glass)

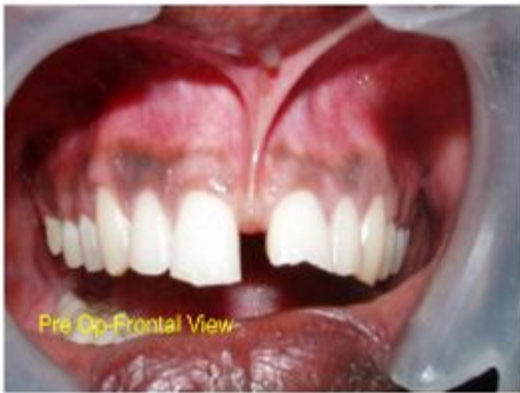Patient Name: Mr. Gopinath

Age/sex: 17y/M

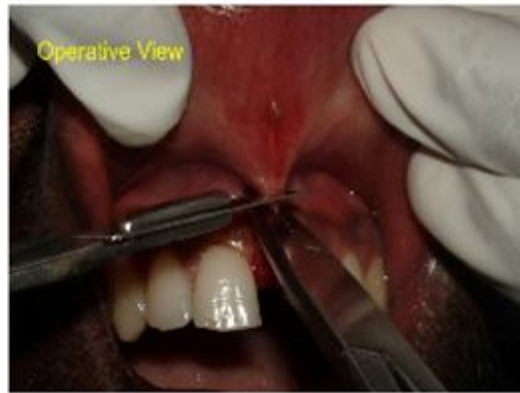OP No: 200905 050022

Date: 18/5/2009

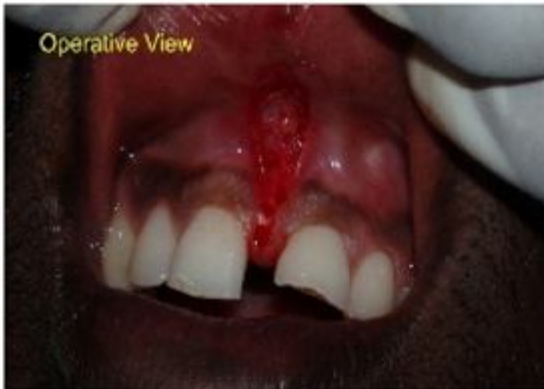Frenectomy



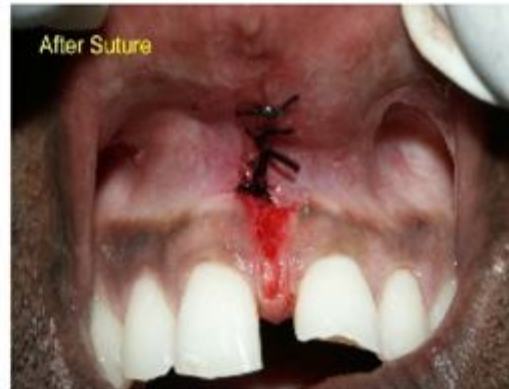Pre-operative



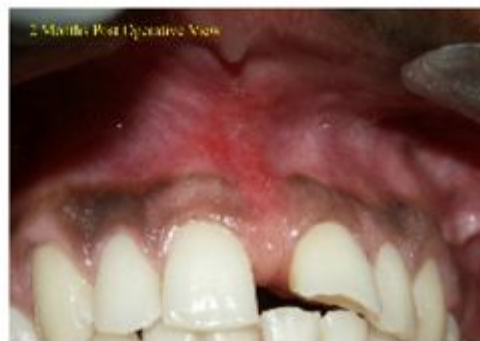Frenal Excision



Frenum Excised



Suture placed



Post operative

Case- Ridge Augmentation with Allograft
(Osteora)

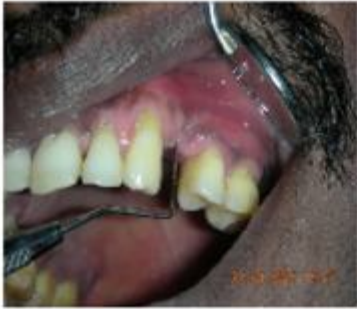Patient Name: Mrs. Saroja

Age/sex: 38y/F

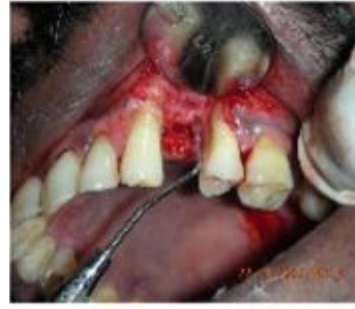OP No: 200906 260016

Date: 6/8/2009

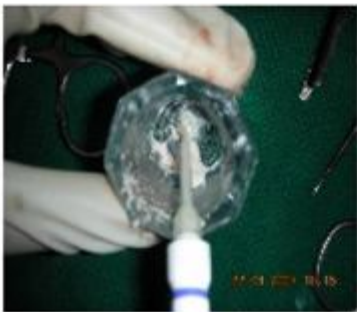Ridge Augmentation with Allograft (Osteora)



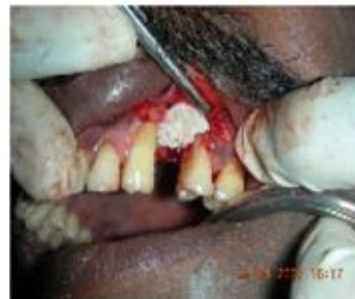Pre- operative



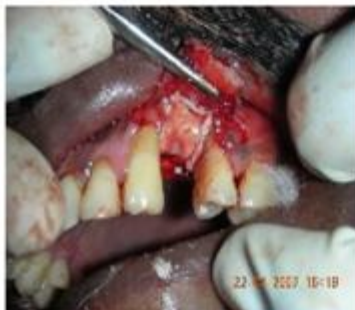Full thickness flap elevation



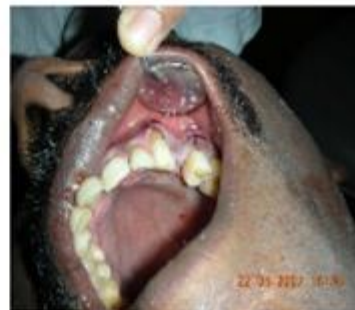**Bone graft mixed
with Osteora**



**Bone graft placed in
the defect site (24)**



**Bone graft and GTR membrane
placed in the defect site (24)**



Post operative

Case- Bridge flap

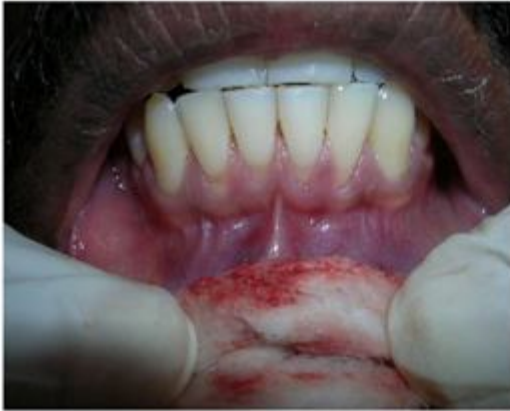Patient Name: Mr.Rajesh

Age/Sex: 27y/M

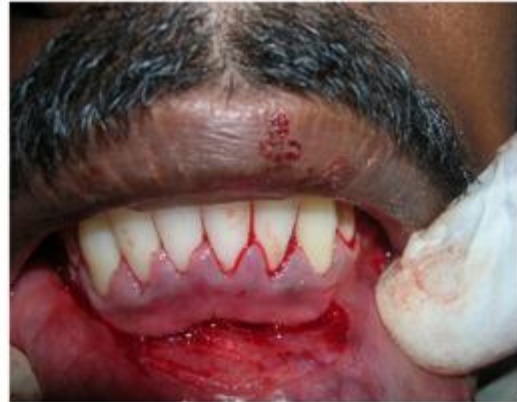OP No: 201106 140004

Date: 18/6/2011

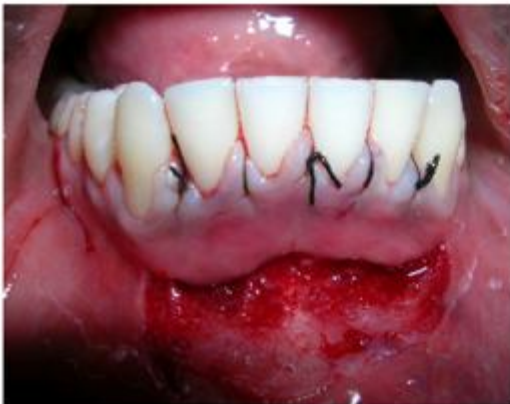Bridge flap



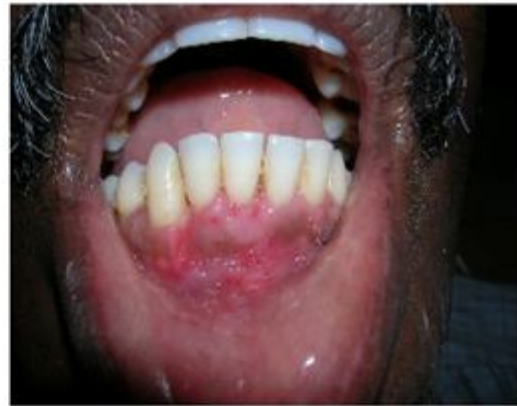Pre-operative



Incision Placed



Flap sutured



Post-operative

Case- Bridge Flap

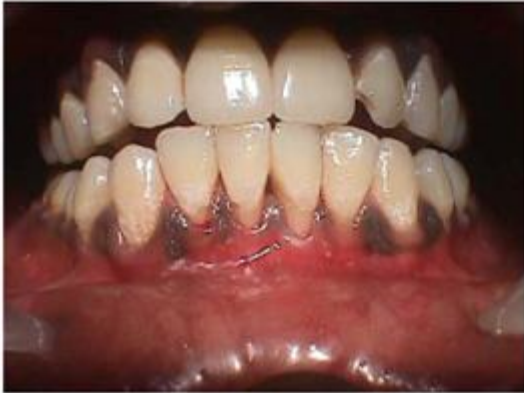Patient Name: Mrs. Rehana

Age/Sex: 50y/F

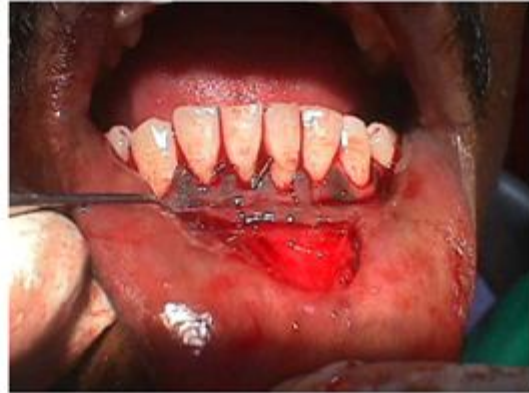OP No: 200905 280002

Date: 3/2/2011

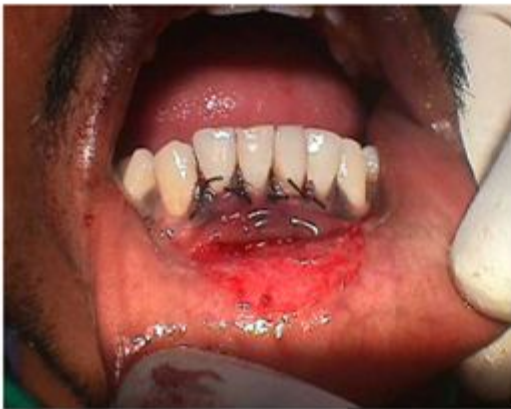Bridge Flap



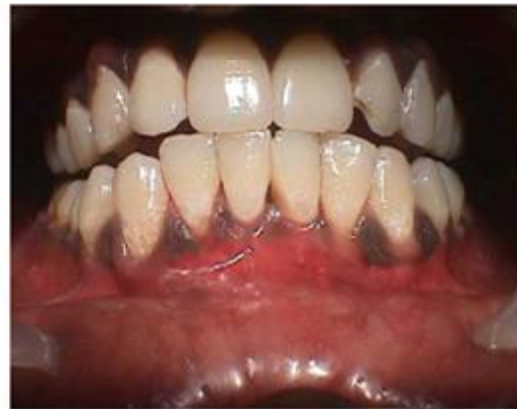Pre-operative



Incision placed



Flap sutured



Post- operative

Case- Root Coverage With
Platelet Rich Plasma

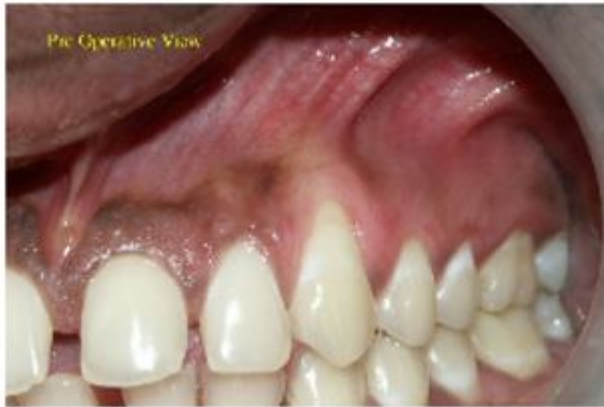Patient Name: Mrs.Kasthuri

Age/Sex: 24y/F

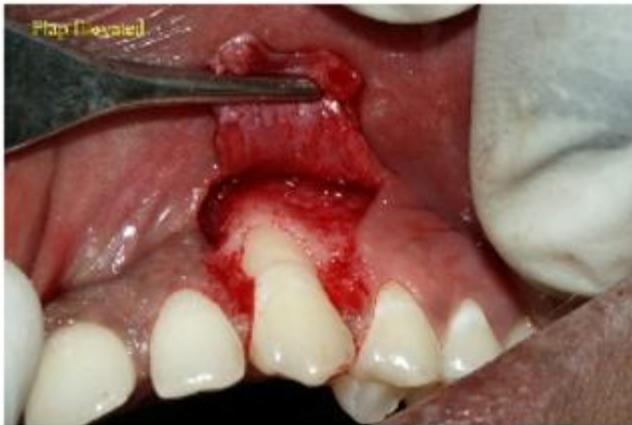OP No:201104 300045

Date: 4/6/2011

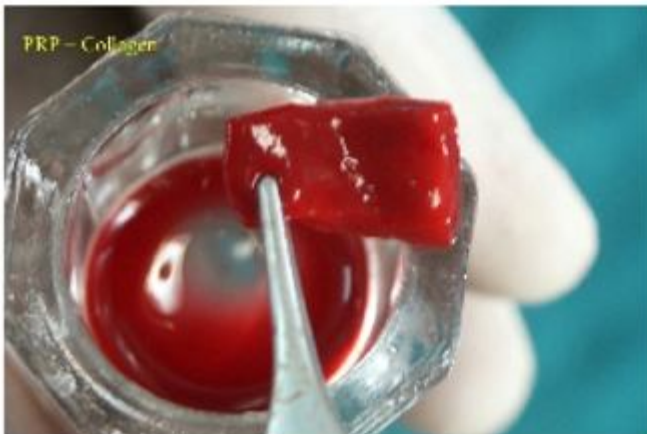Root Coverage With Platelet Rich Plasma



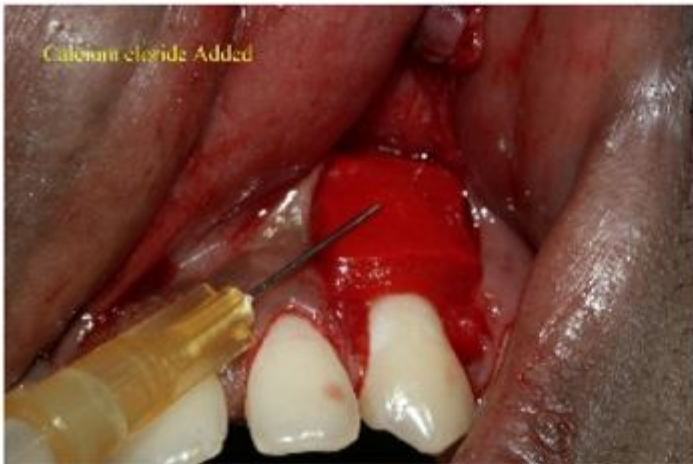Pre-operative



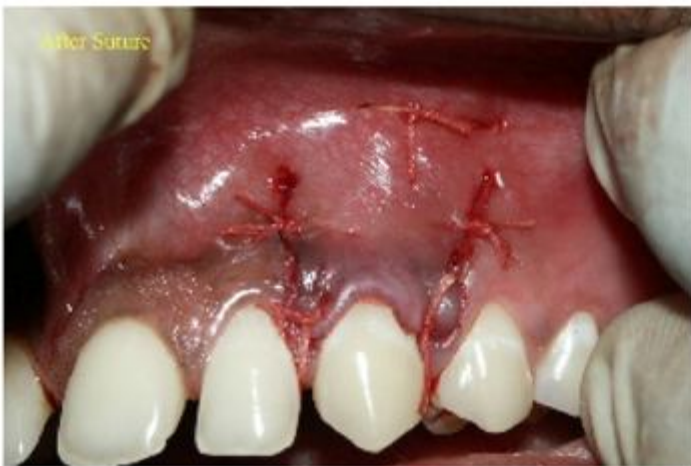Flap Elevated



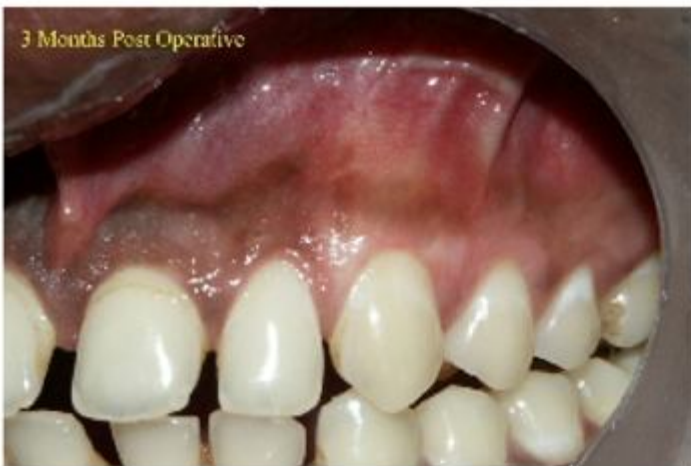PRP + Collagen



**Graft placed
at defect site**



Flap Sutured



Post-operative

Case- Socket Preservation

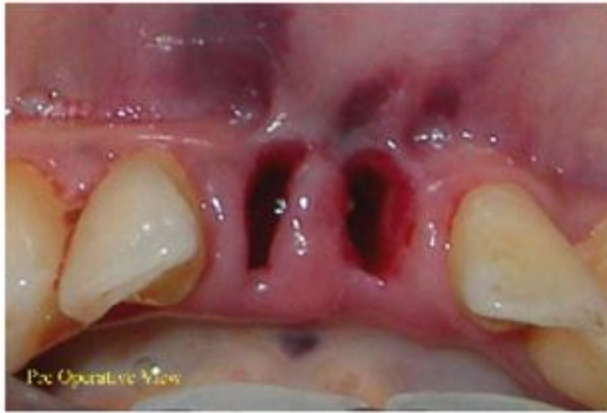Patient Name: Mrs. Saroja

Age/Sex: 38y/F

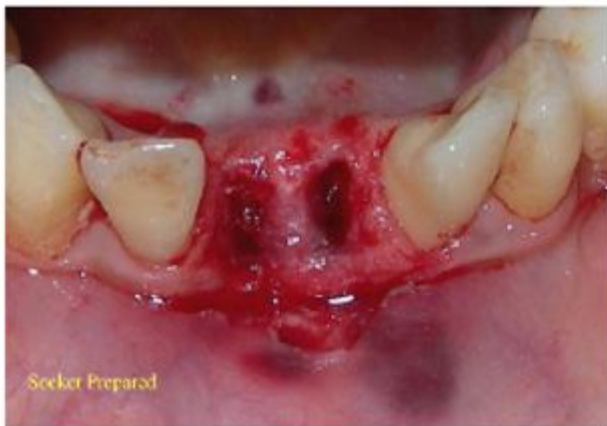OP No: 200906 260016

Date: 6/8/2009

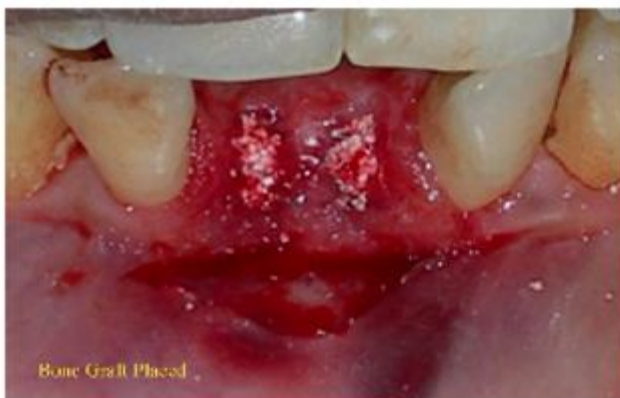Socket Preservation



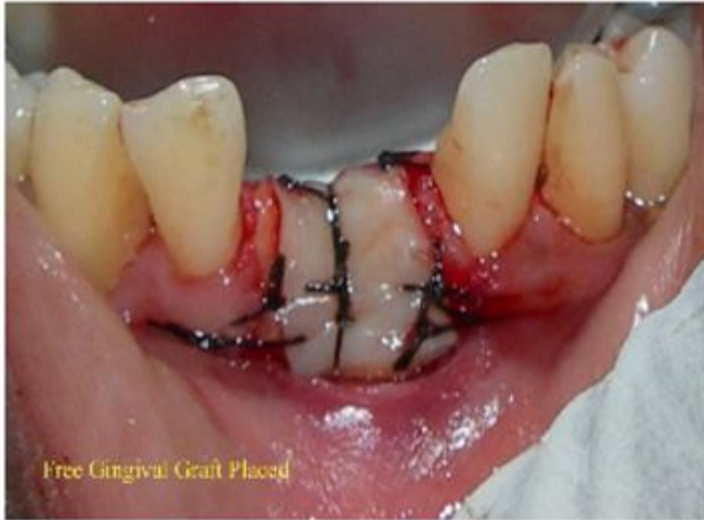Pre-operative



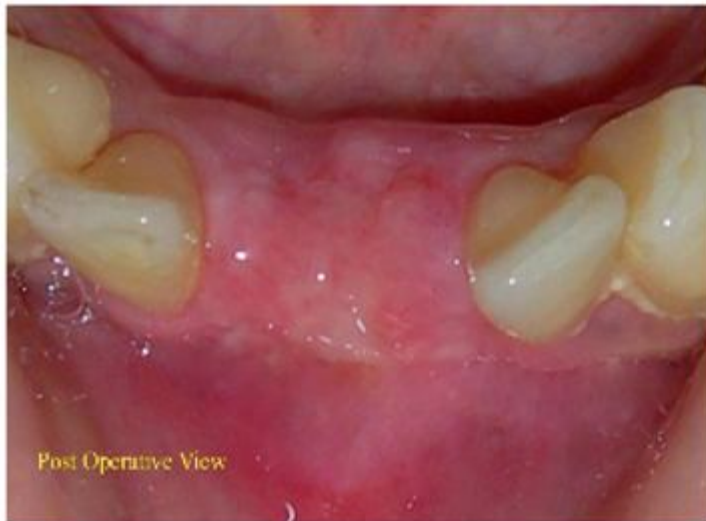Socket Prepared



Bone graft placed



**Free gingival
Graft placed**



Post operative

Case- Crown Lengthening

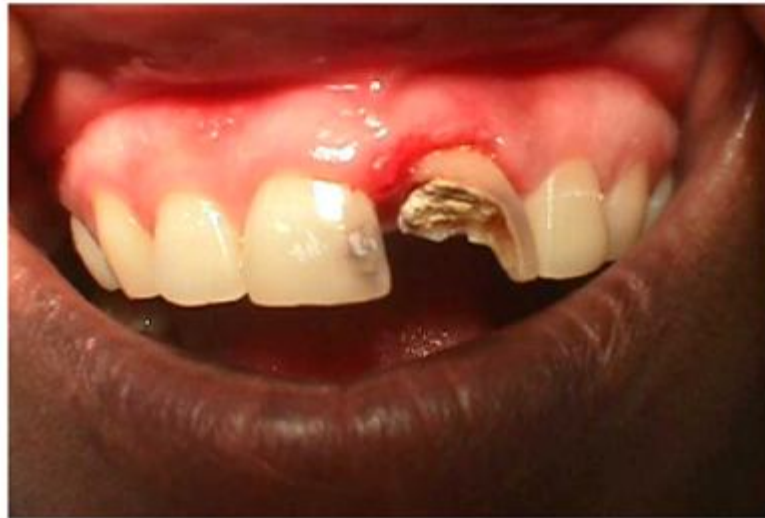Patient Name: Ms.Saradha

Age/Sex: 18y/F

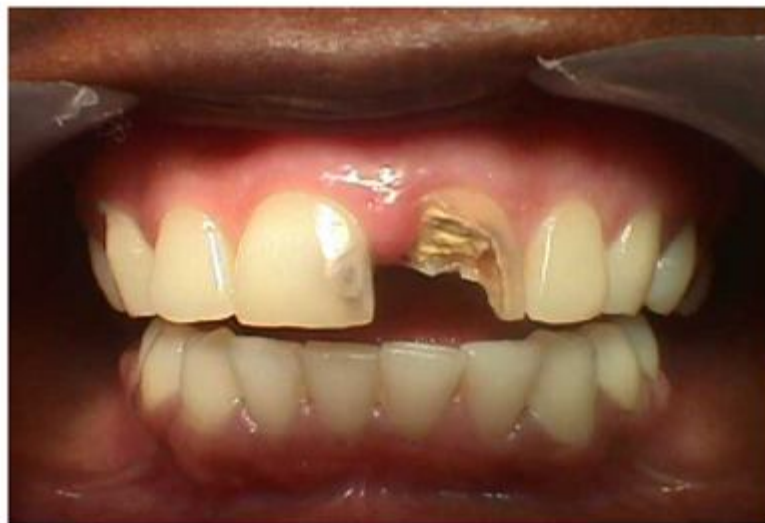OP No: 201104 300043

Date: 3/5/2011

Crown Lengthening



Pre operative



Post operative

Case-Depigmentation of Gingiva

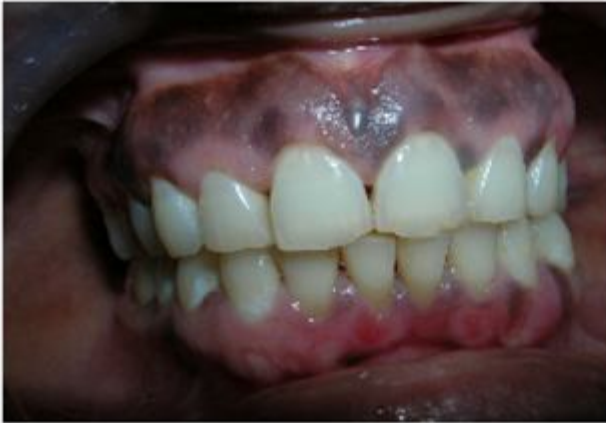Patient Name: Ms. Logeswari.

Age/Sex: 18y/F

OP No: 200708 240003

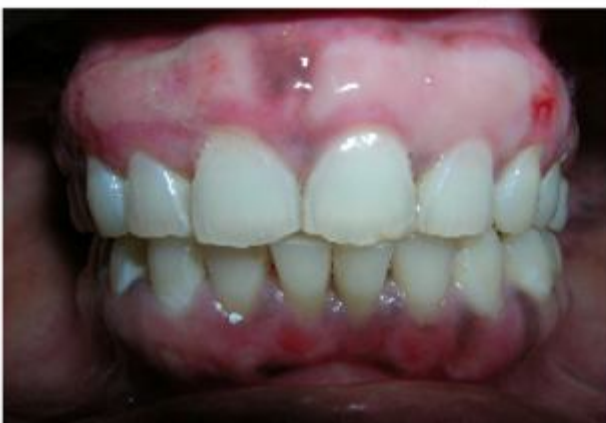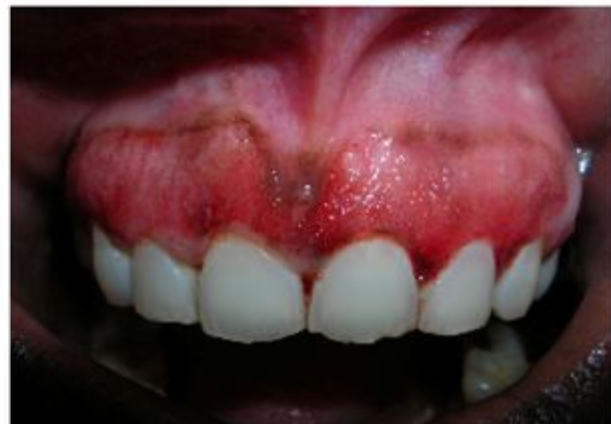Date: 8/7/2009

Depigmentation of Gingiva



Pre operative

**Depigmentation of
the Gingiva**



Post Operative

Case- Root Coverage with
Connective Tissue Graft

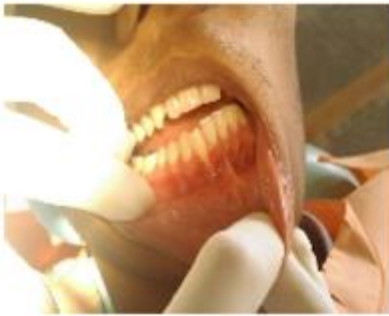Patient Name: Mr.Pawan kumar
Singh

Age/Sex: 22y/M

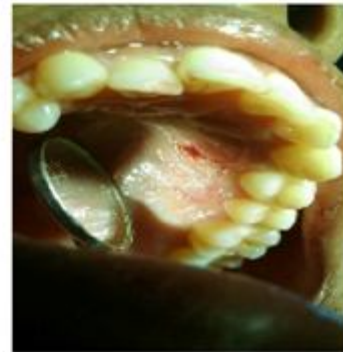OP No: 201104 090017

Date: 12/4/2011

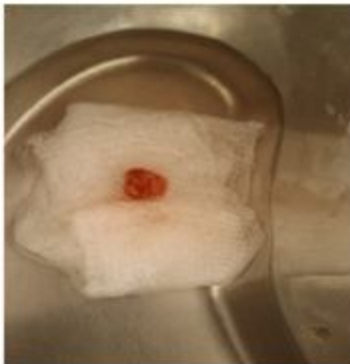Root Coverage with Connective Tissue Graft



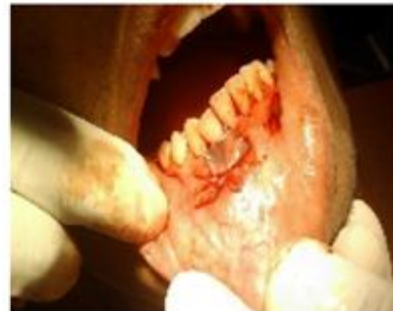Pre operative



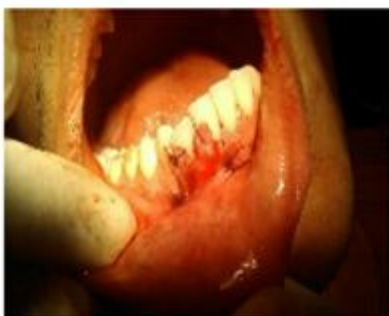Site of Connective graft excised



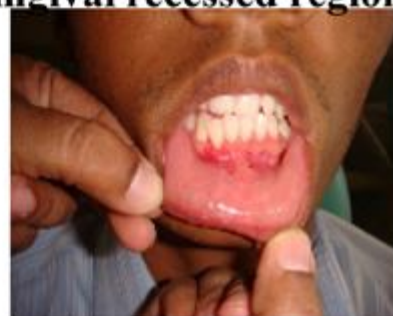Connective tissue graft



Connective tissue graft placed in Gingival recessed region



Sutures Placed



Post operative

Case- Coronally Repositioned Flap

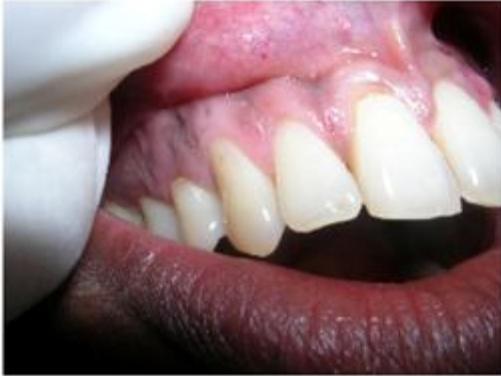Patient Name: Mr.Lakshminarayanan

Age/Sex: 28y/M

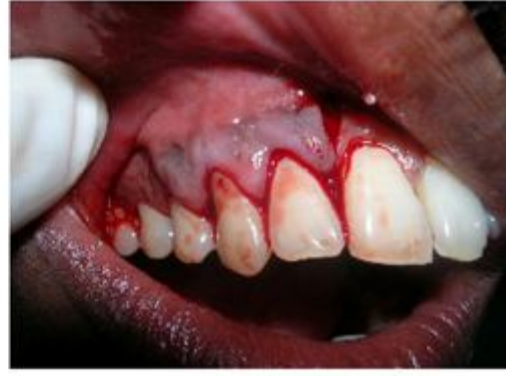OP No: 201106 080016

Date: 26/7/2011

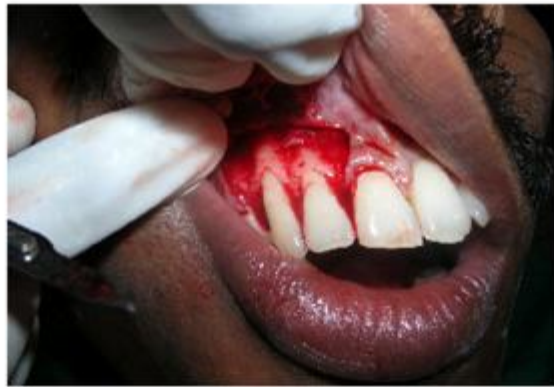Coronally Repositioned Flap



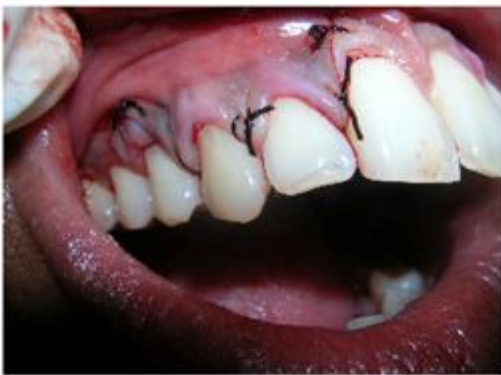Pre operative



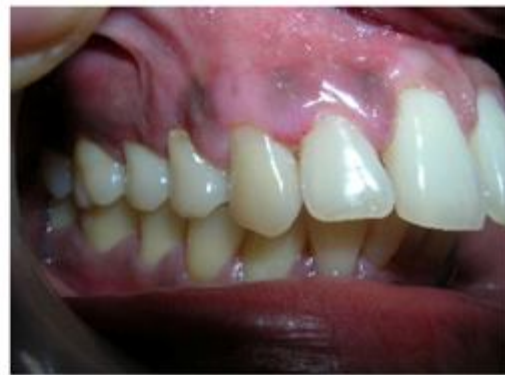Incision placed



Full thickness flap elevated



Flap sutured



Post operative

Case- Connective Tissue Graft

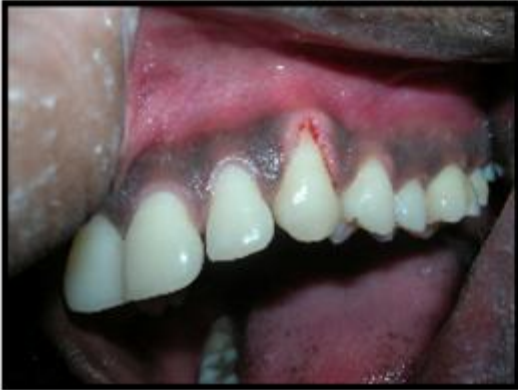Patient Name: Mrs. Terri Swanson

Age/Sex: 56y/F

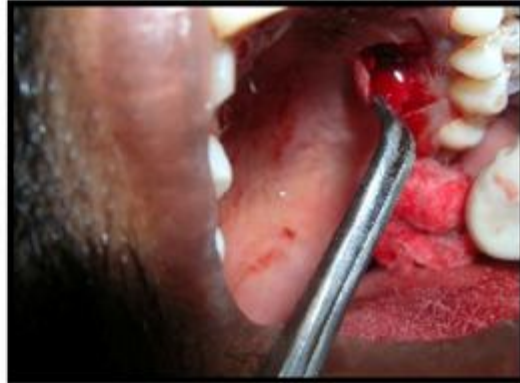OP No: 201104 180061

Date: 24/4/2011

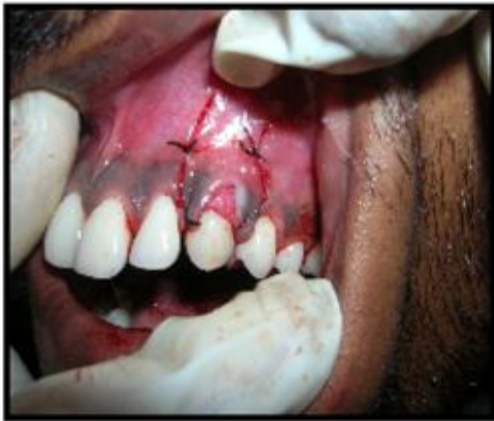Connective Tissue Graft



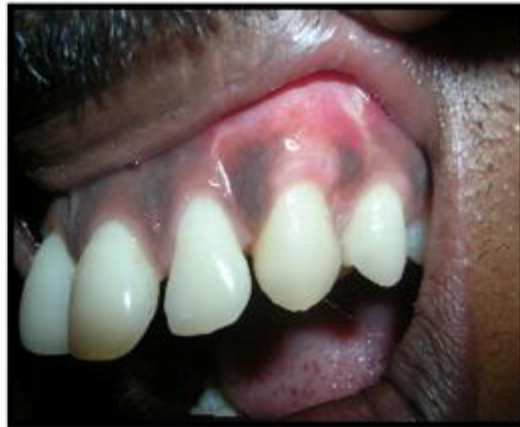Preoperative



**Connective tissue graft
Harvested**



**Connective tissue graft
Placed at recipient site**



Post-Operative

Case- Connective Tissue Graft

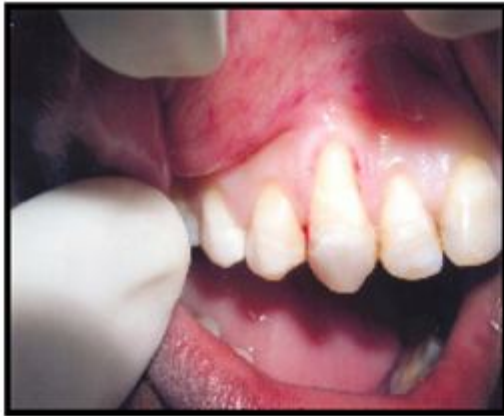Patient Name: Ms.Ramya

Age/Sex: 21y/F

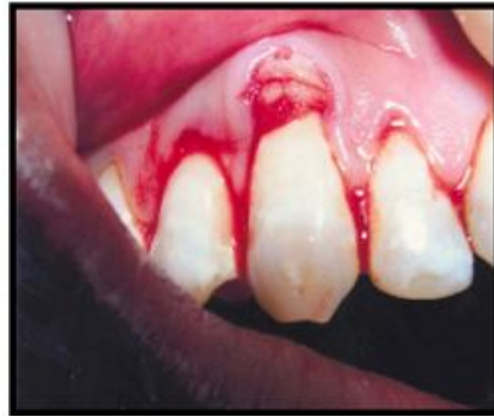OP No: 201011 270004

Date: 24/4/2011

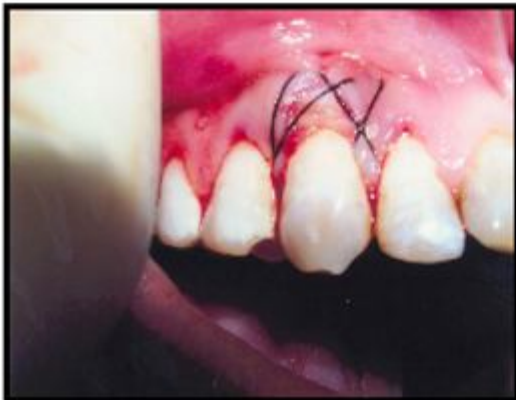Pouch And Tunnel Procedure



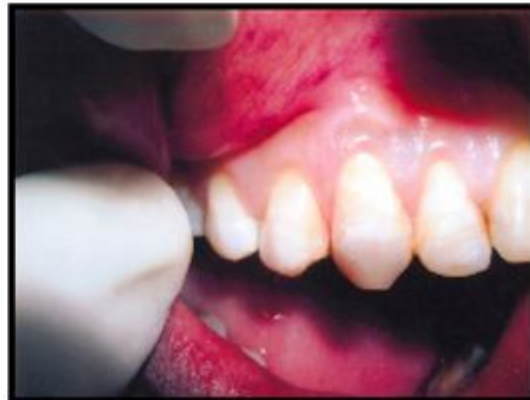Preoperative



**Connective tissue graft
Placed in the pouch**



Flap sutured



Post- Operative

Case- Extended mesh connective tissue
Graft

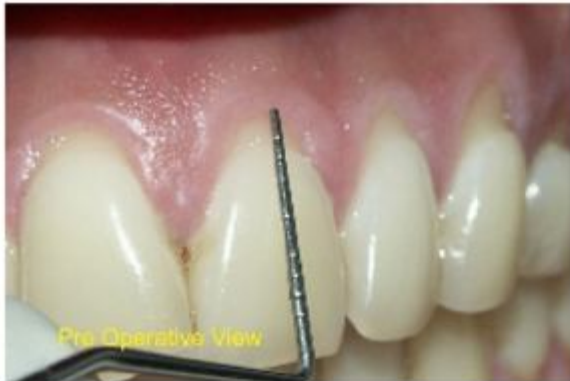Patient Name: Mrs.Jenova

Age/Sex: 32y/F

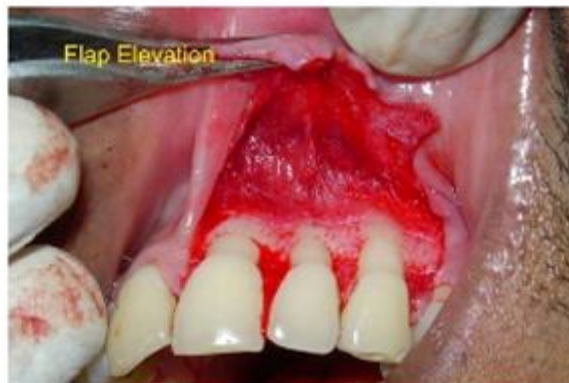OP No: 201103 110002

Date: 21/3/2011

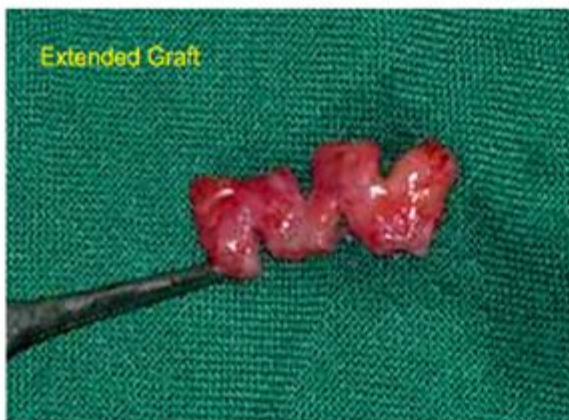Extended mesh connective tissue Graft



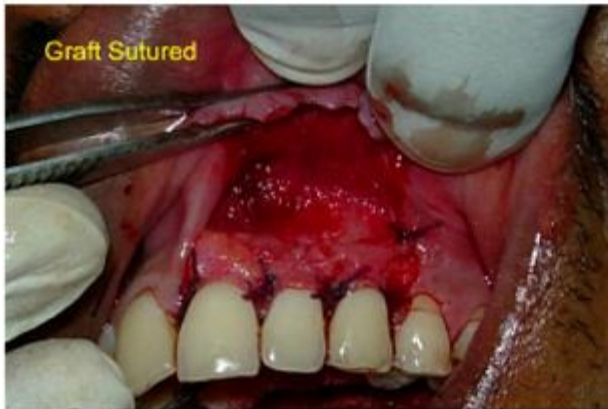Pre-operative



Flap elevation

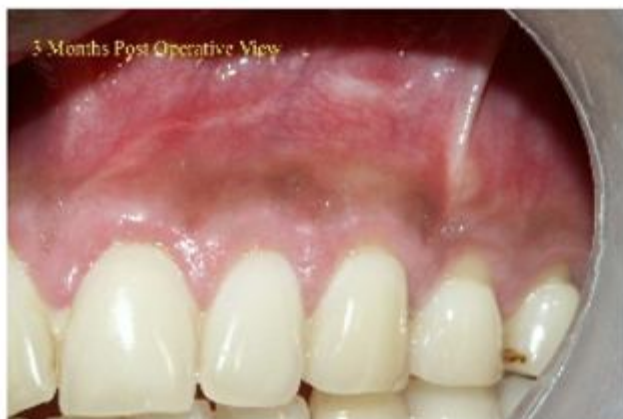
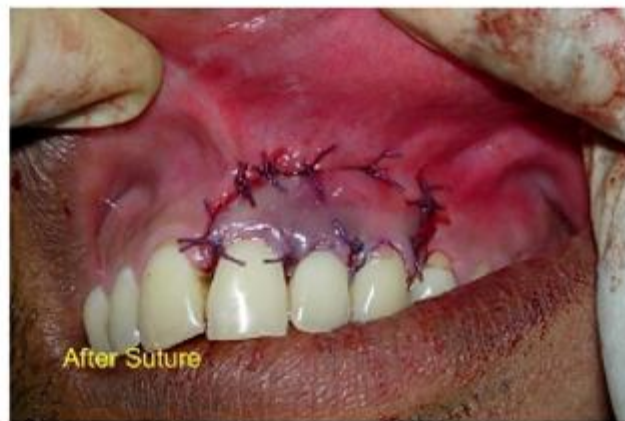
Extended CTG



Graft Sutured

Flap Sutured



Post-operative

Case- Connective Tissue Graft

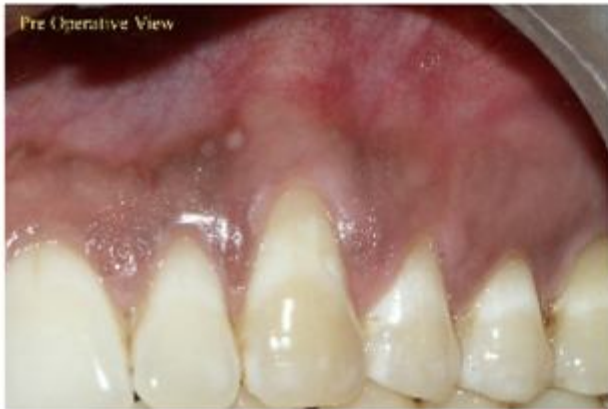Patient Name: Mr.Dhamodharan

Age/Sex: 26y/M

OP No: 201103 30008

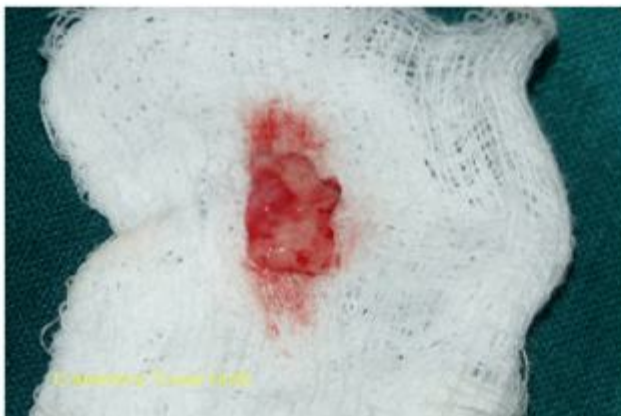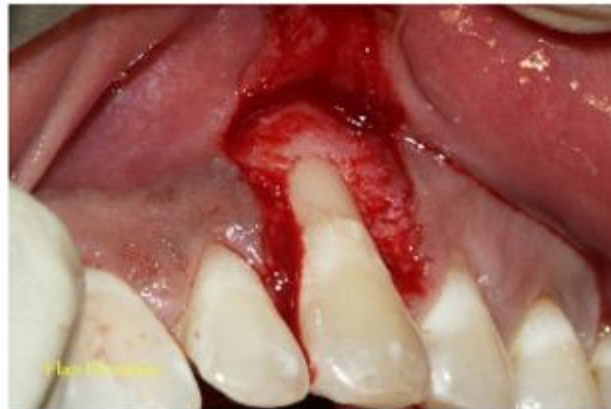Date: 1/4/2011

Connective Tissue Graft

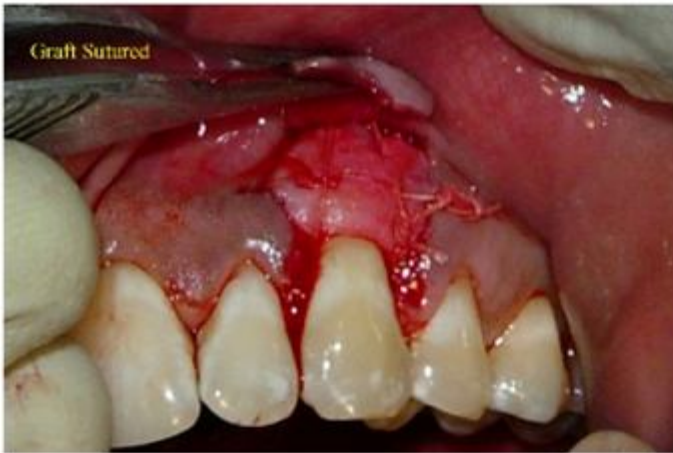

Pre-operative

Flap elevation

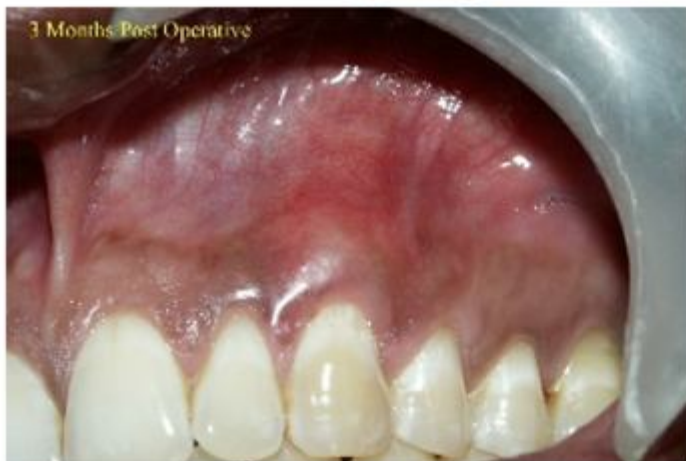
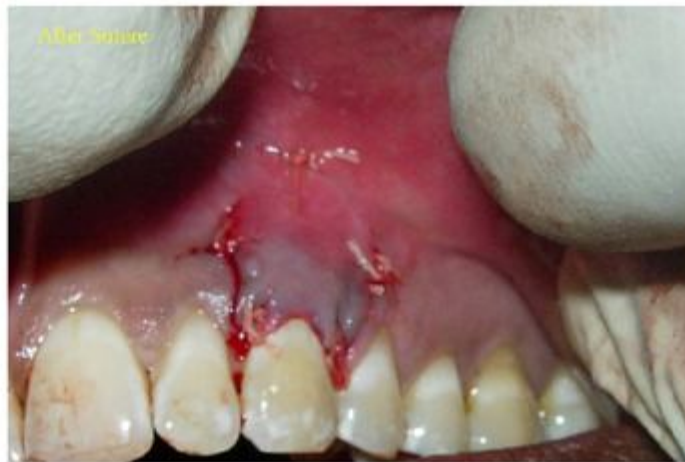
Connective Tissue Graft



Graft Sutured

Flap Sutured



Post Operative

Case- Root Coverage Using Emdogain

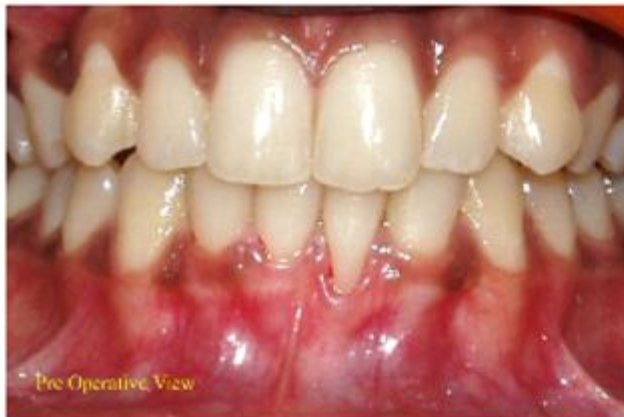Patient Name: Mr. Pavithra Malik

Age/Sex: 21y/M

OP No: 201011 110022

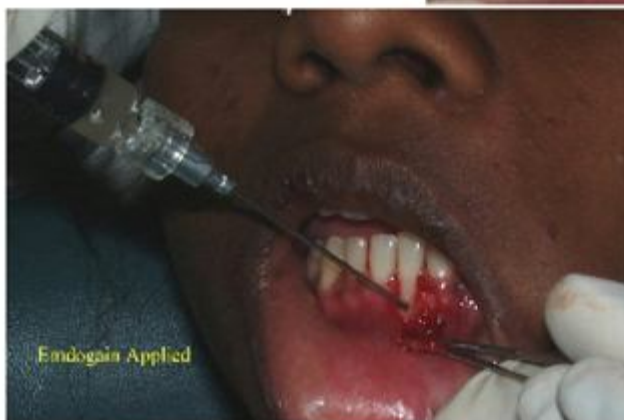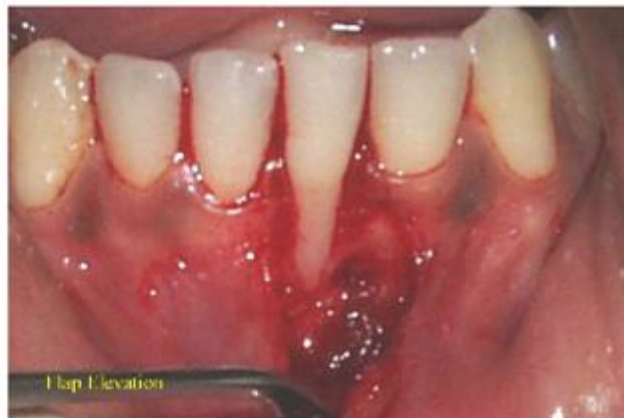Date:7/12/2010

Root Coverage Using Emdogain

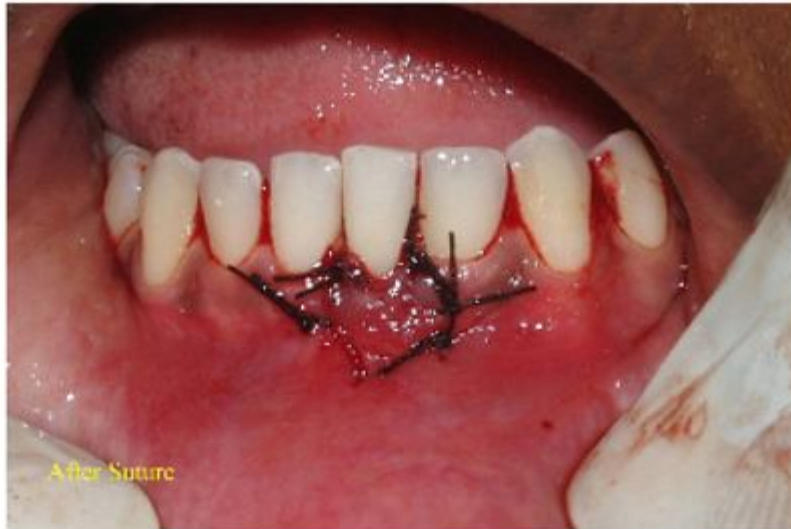

Pre Operative

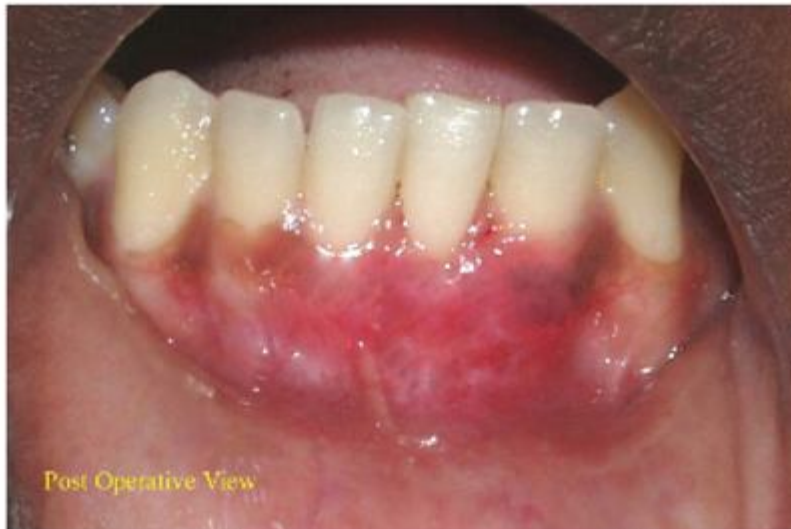Flap Elevation



Emdogain Applied



Flap Sutured



Post Operative

Case- Vestibular Deepening Procedure

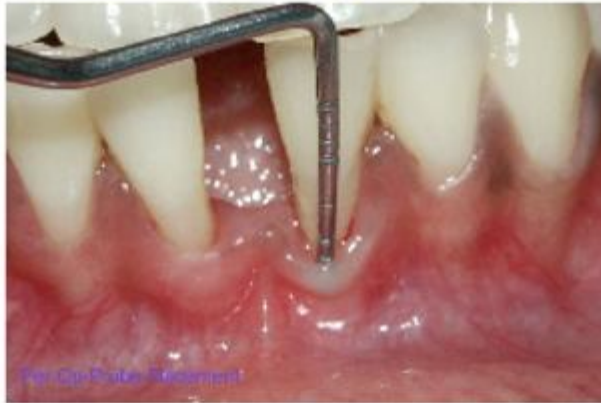Patient Name: Mr. Dinesh

Age/Sex: 18y/M

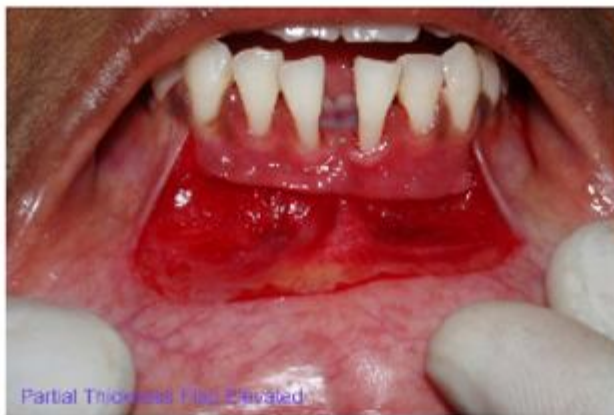OP No: 201008 110004

Date: 12/8/2010

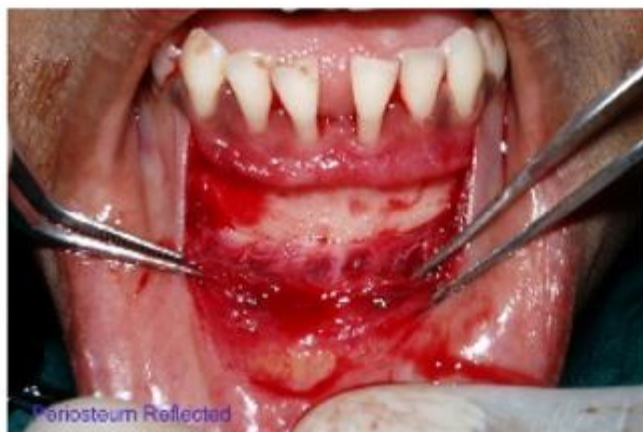Vestibular Deepening Procedure



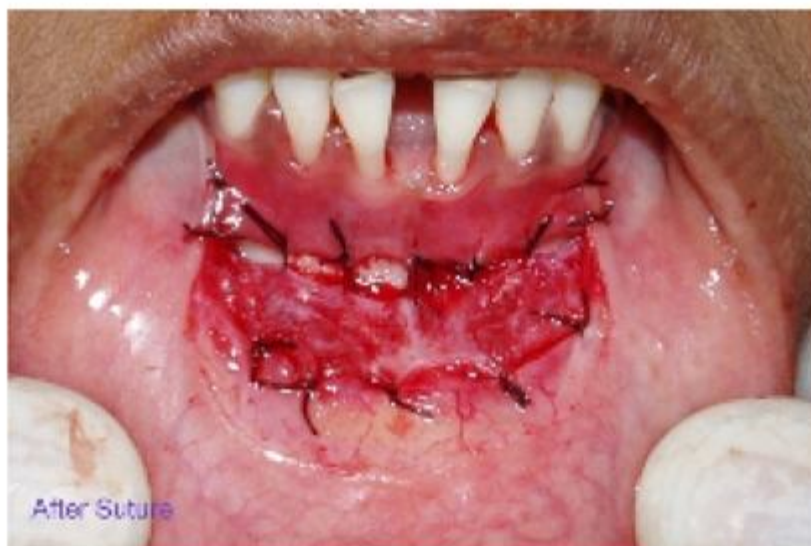Pre Operative



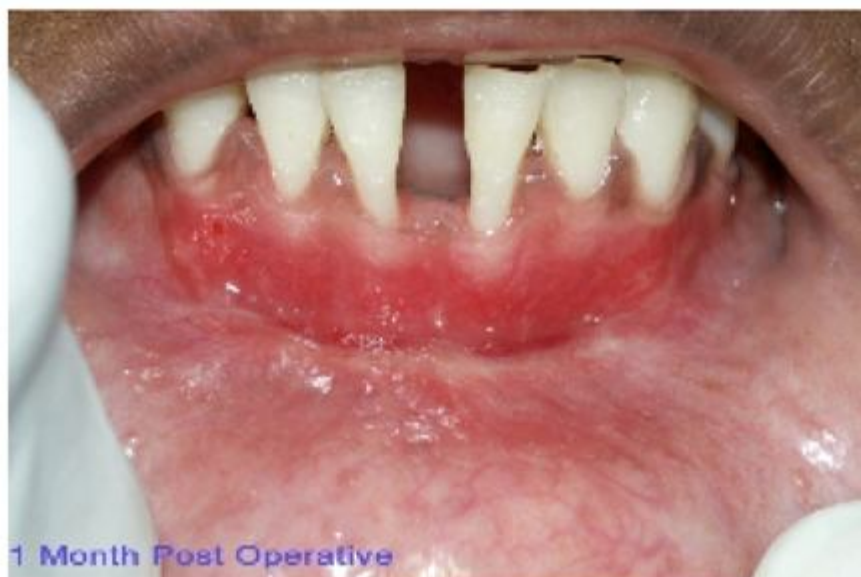Operative



Operative



Flap Sutured



Flap Sutured

CASE- Root Coverage Using GTR and Bone Graft

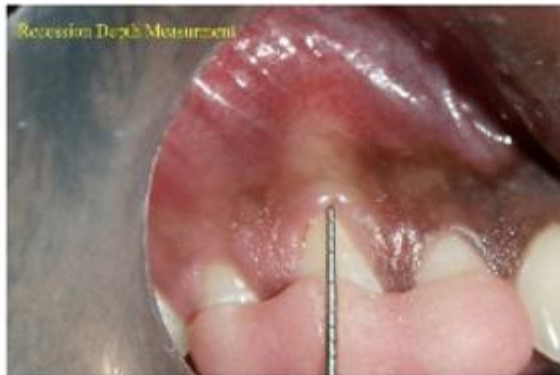Patient Name: Mr. Bharath Raju

Age/Sex: 29y/M

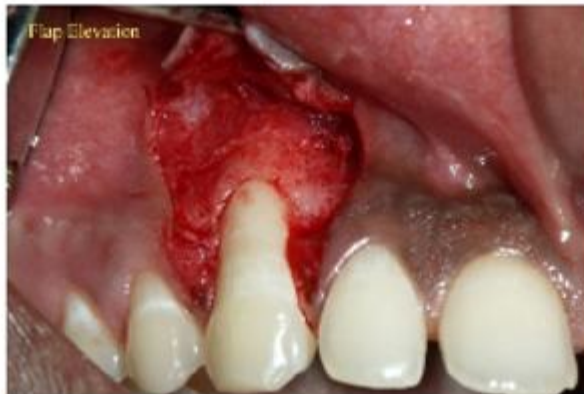OP No: 201102 150017

Date: 17/2/2011

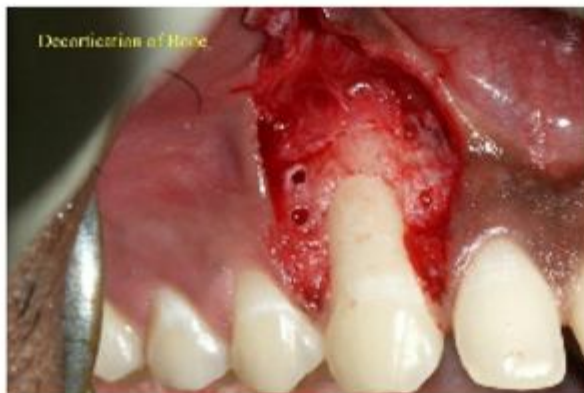Root Coverage Using GTR and Bone Graft



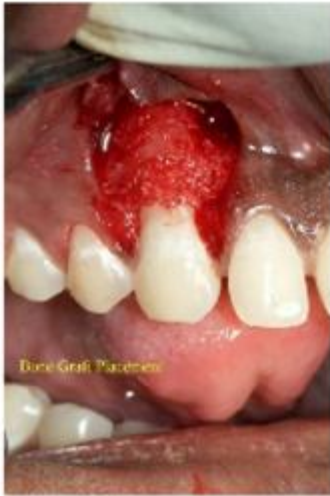Pre Operative



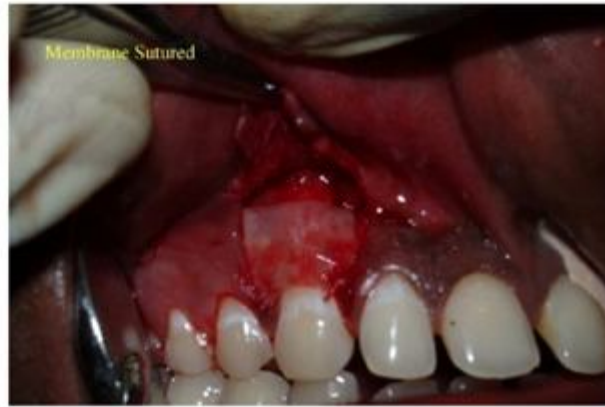Flap Elevation



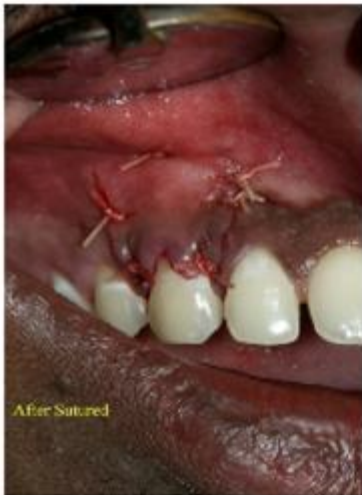Decortication of Bone



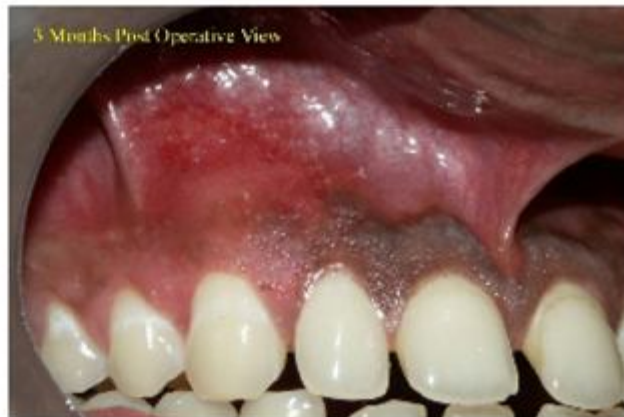Placement of
Bone Graft



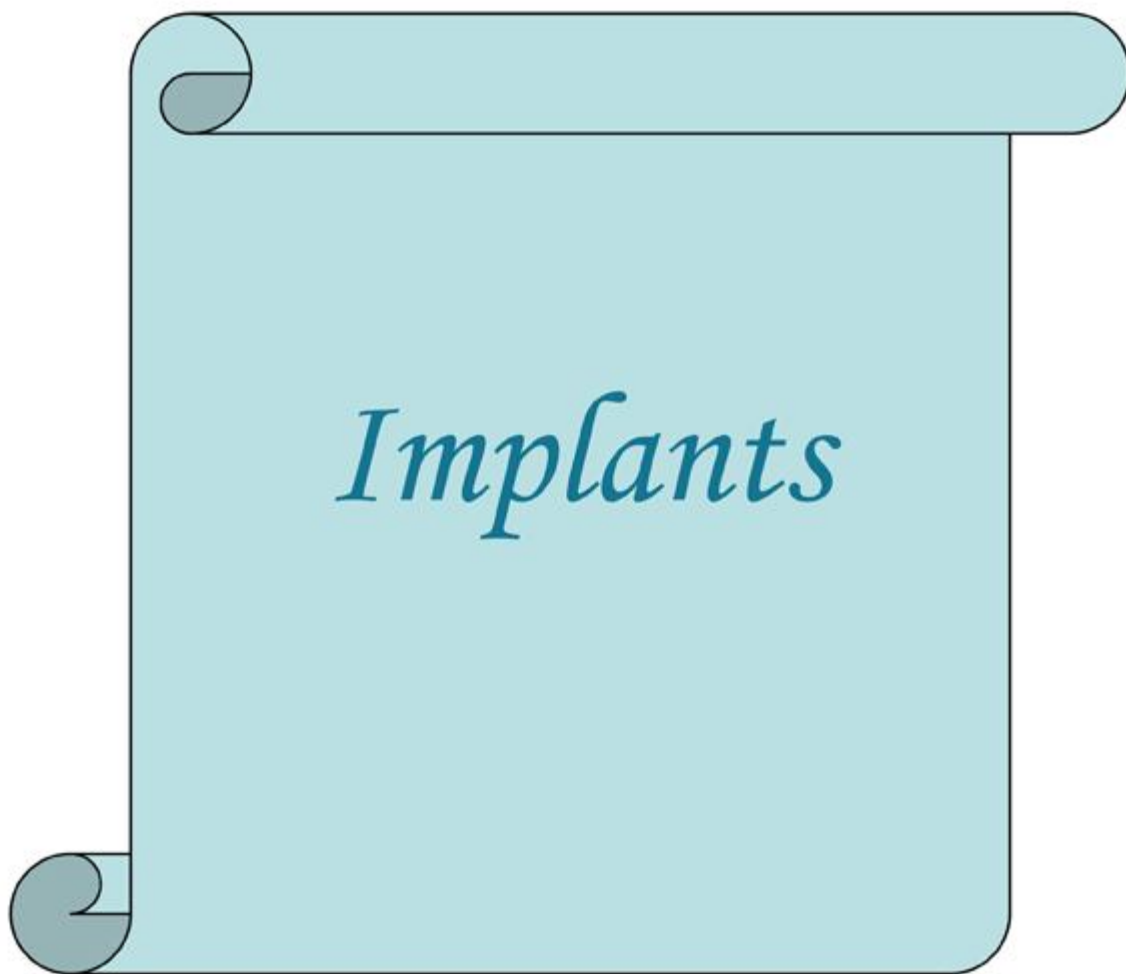
GTR Membrane Sutured



Flap Sutured



Post Operative



Implants

NAME: Mrs. Uthira Devi

AGE/SEX: 26/F

OP. No: 200907 040016

Date: 2/11/2009

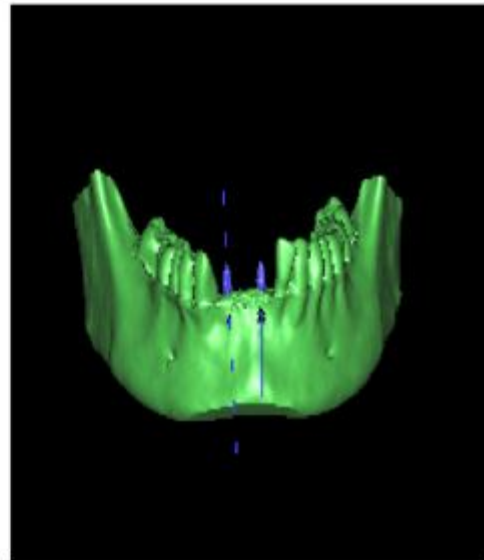
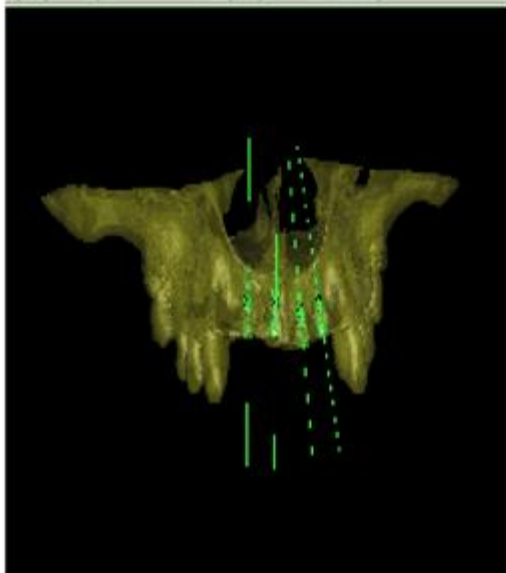
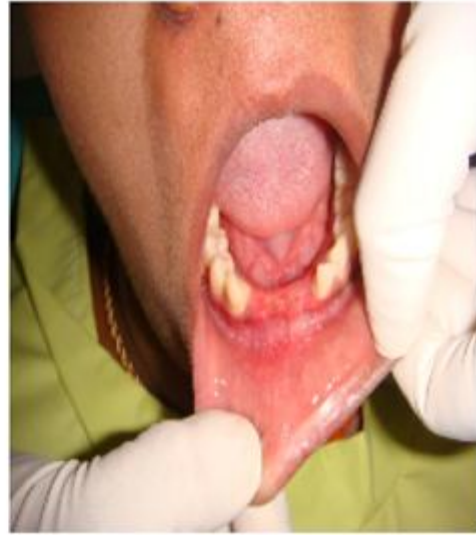
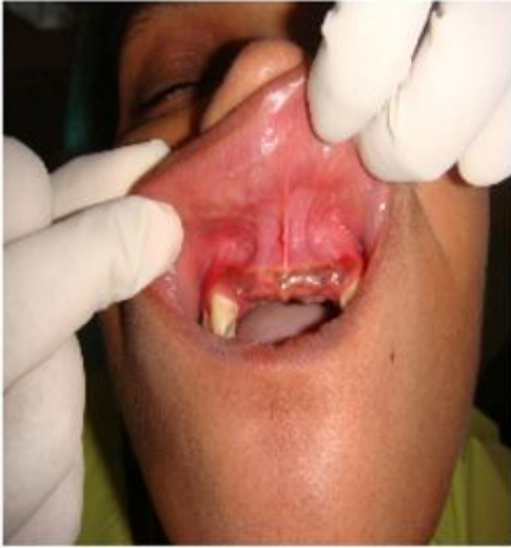
Pre Operative

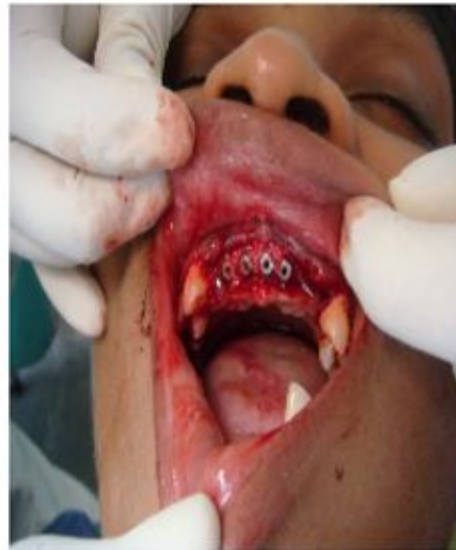
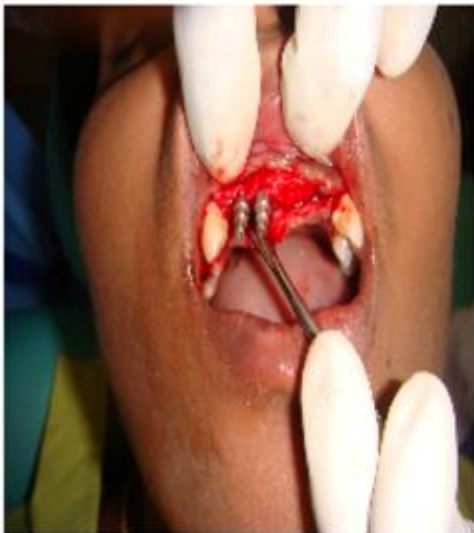
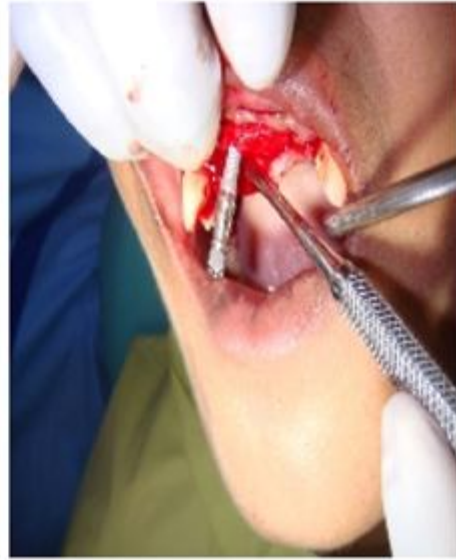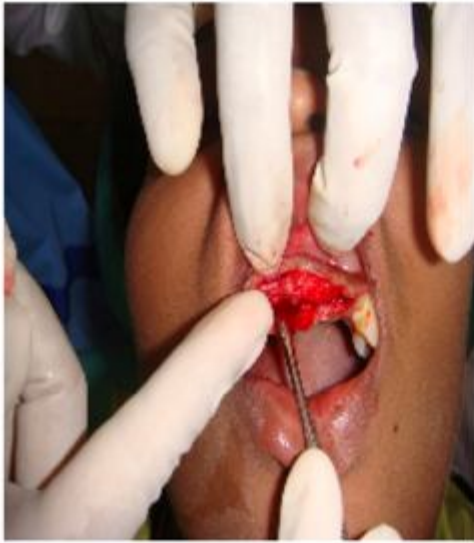Post Operative

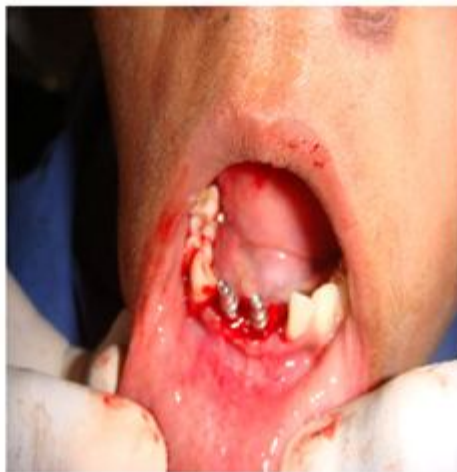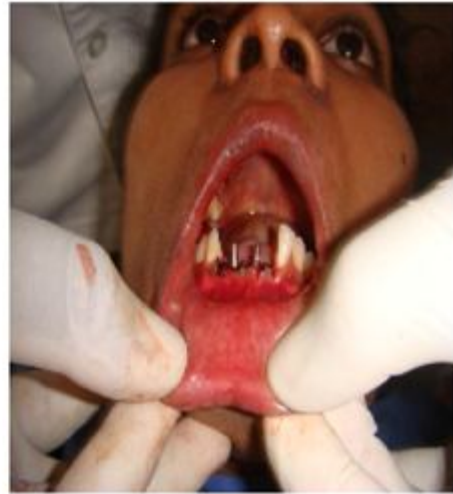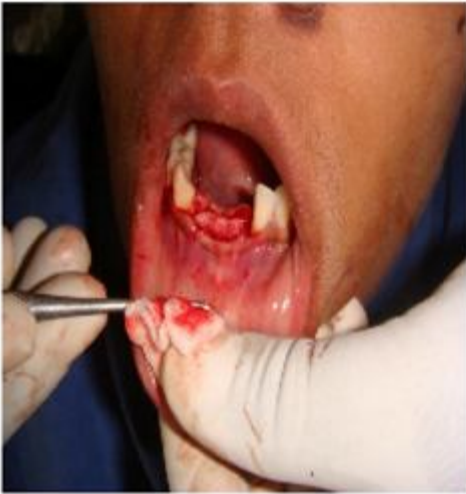3D Software Analysis



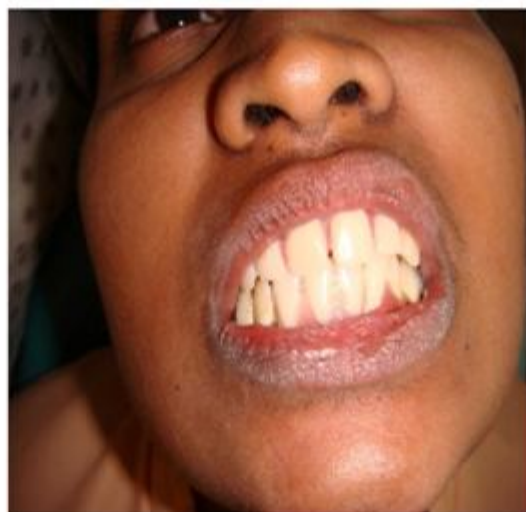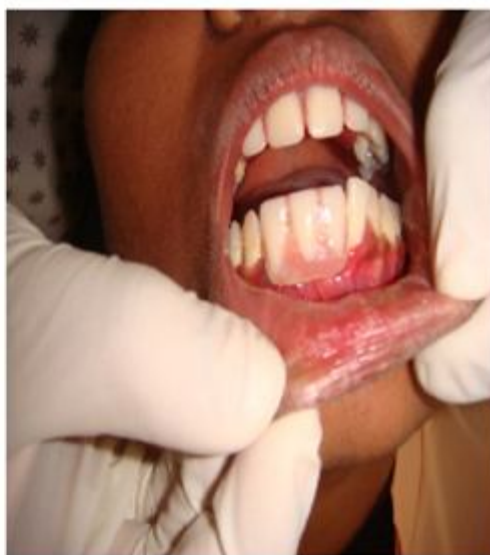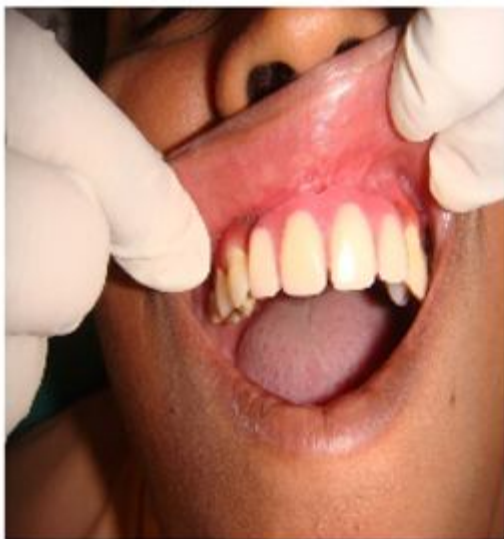Implant screw placement- Maxilla



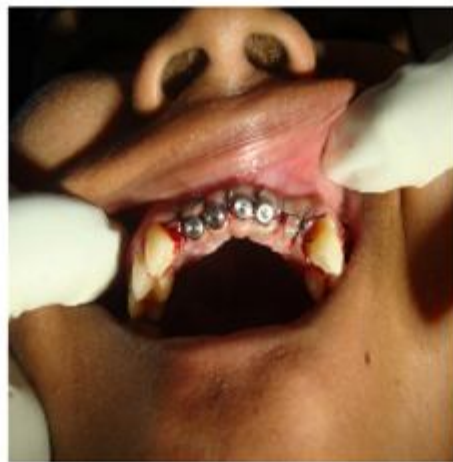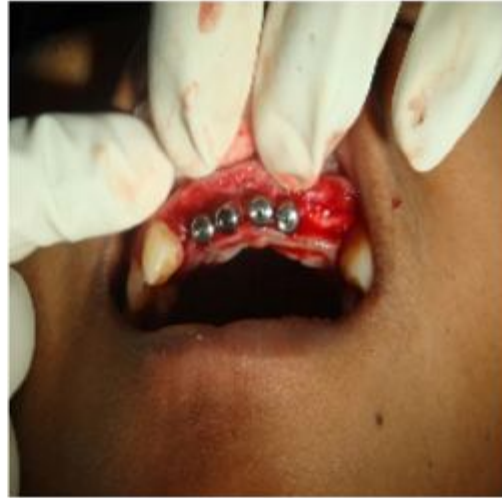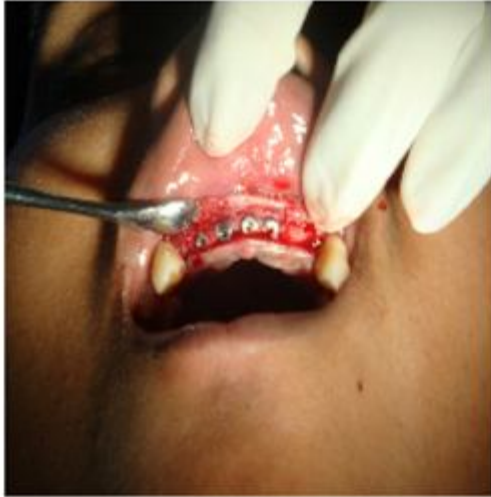Implant screw placement- mandible



Removable prosthesis



Healing cap placement



Abutment screw & Prosthesis

