



**Chettinad**

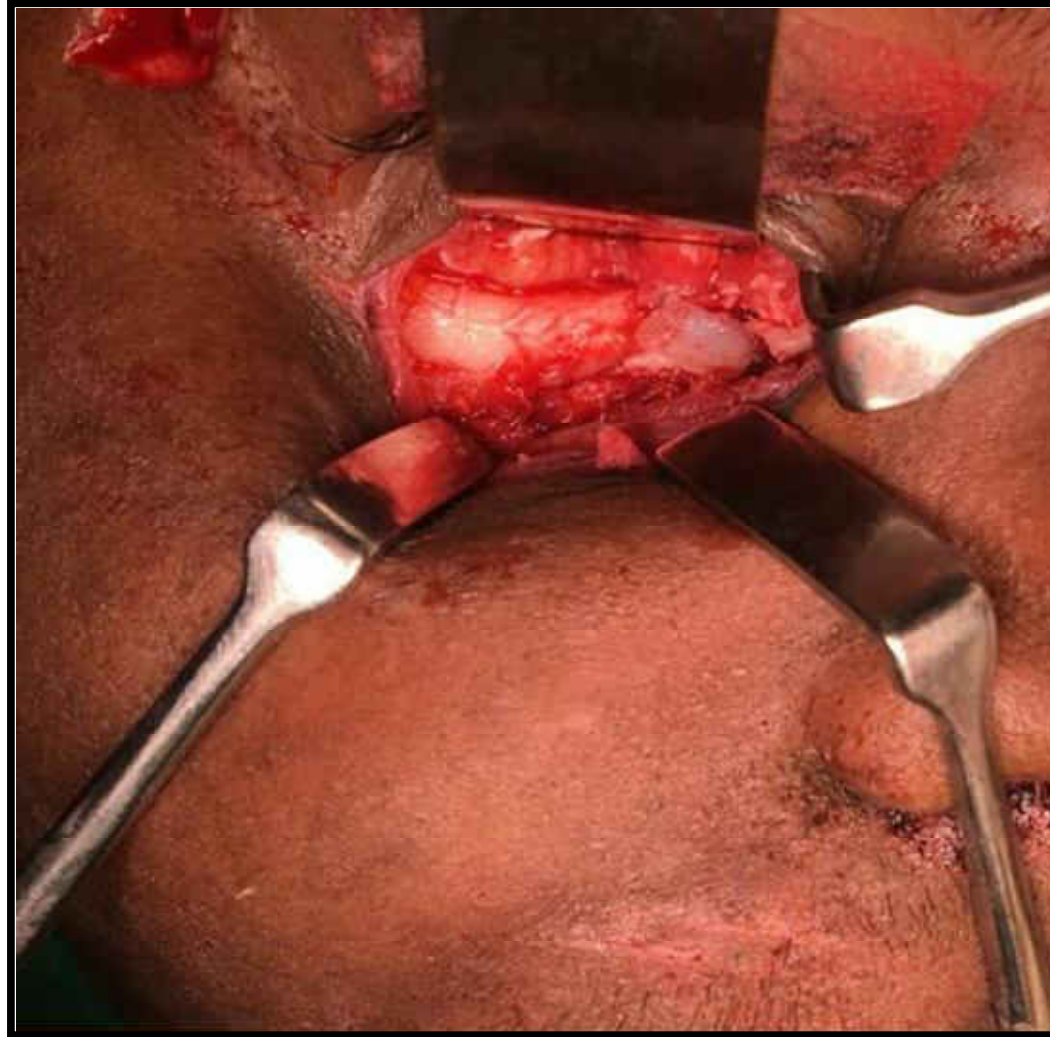
Dental College & Research Institute



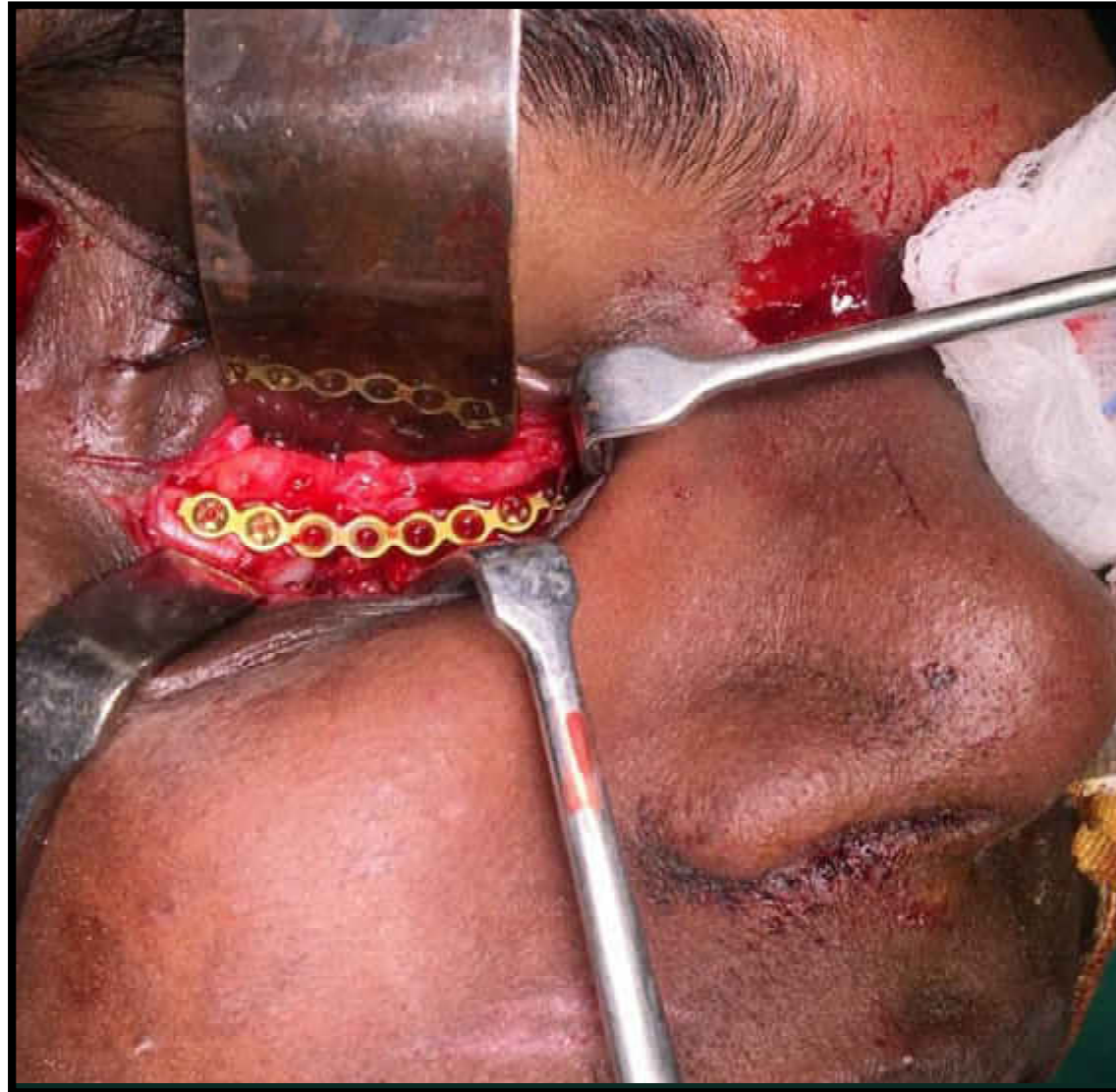# ORAL AND MAXILLOFACIAL SURGERY

# **MAJOR SURGERIES**

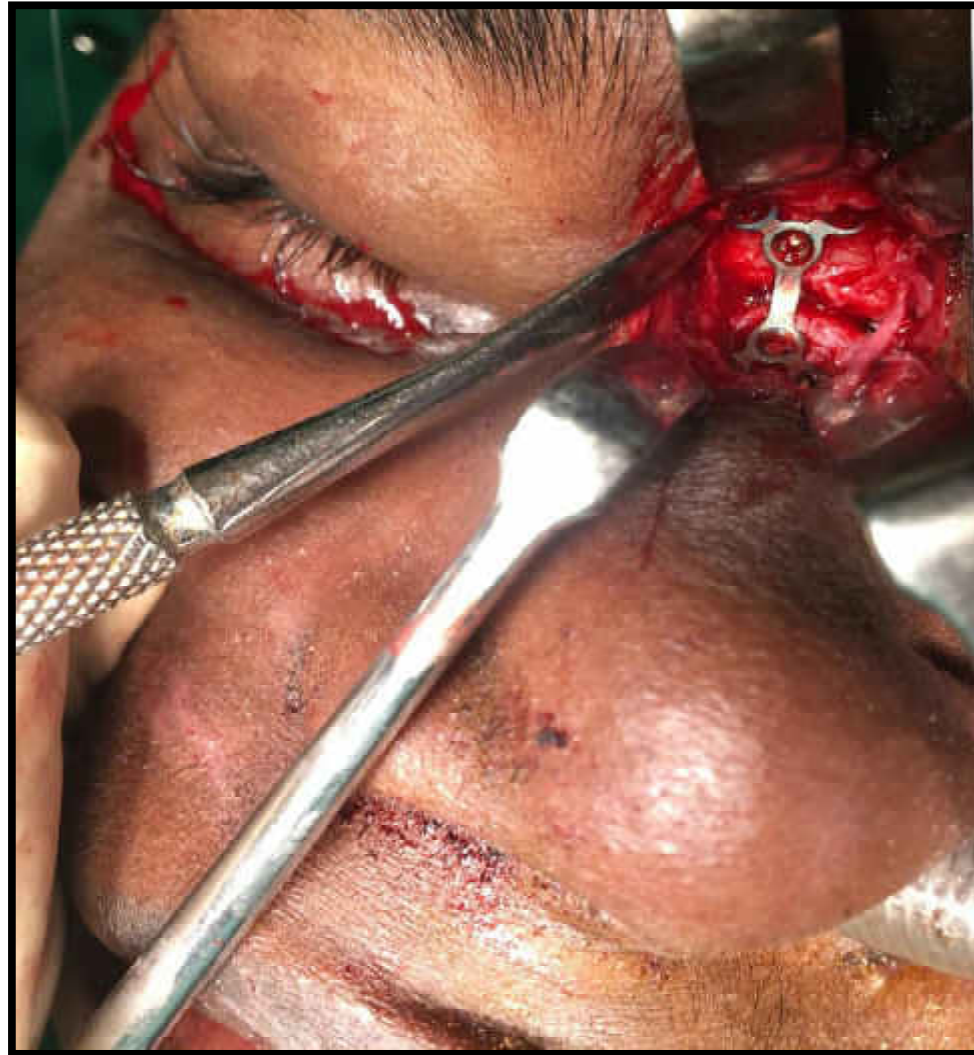## MAJOR SURGERIES



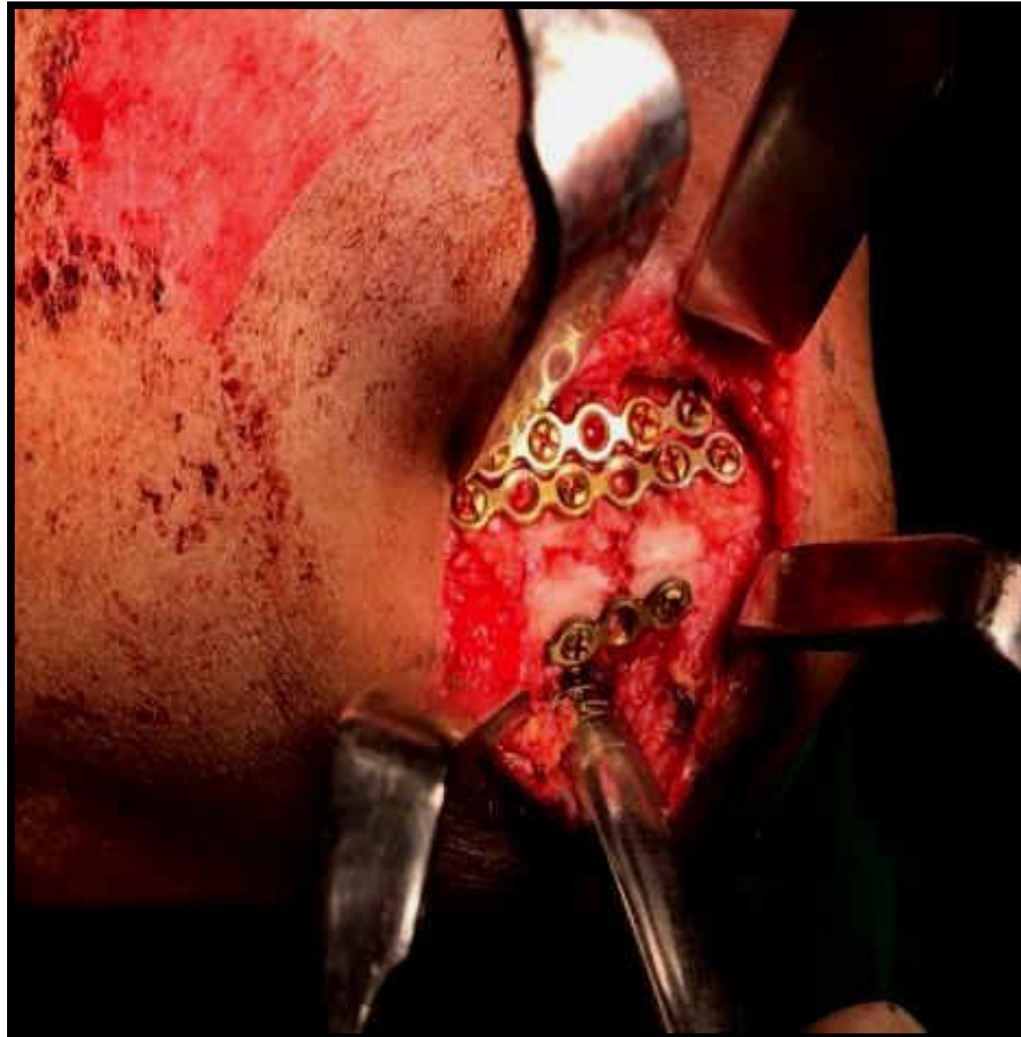## ORBITAL FLOOR RECONSTRUCTION



## NASAL BRIDGE RECONSTRUCTION

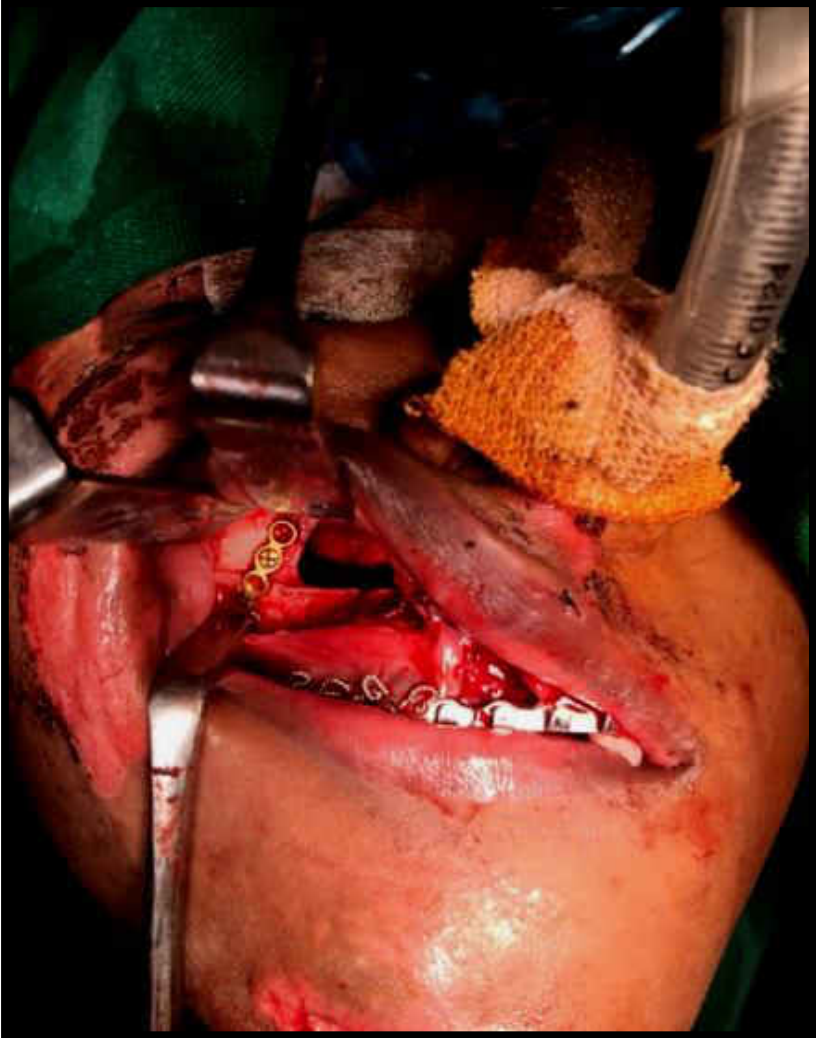

## PARASYMPHYSIS FRACTURE

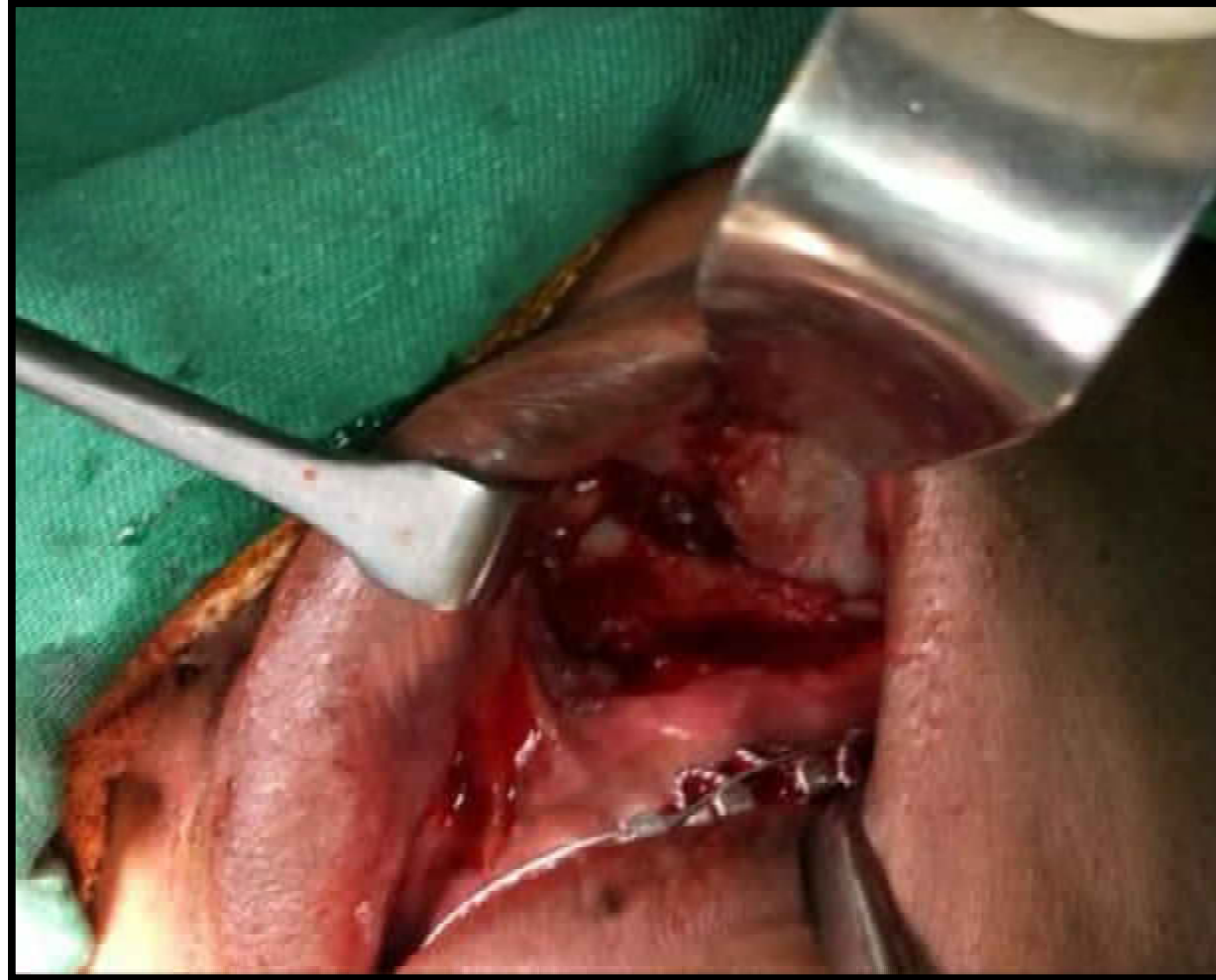



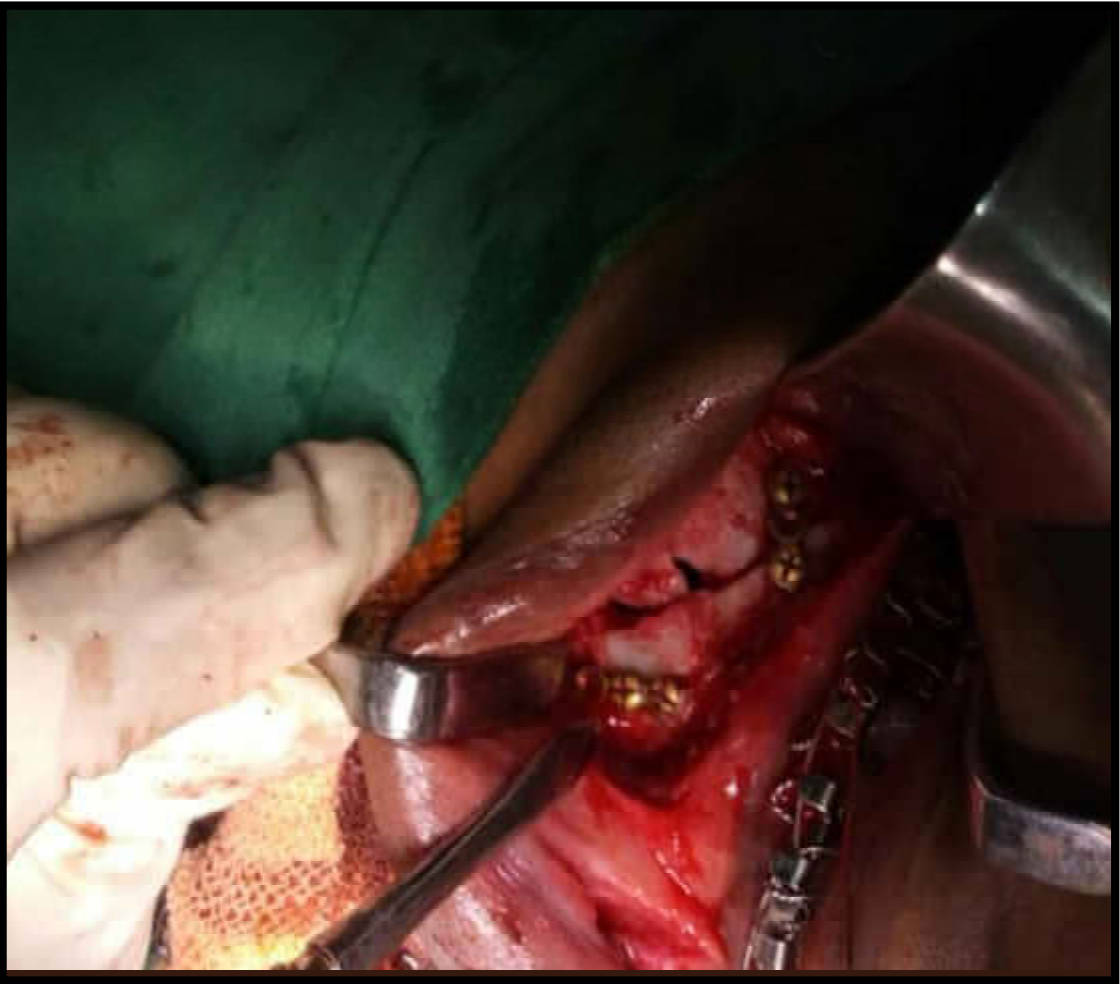**LEFORT 1 FRACTURE**



## LEFORT 1 FRACTURE

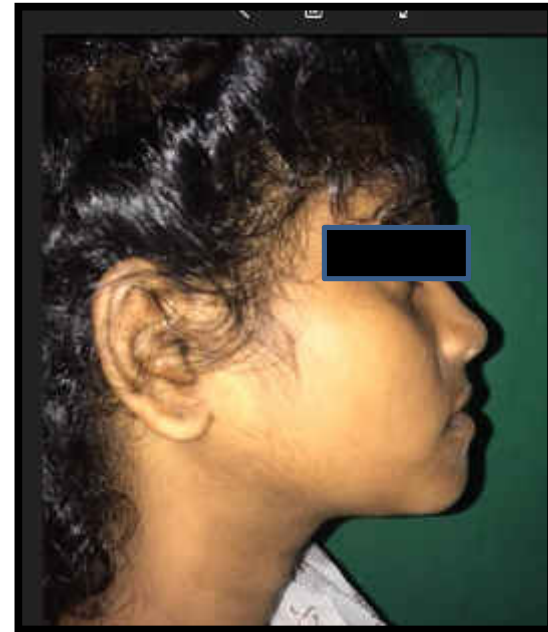
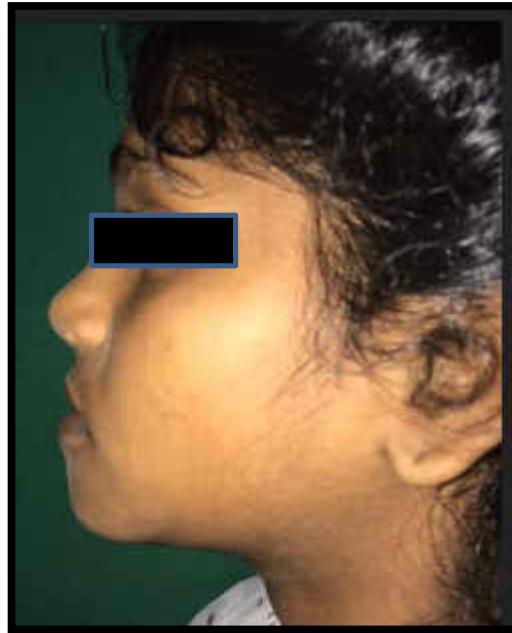
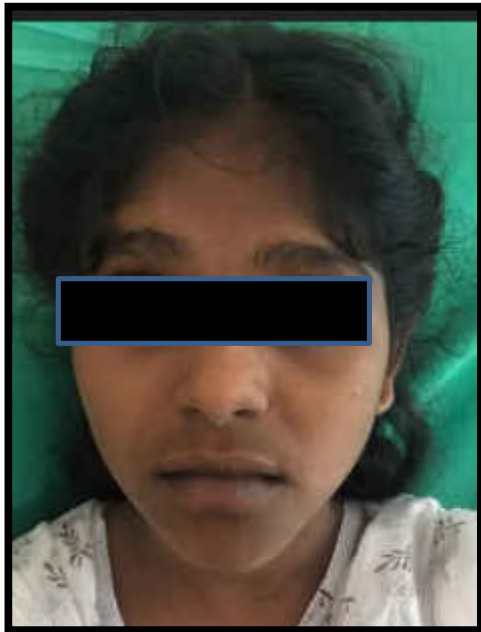

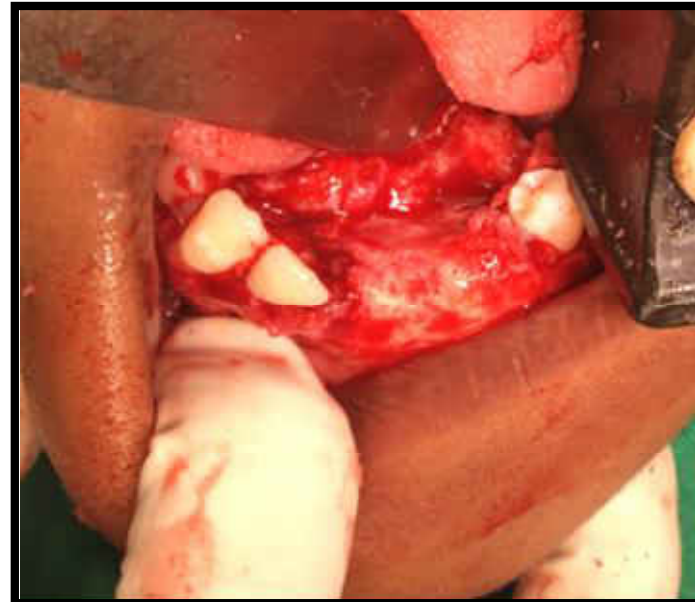
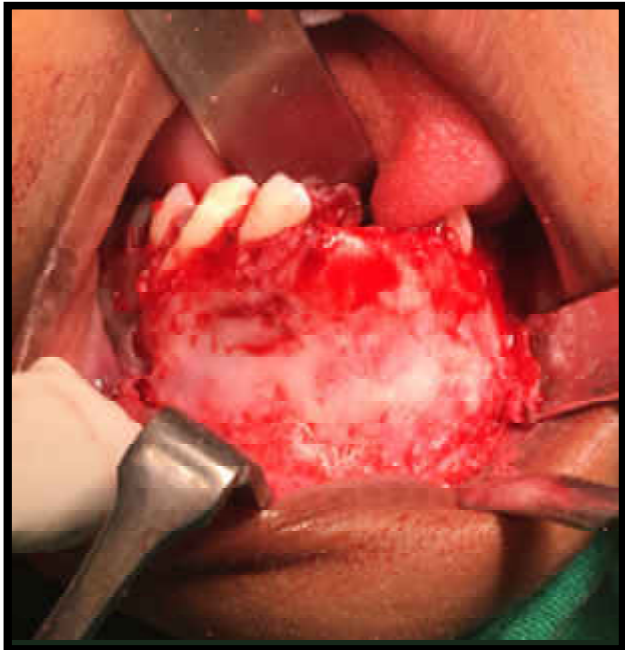
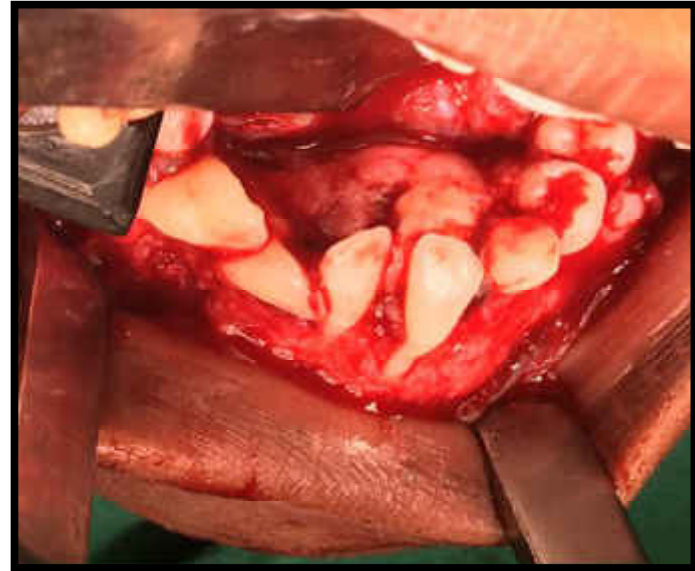
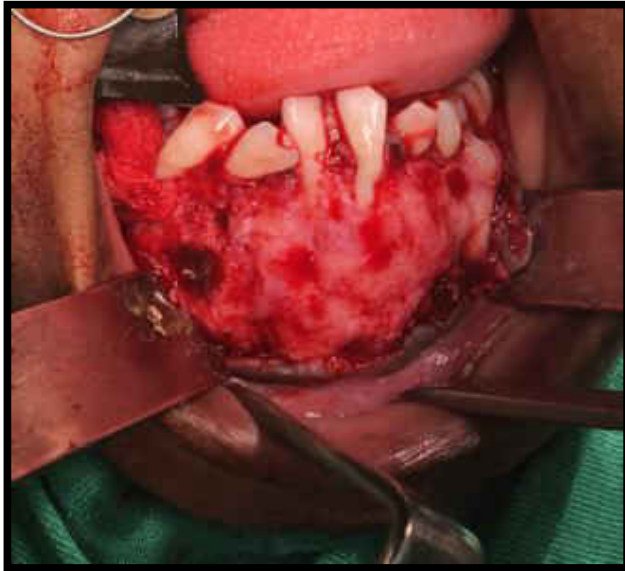


# FIBROUS DYSPLASIA

Pre operative

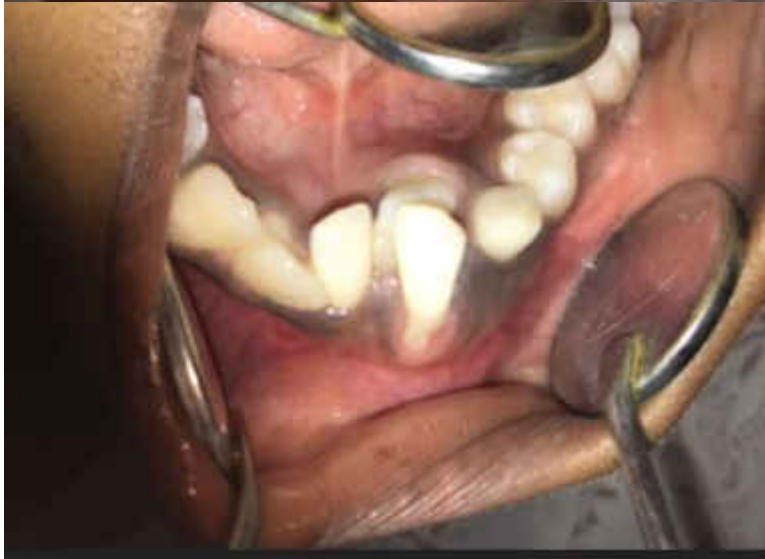
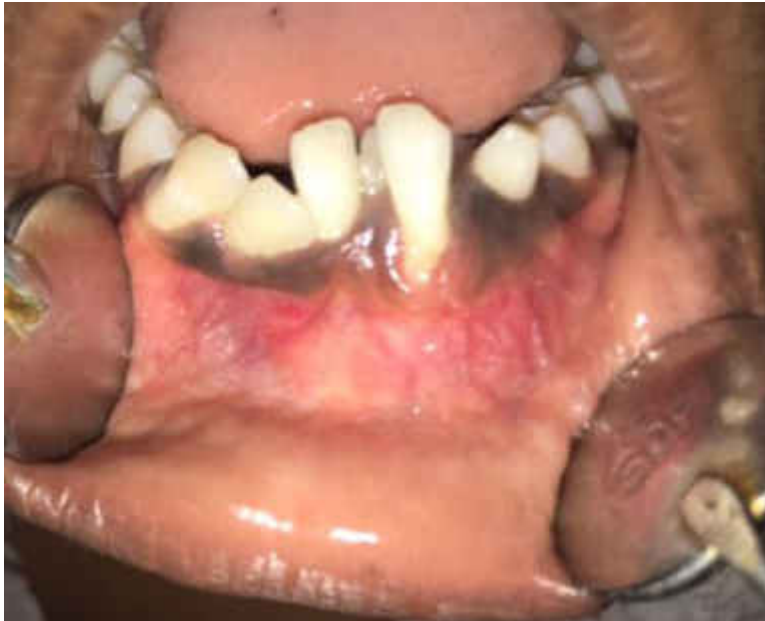
# Intraoperative

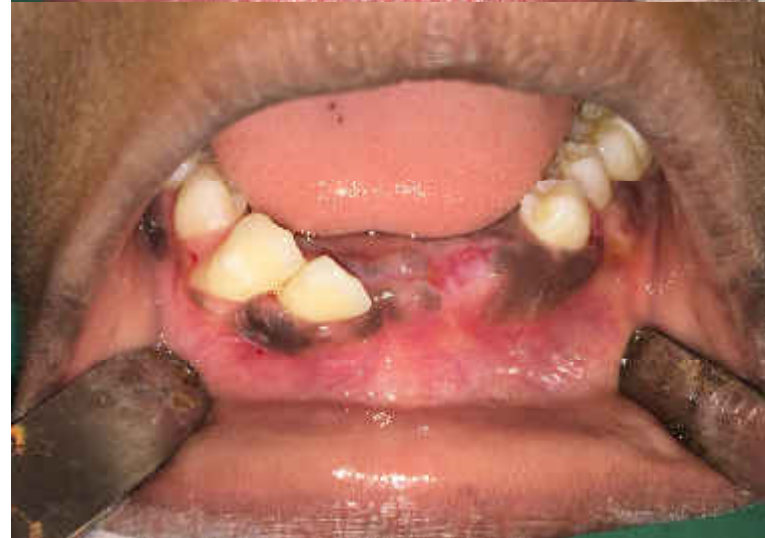
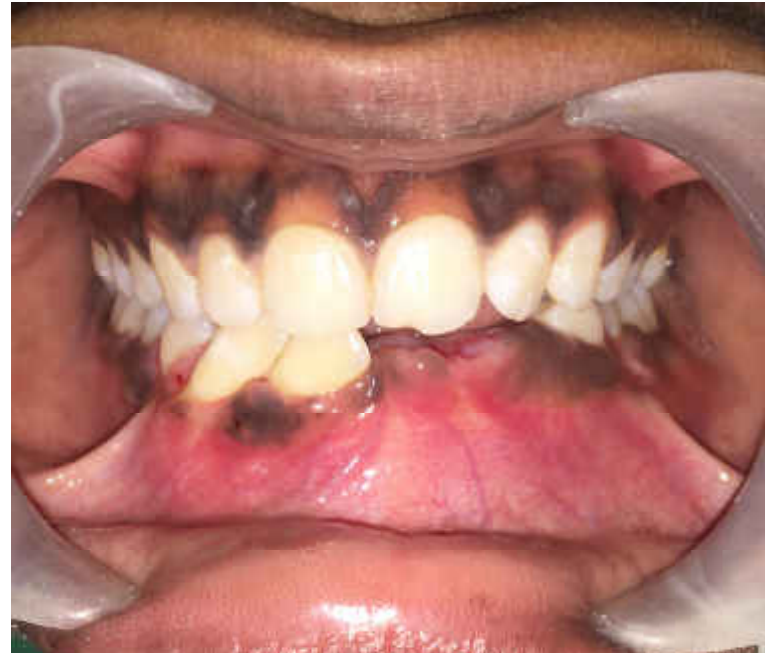
# Intraoral

preop



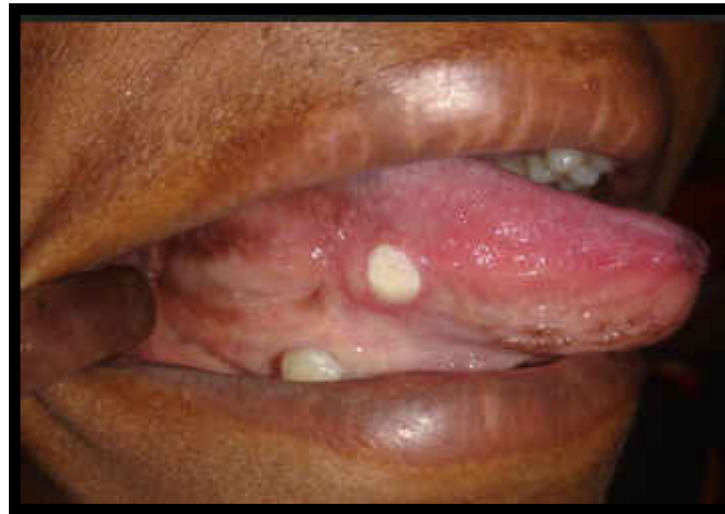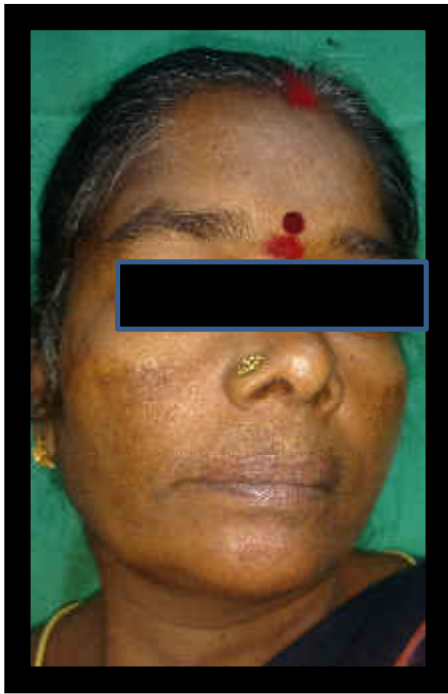postop



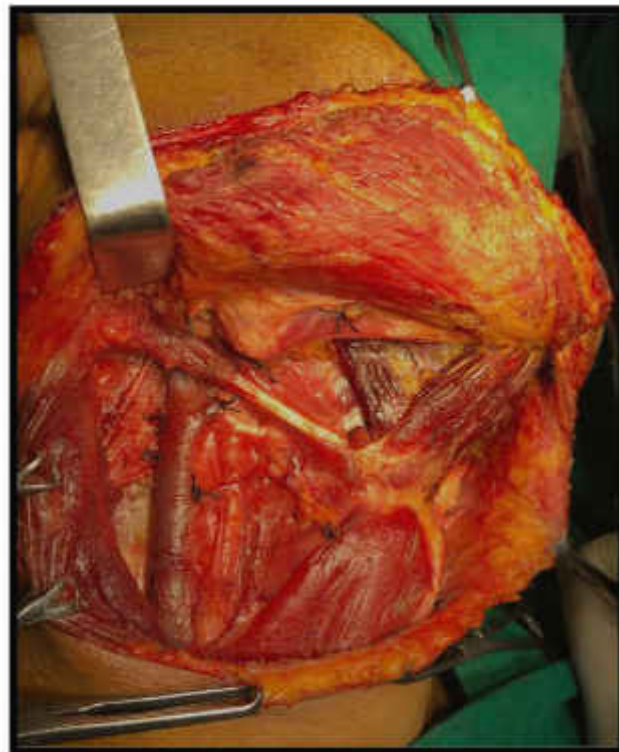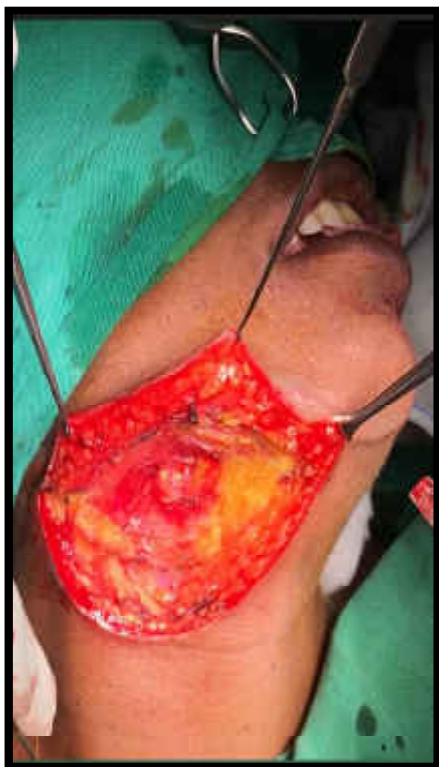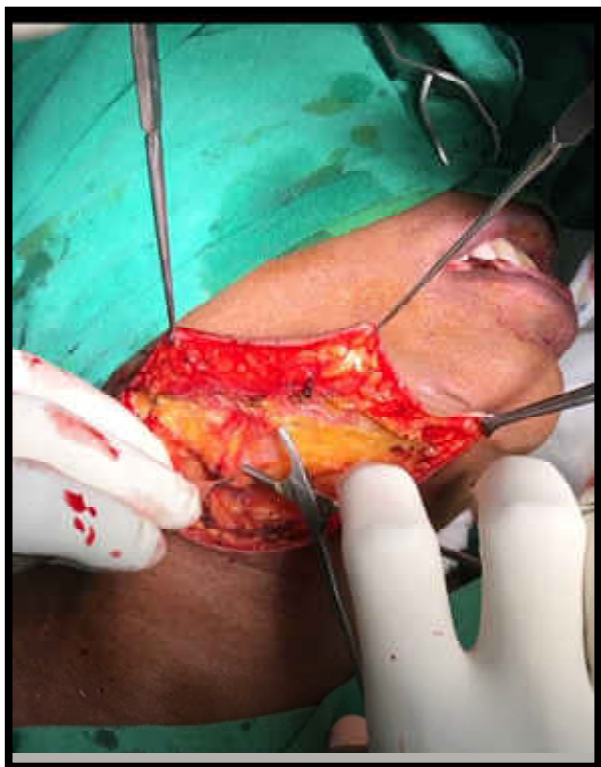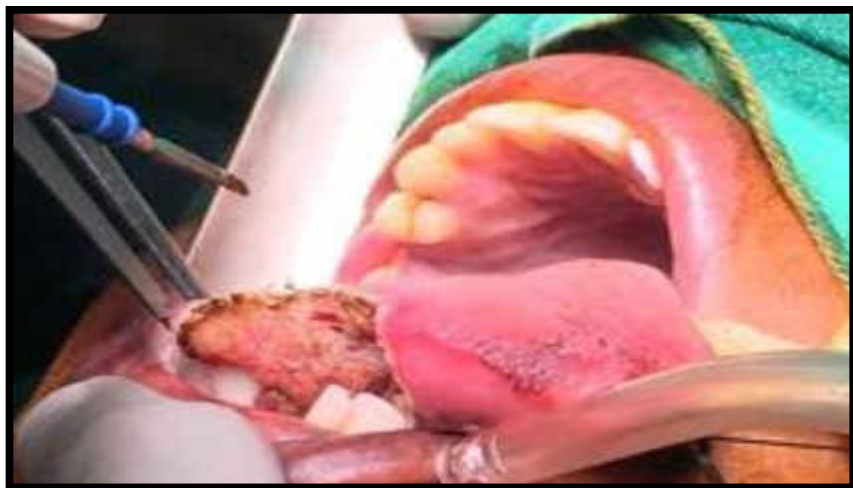


# SQUAMOUS CELL CARCINOMA OF TONGUE

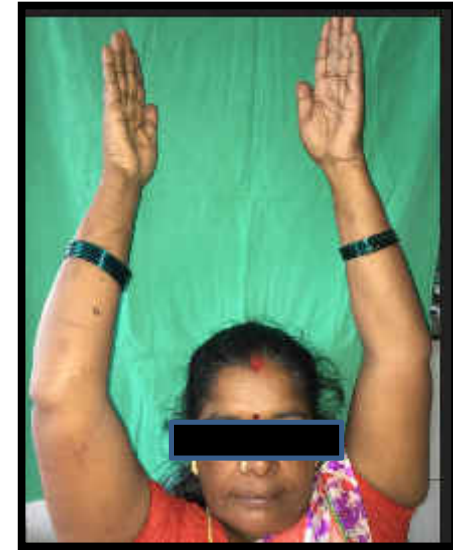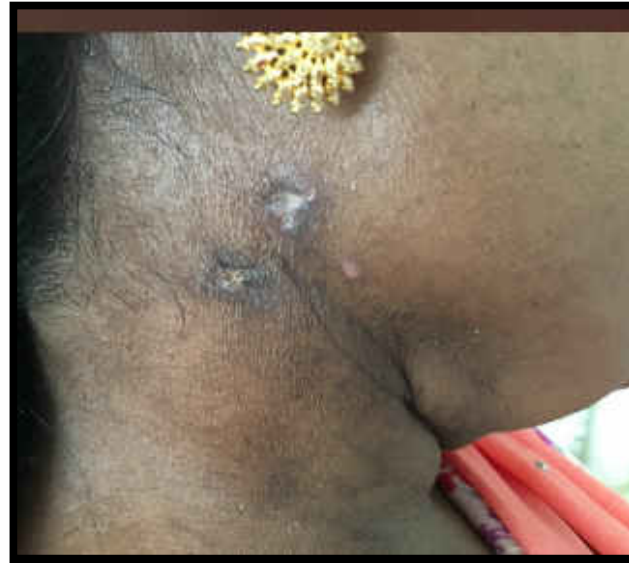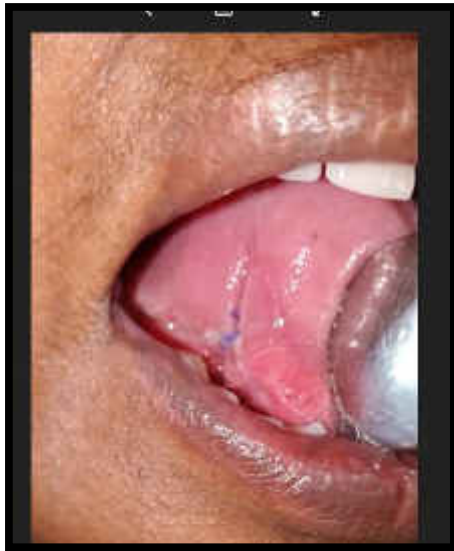
Pre operative





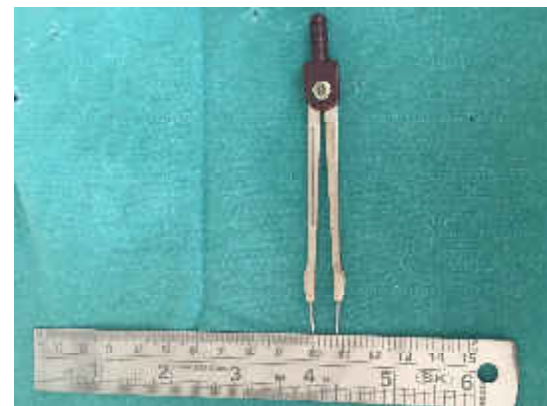
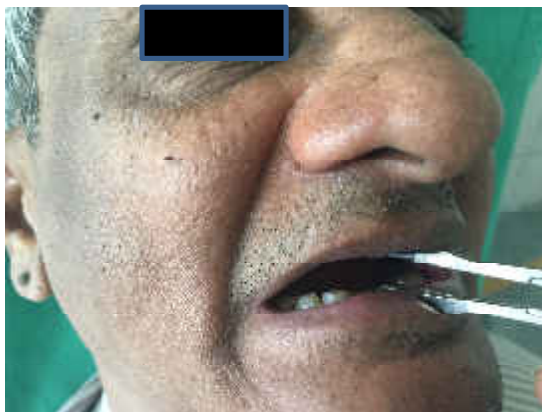
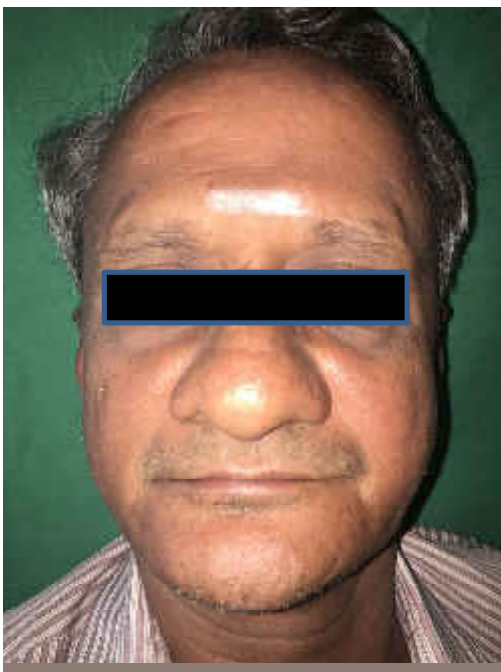## Postoperative

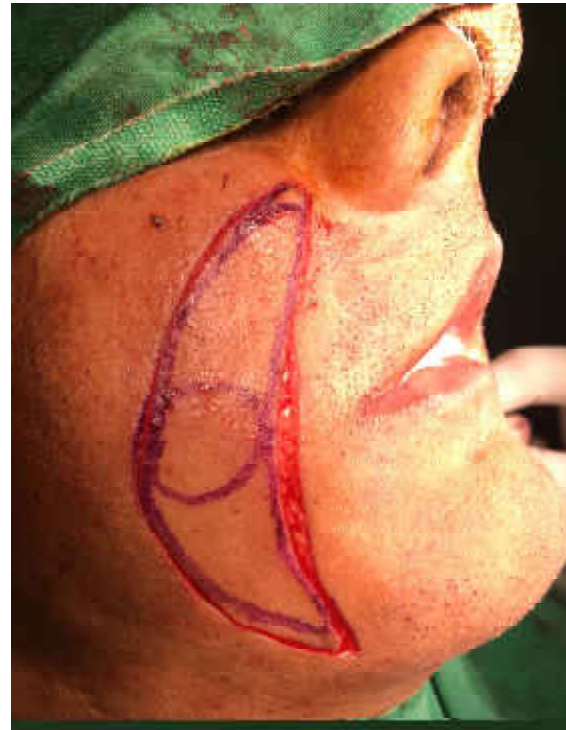
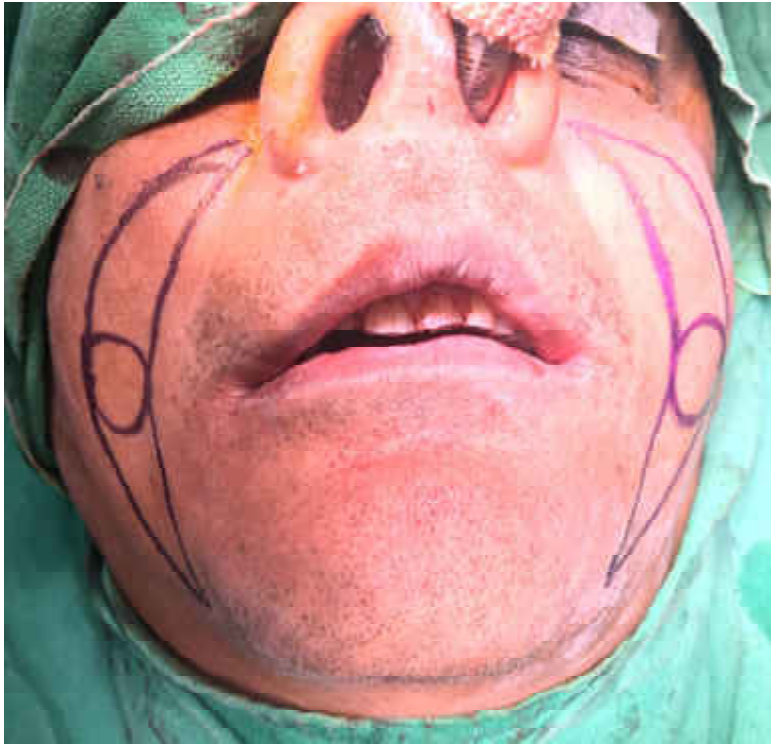
# ORAL SUBMUCOUS FIBROSIS

Pre operative

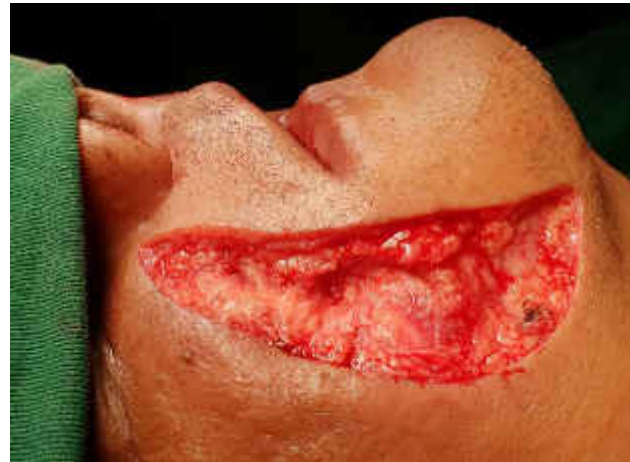
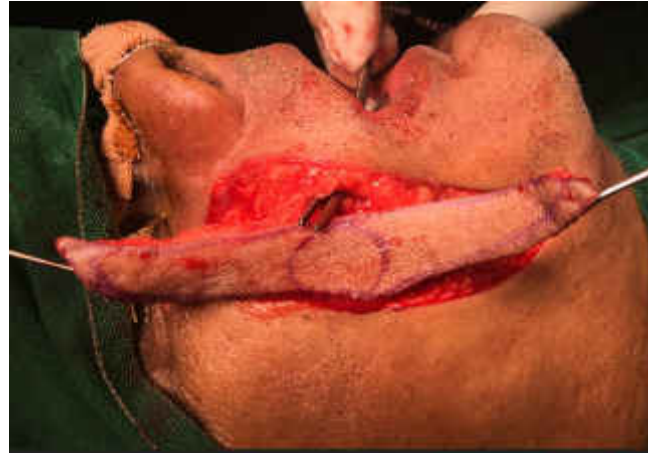
# Nasolabial flap



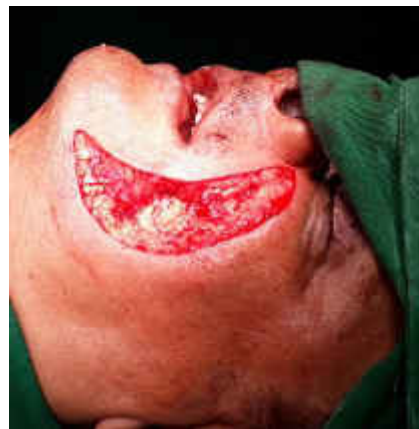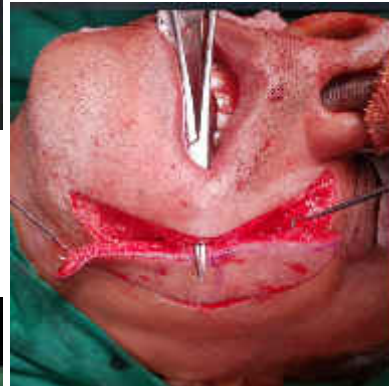

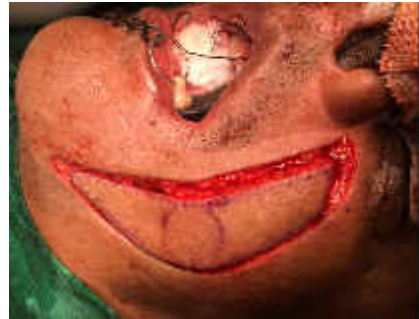
## Transbuccal tunneling

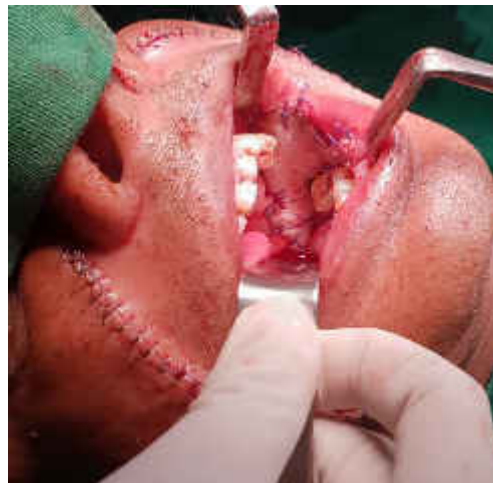
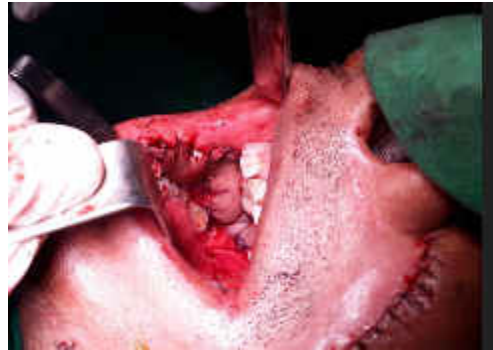


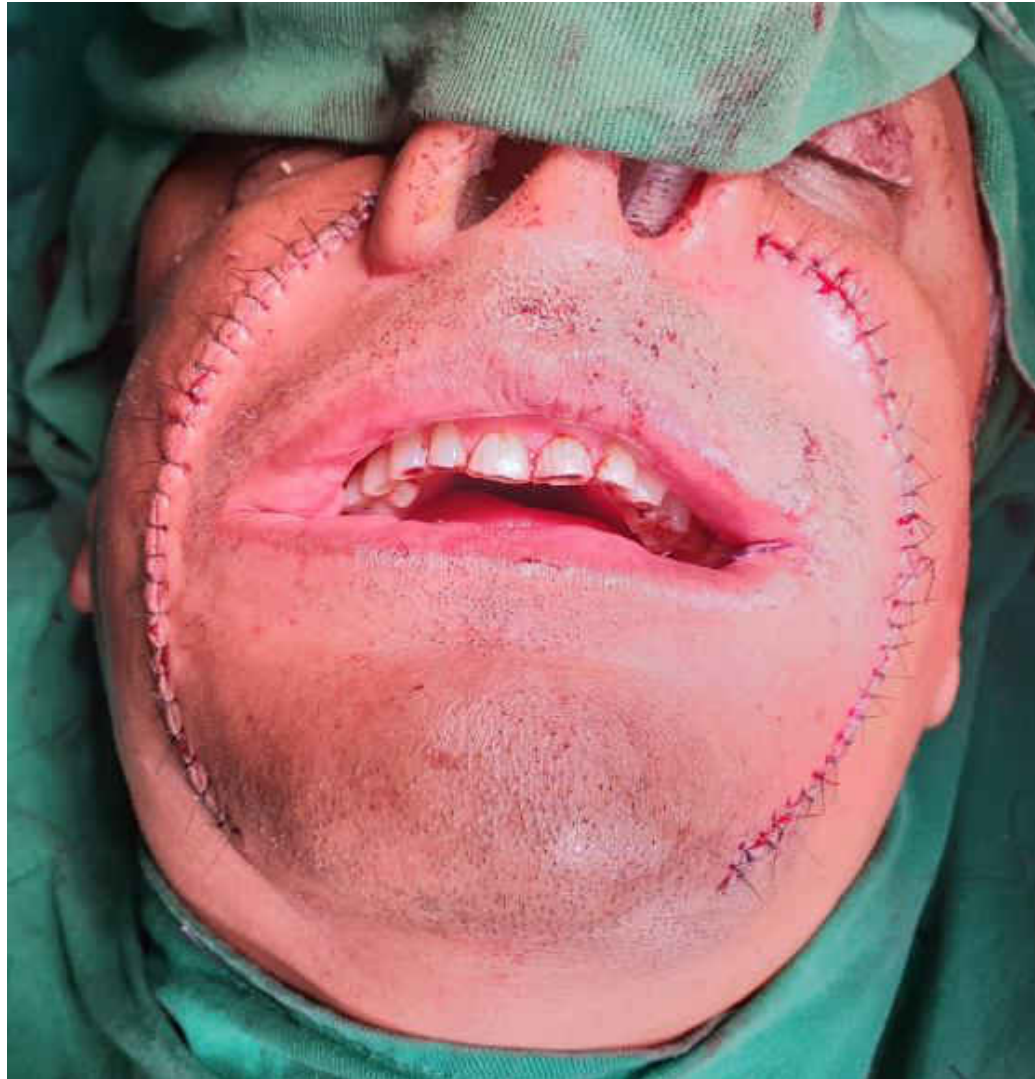## Nasolabial flap – Left side



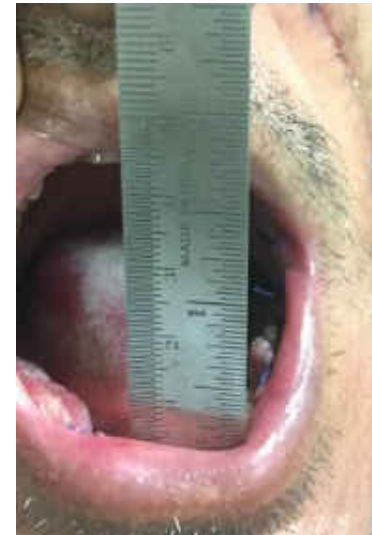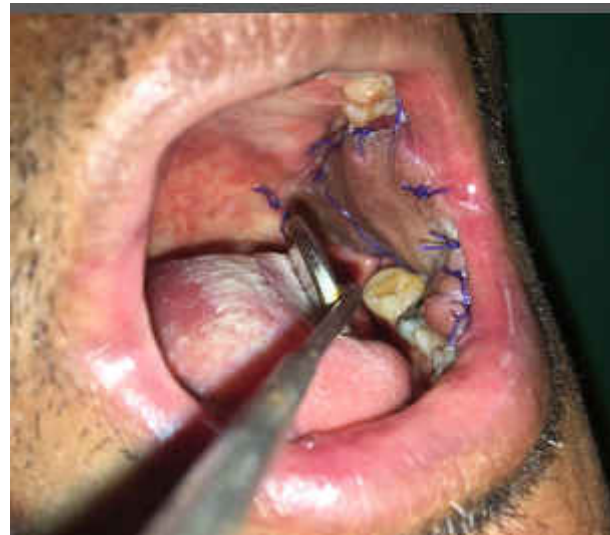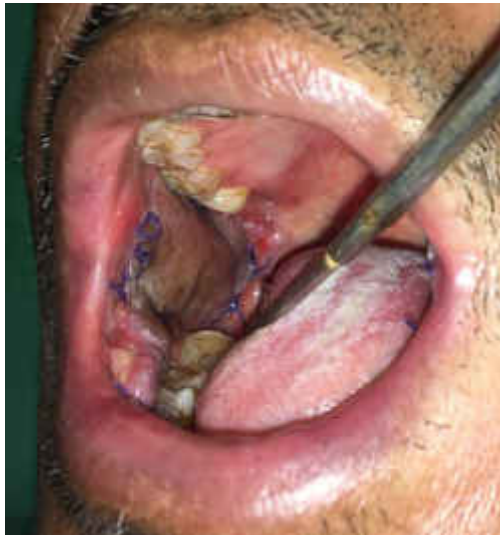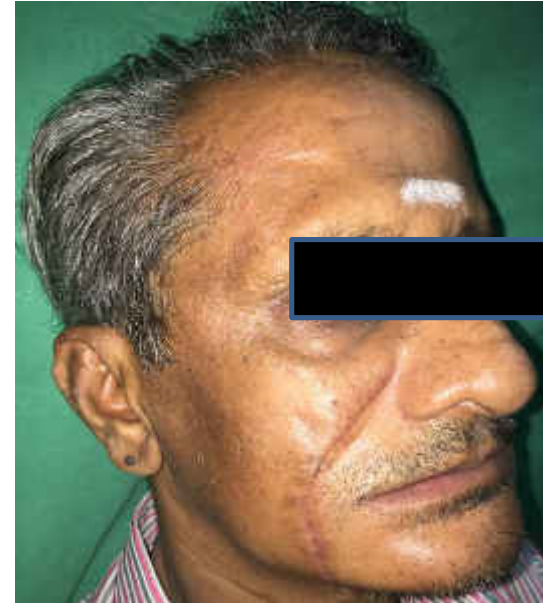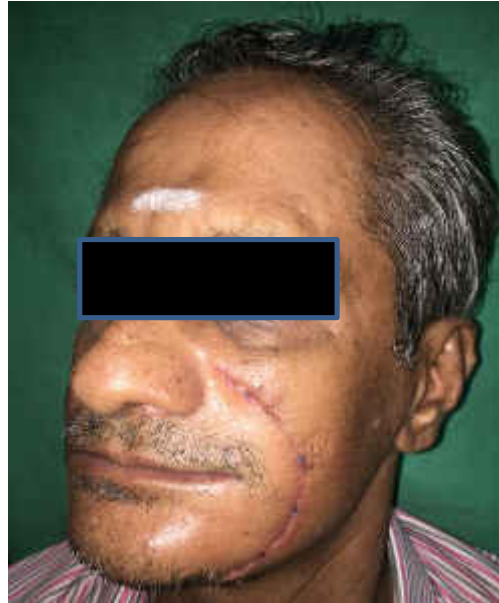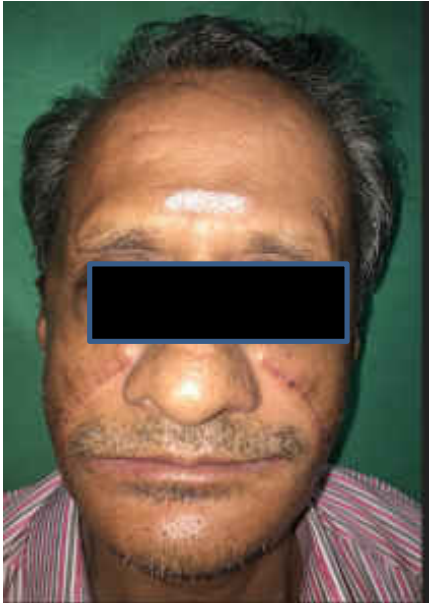# Reconstruction



## Closure of secondary defect

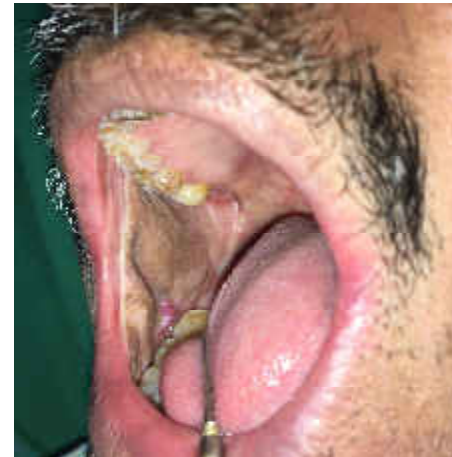
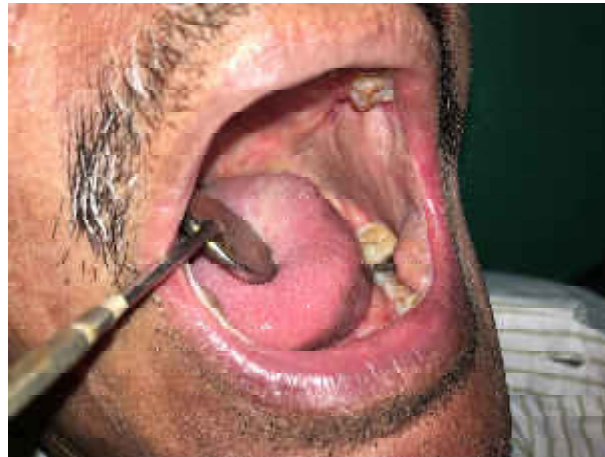
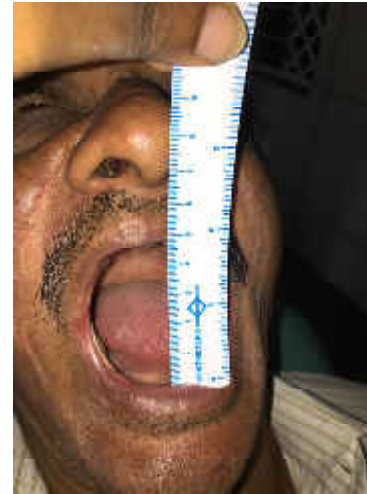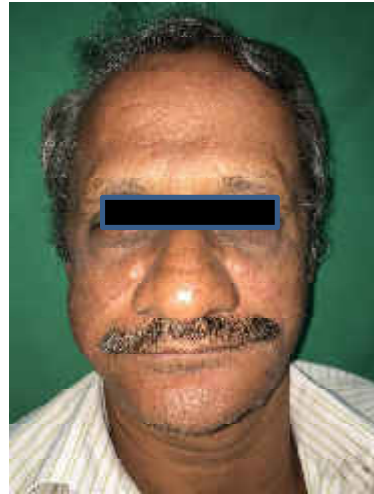Postoperative-3 weeks



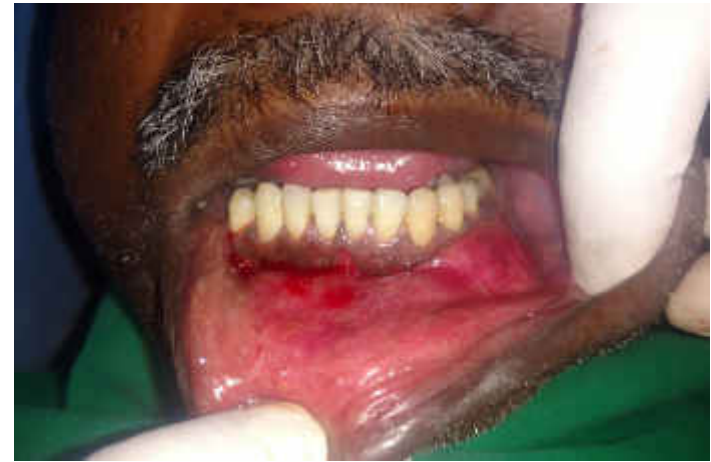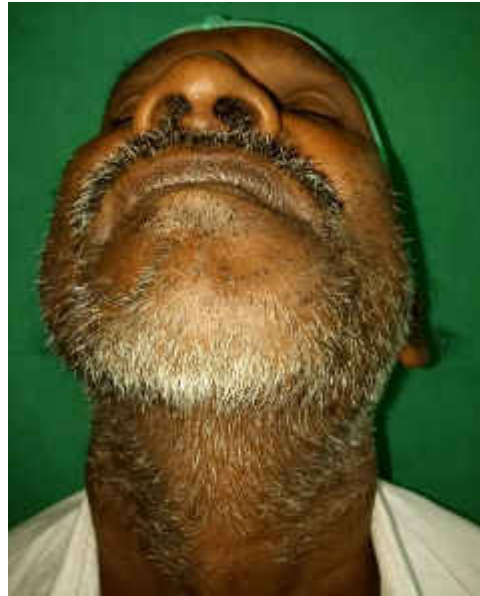

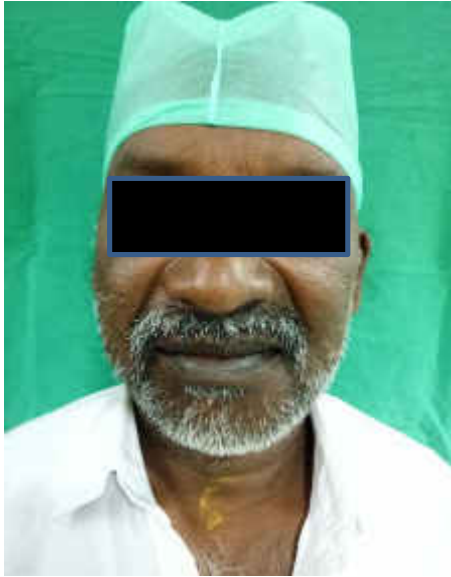
## Postoperative-5 MONTHS

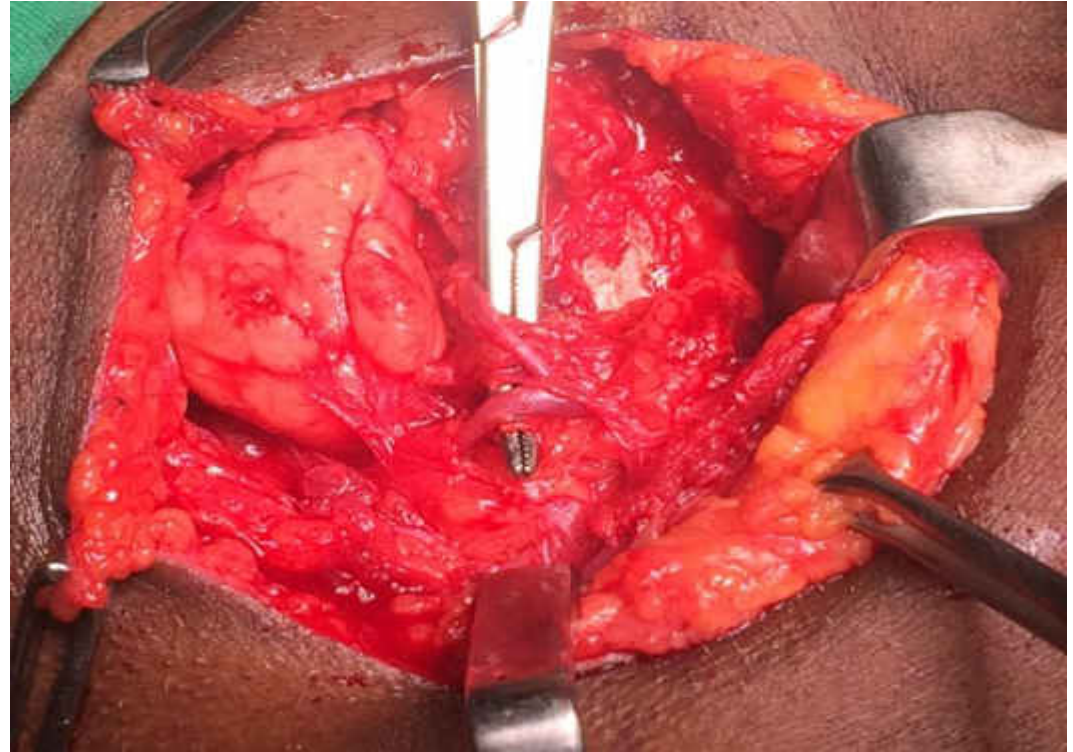
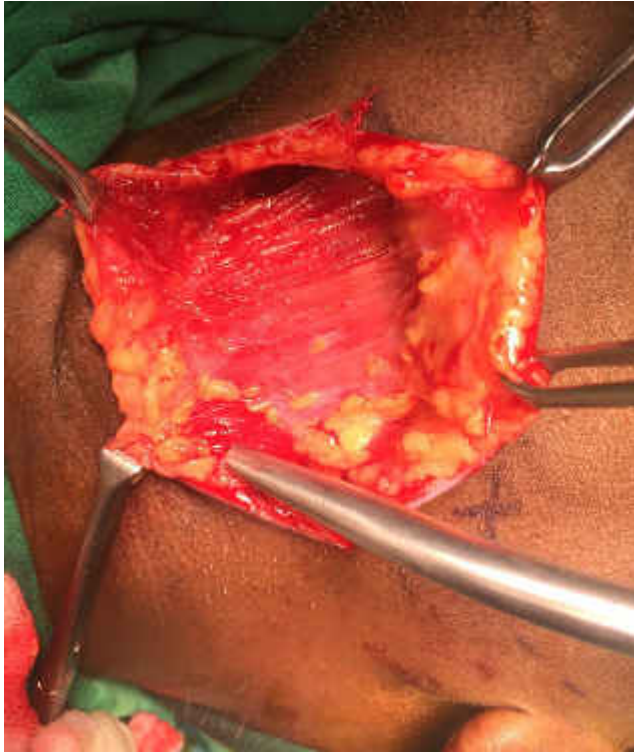


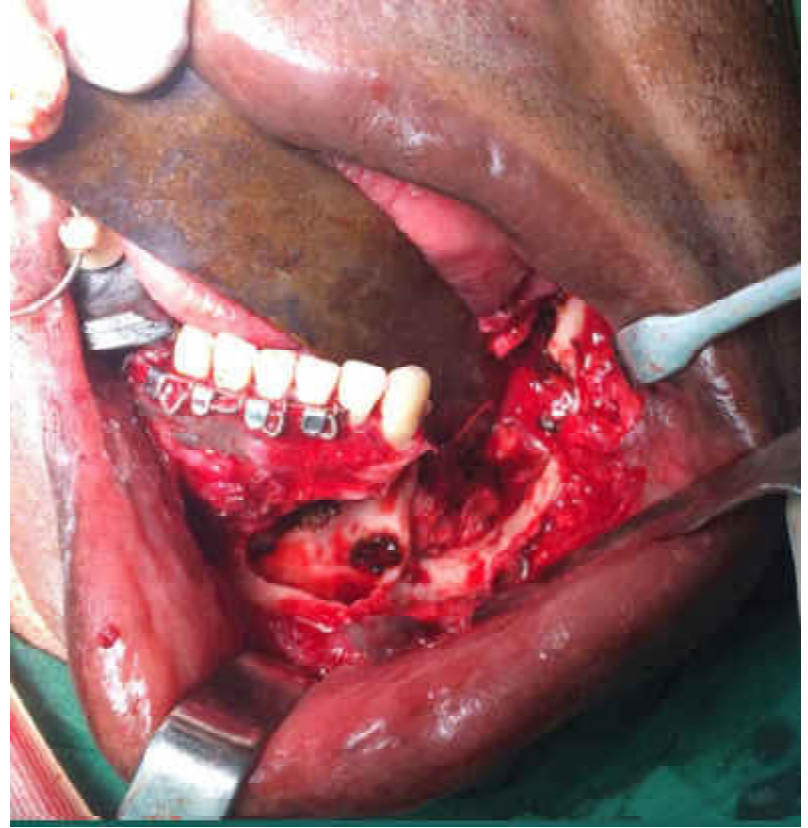
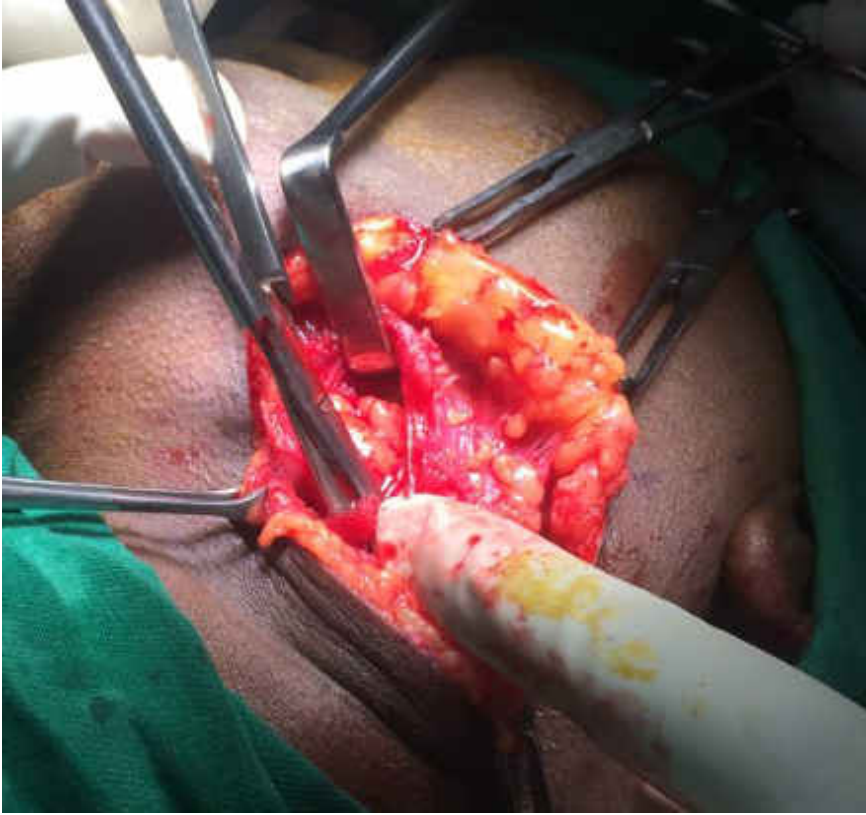


## Preoperative



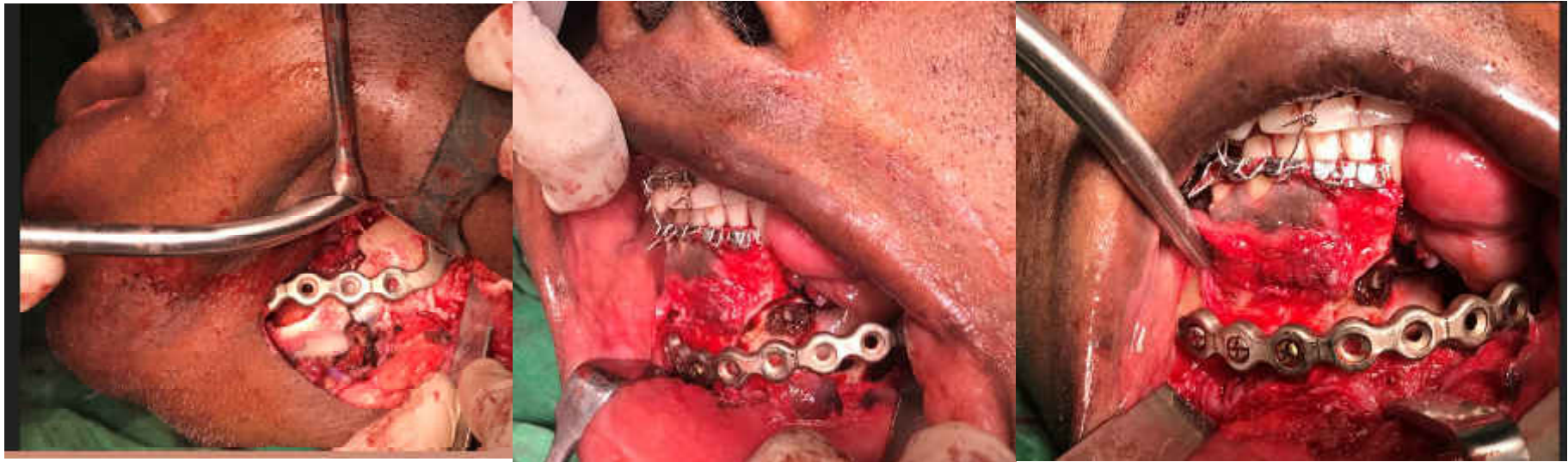# Intraoperative



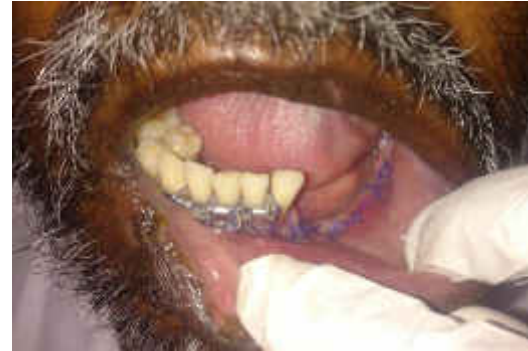
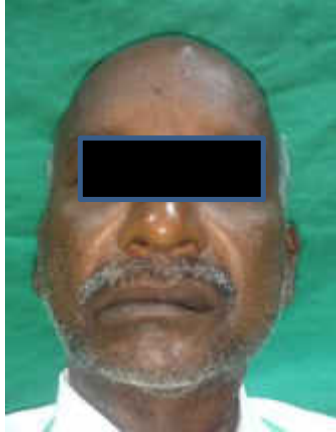


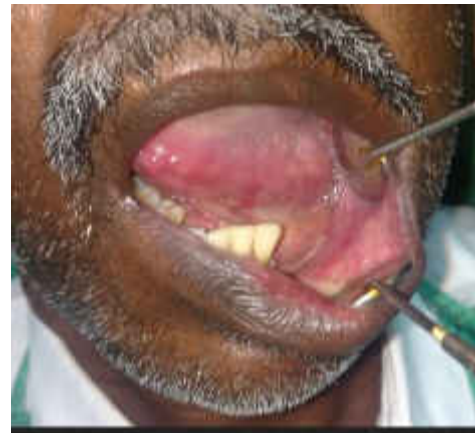# Reconstruction



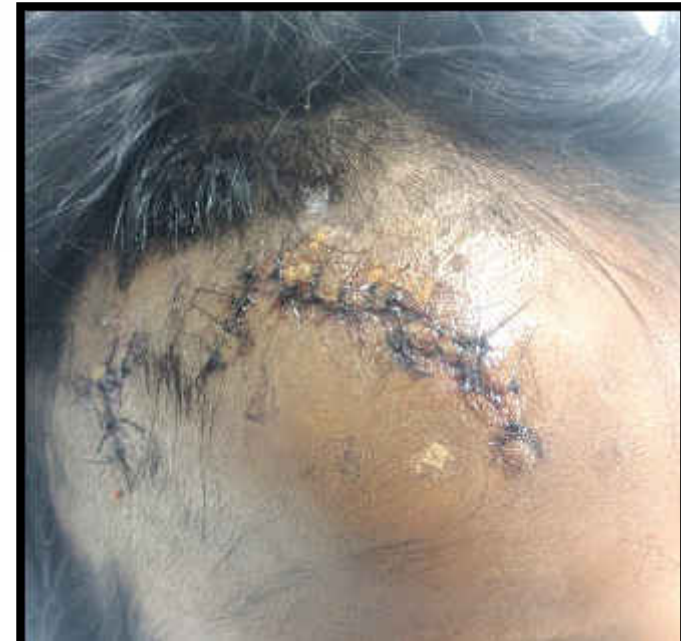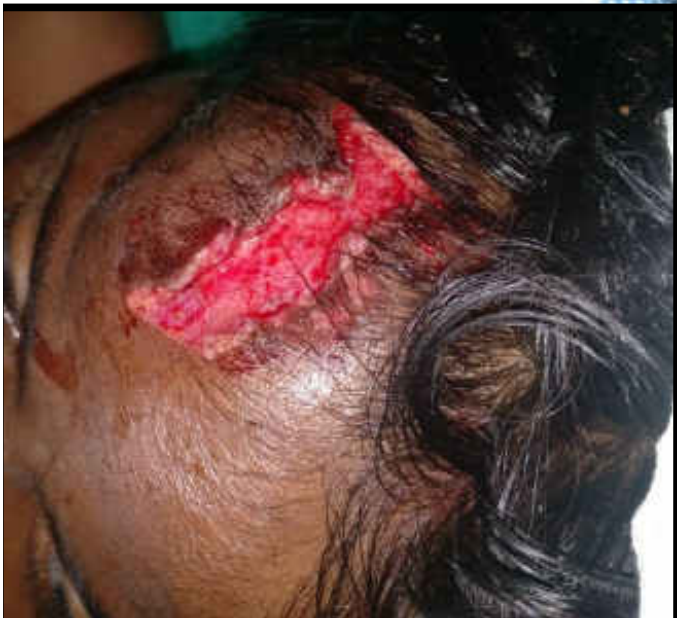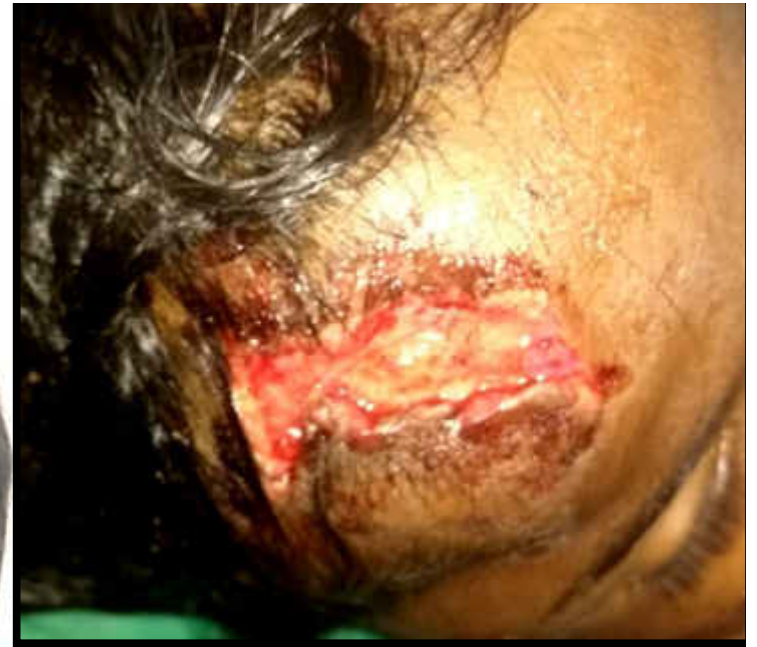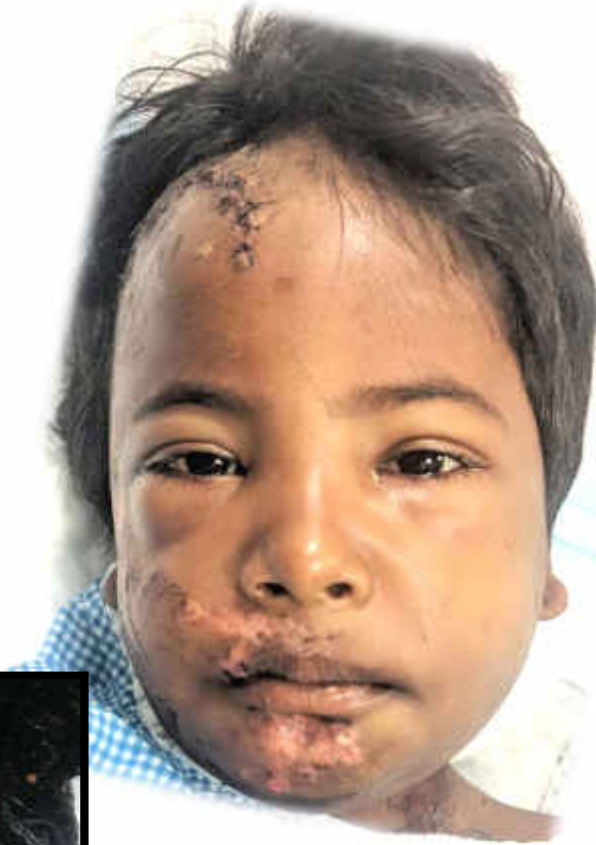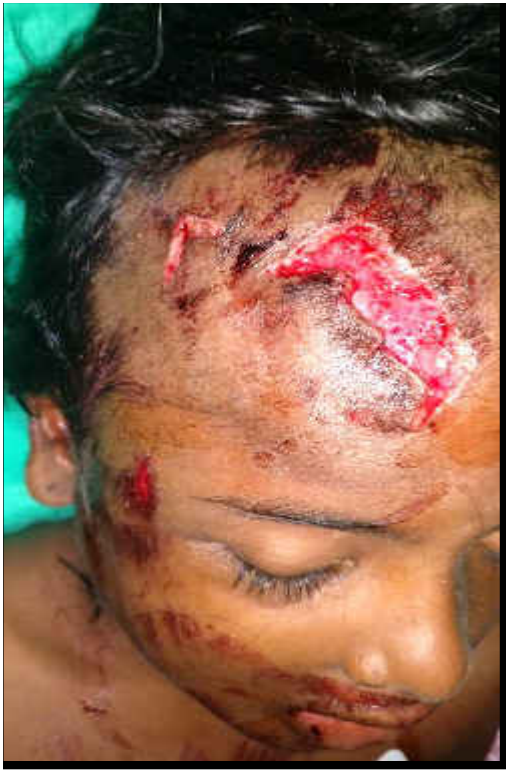## Postoperative

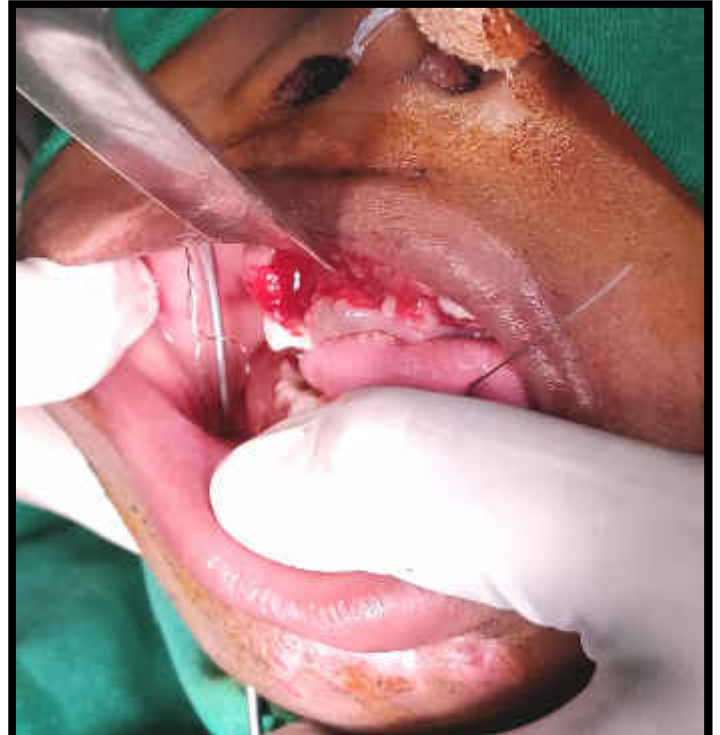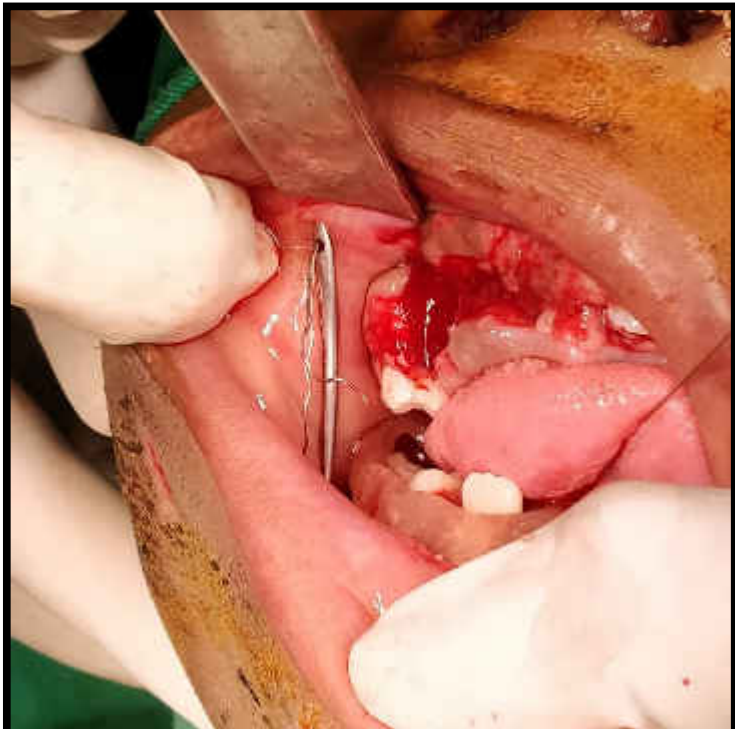
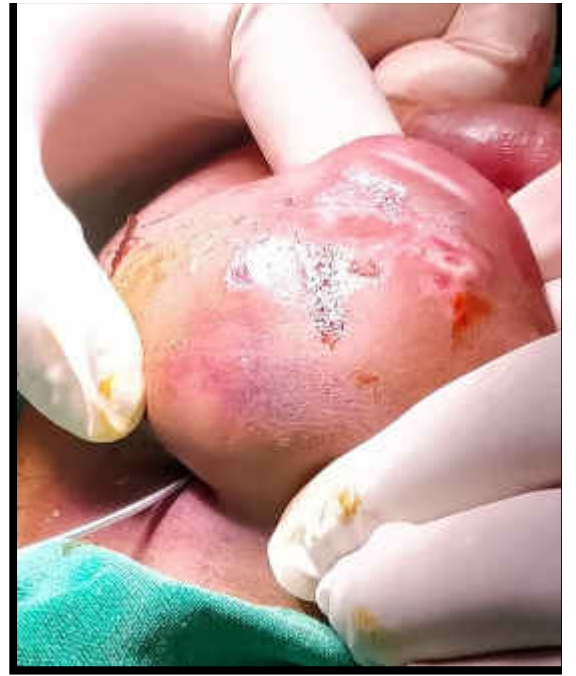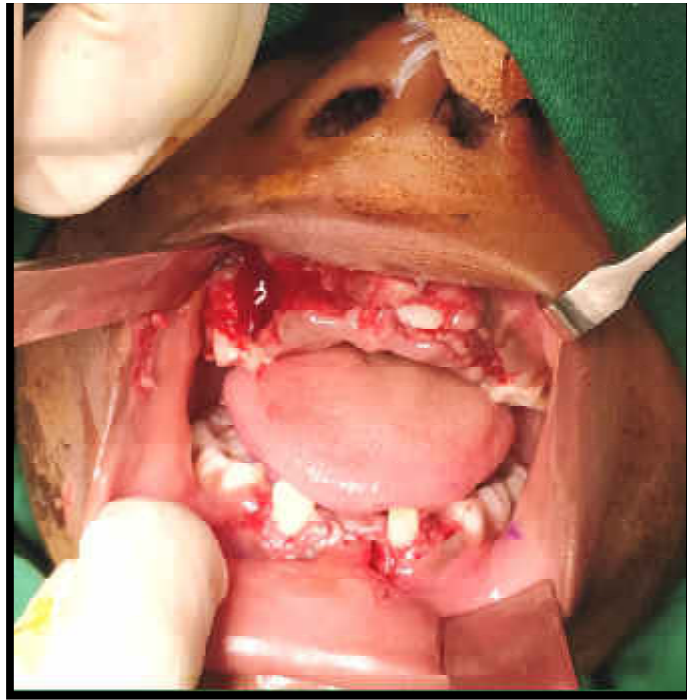


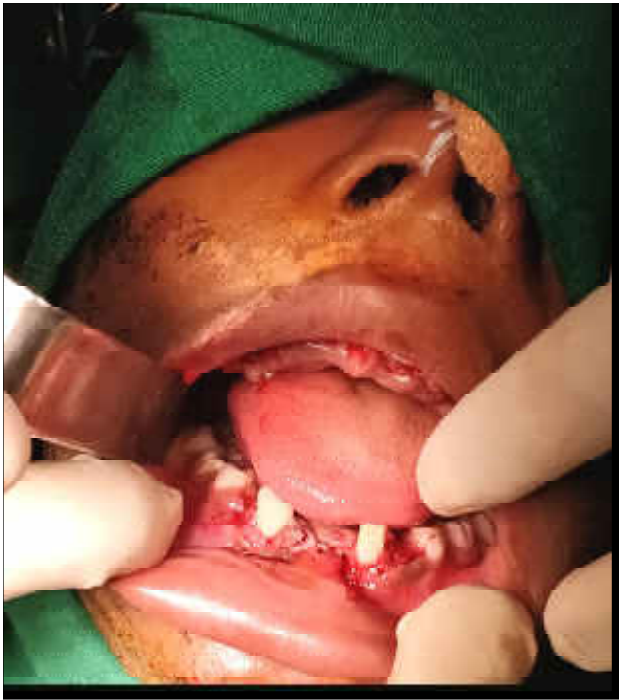## Postoperative - 3MONTHS

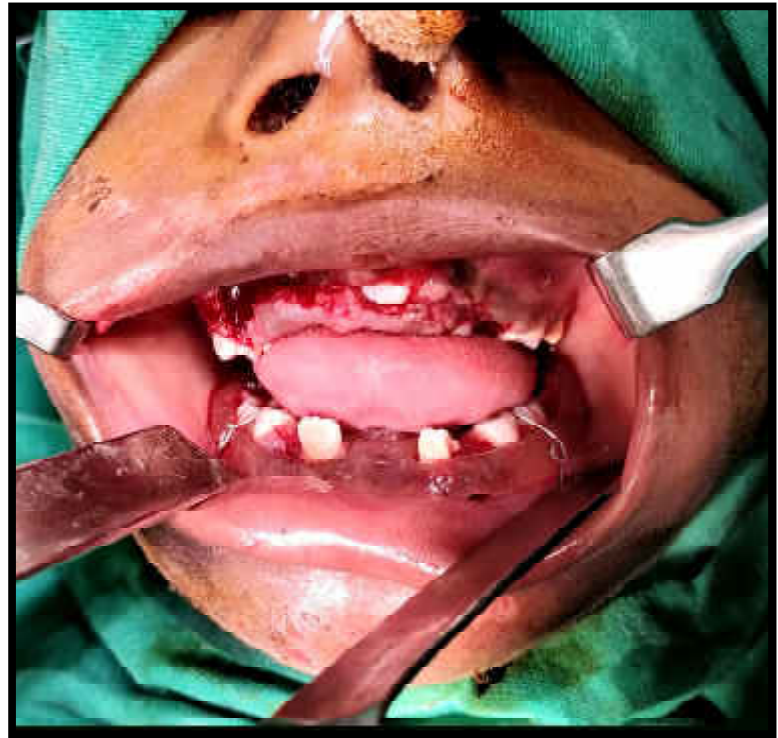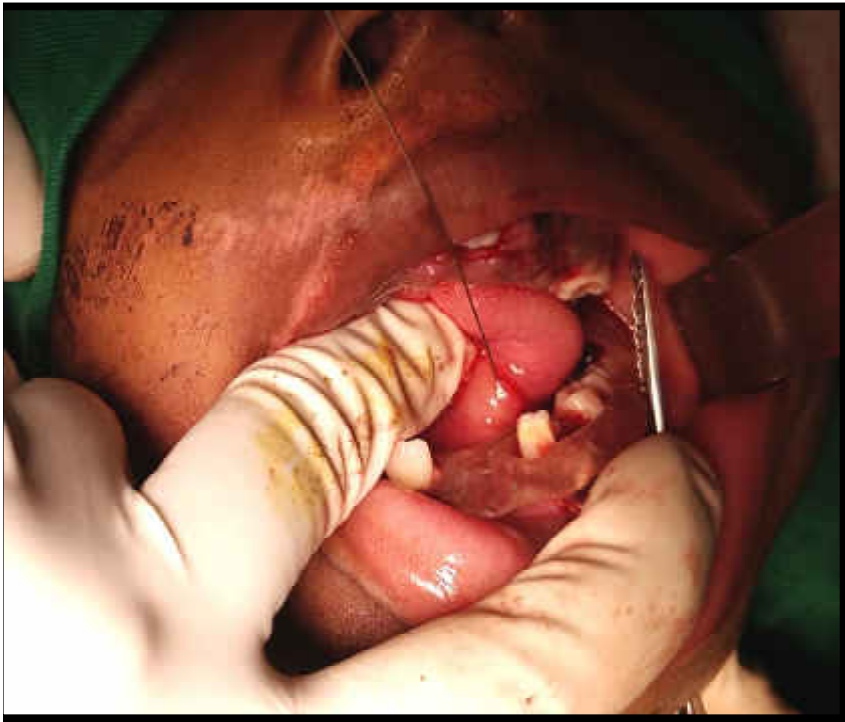

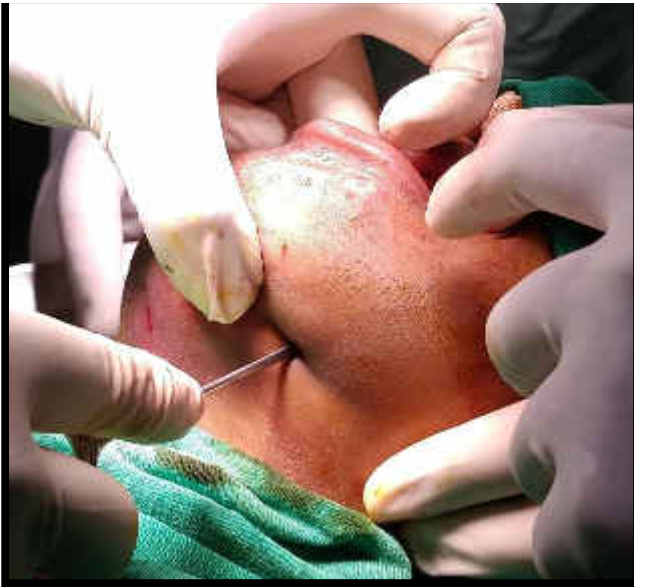
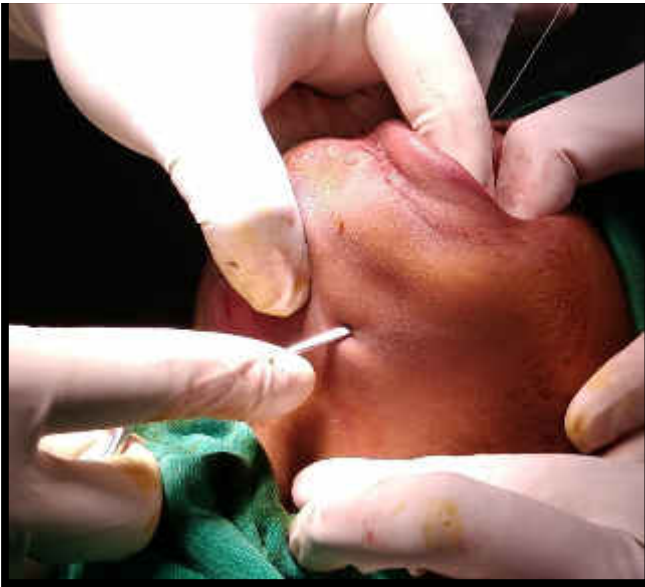
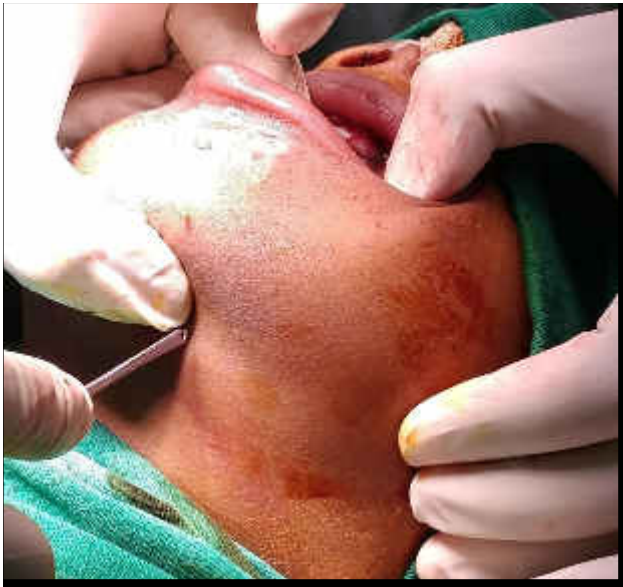


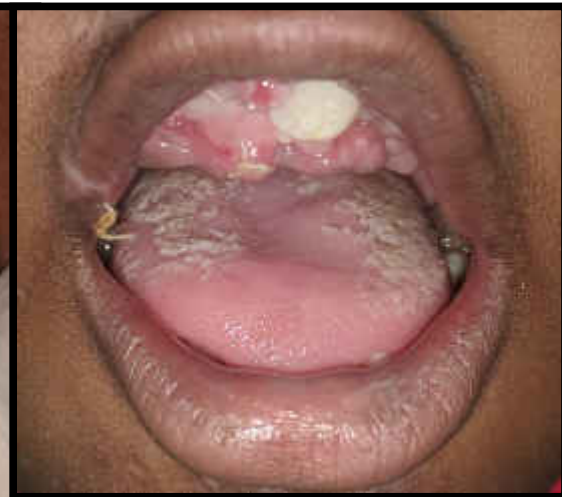
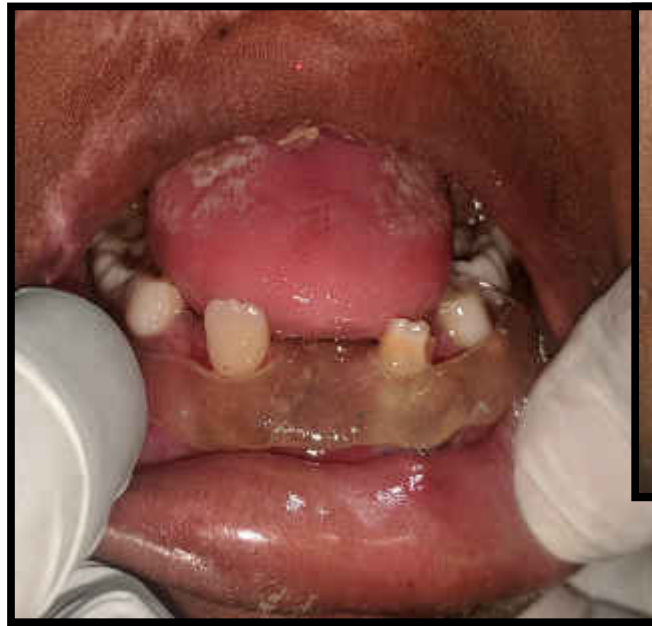
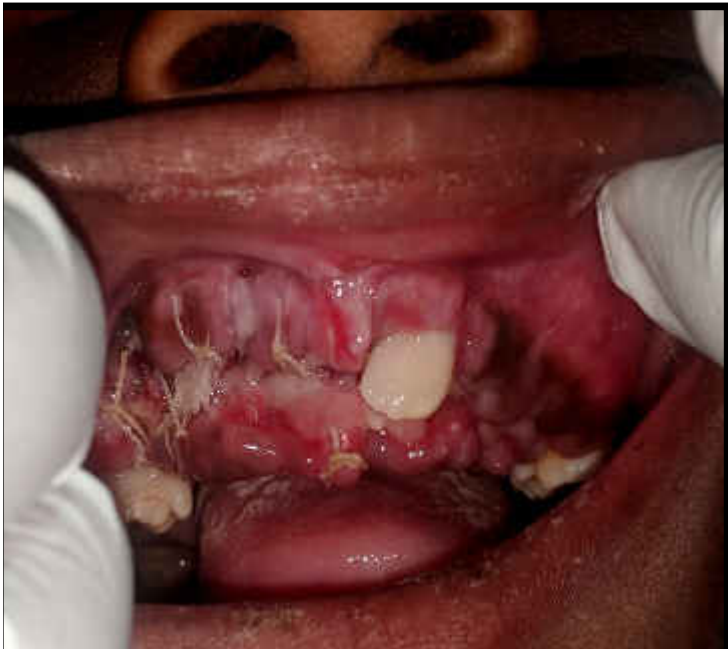
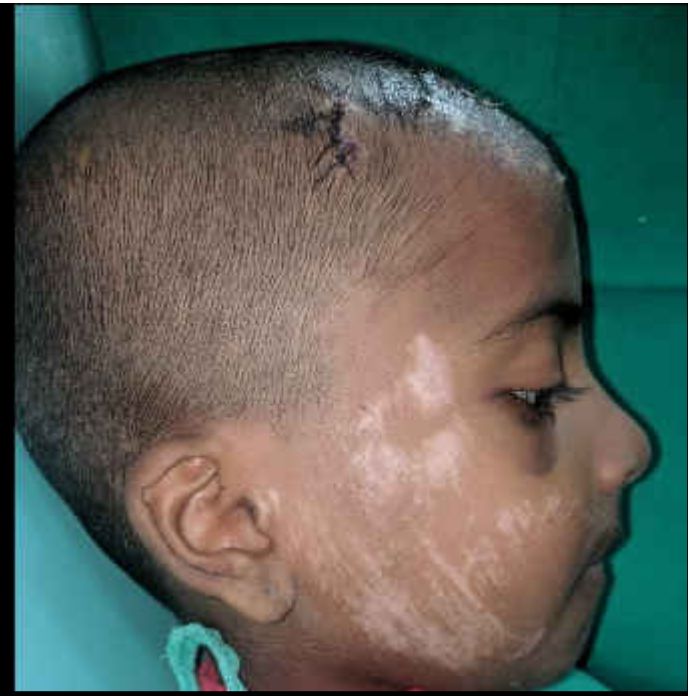
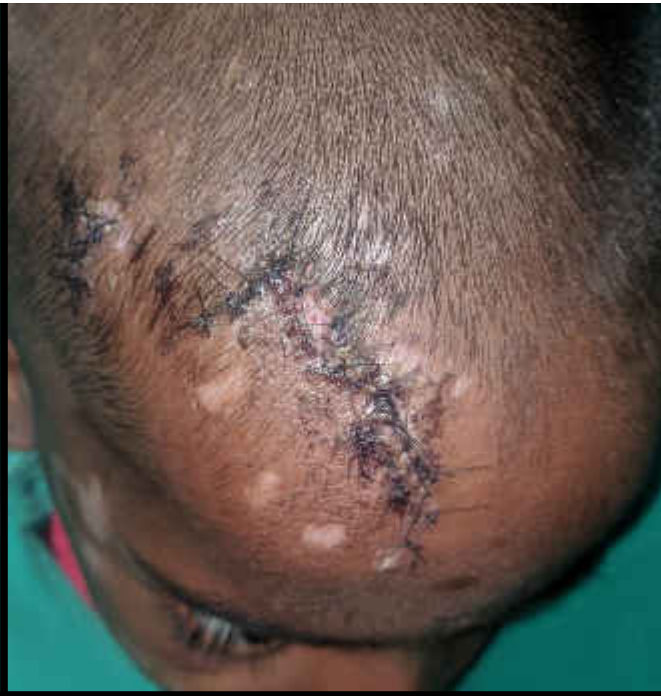
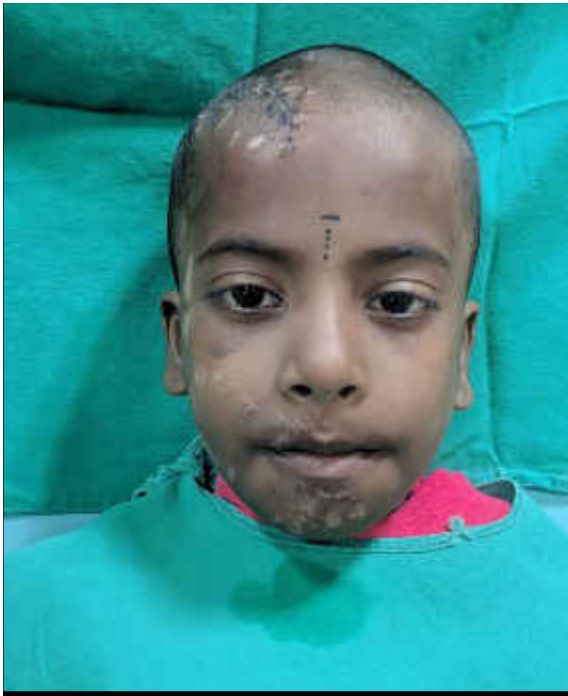




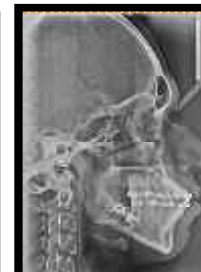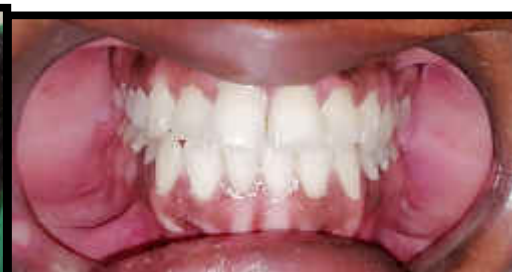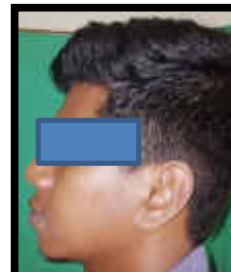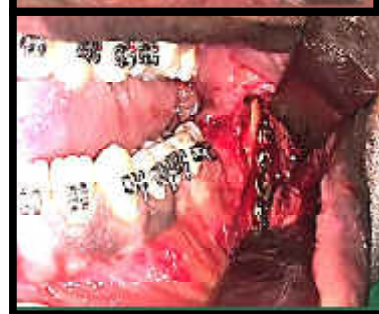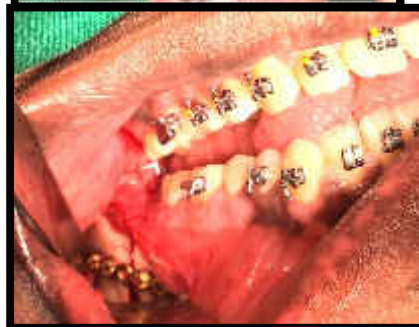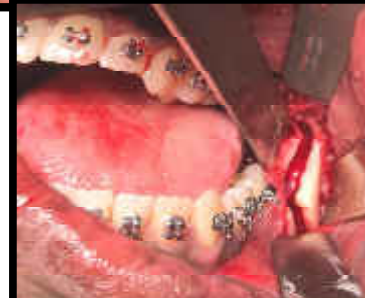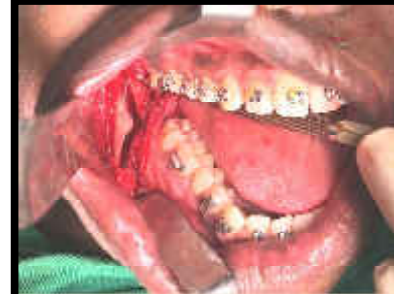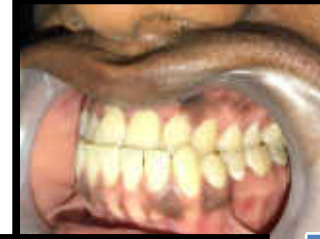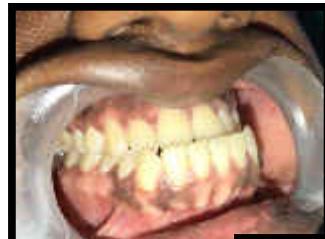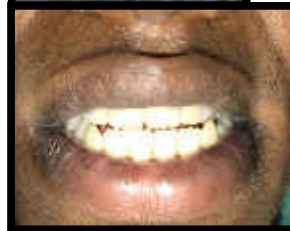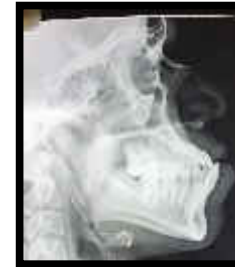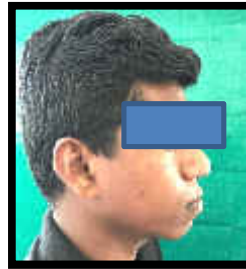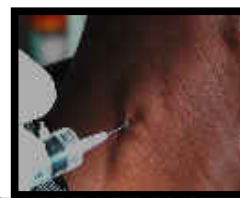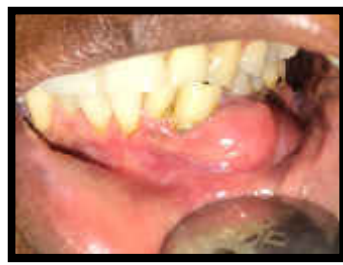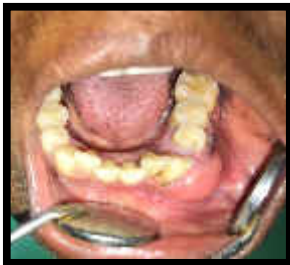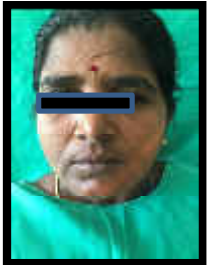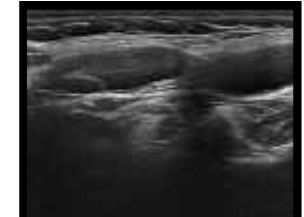


**SKELETAL CLASS  
III  
MALOCCLUSION**

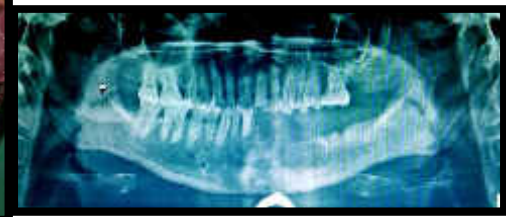
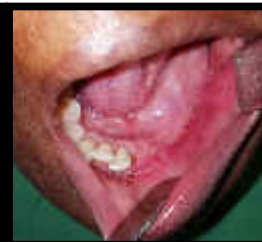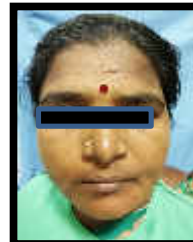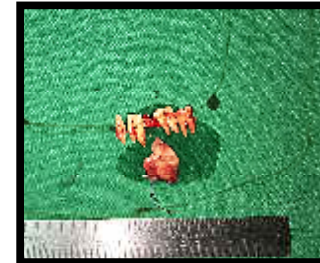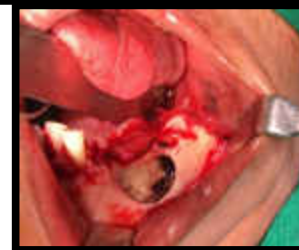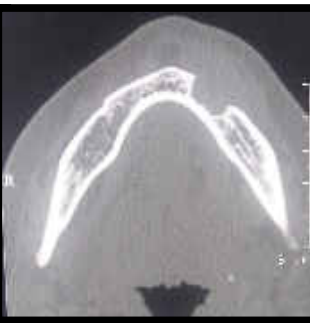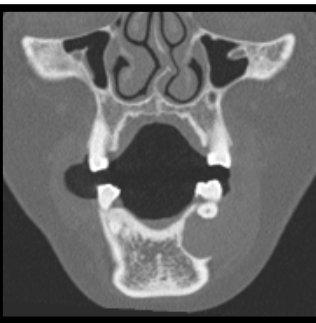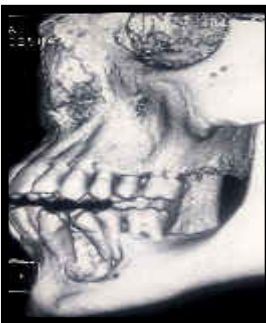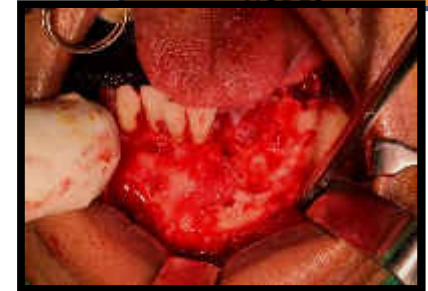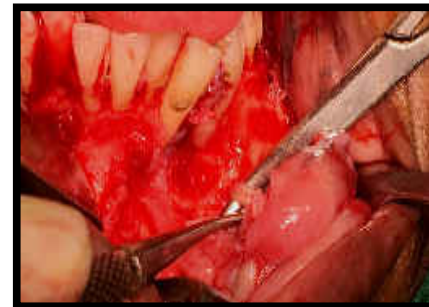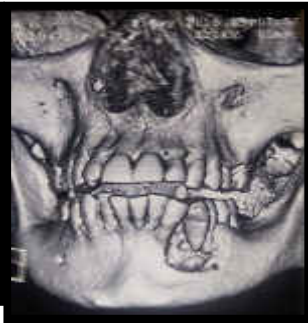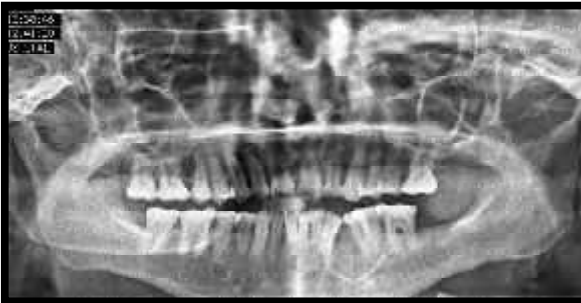
# CLEAR CELL ODONTOGENIC TUMOR



ULTRASOUND GUIDED FNAC OF LYMPH NODES



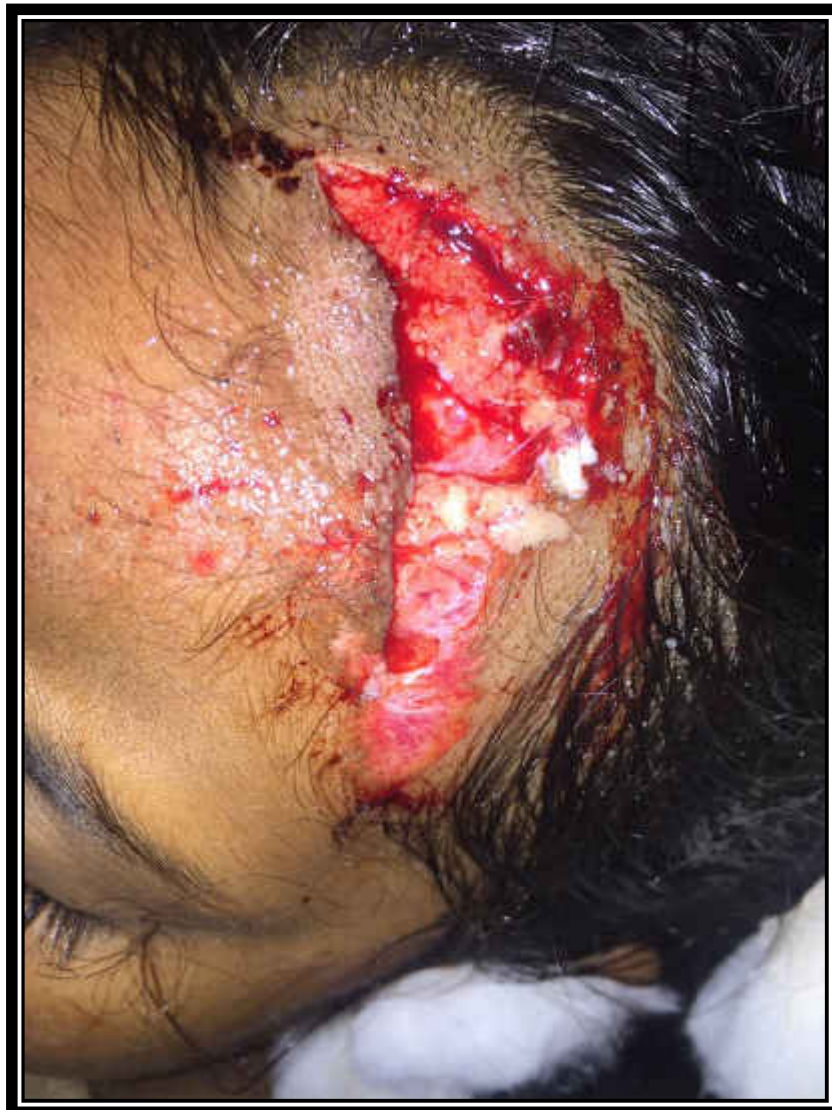REACTIVE LYMPH



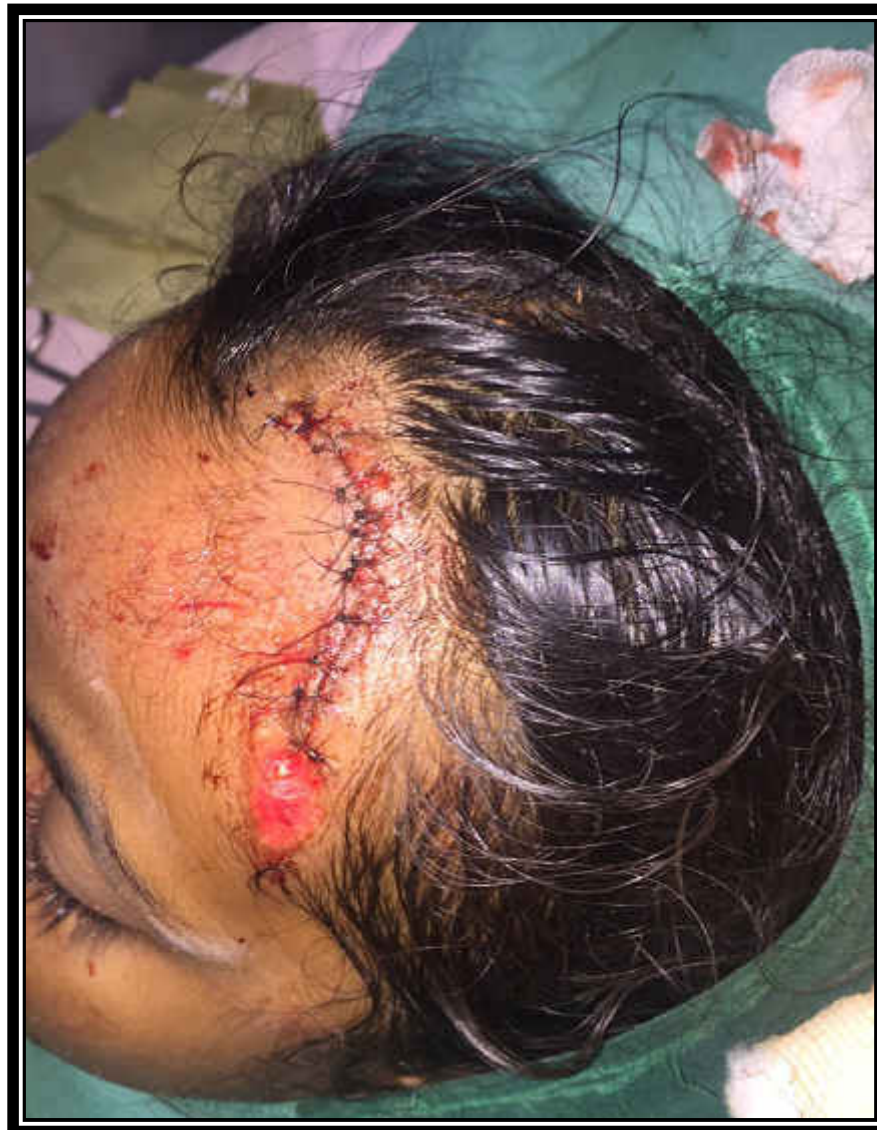# SOFT TISSUE INJURIES



**PRE-OP**

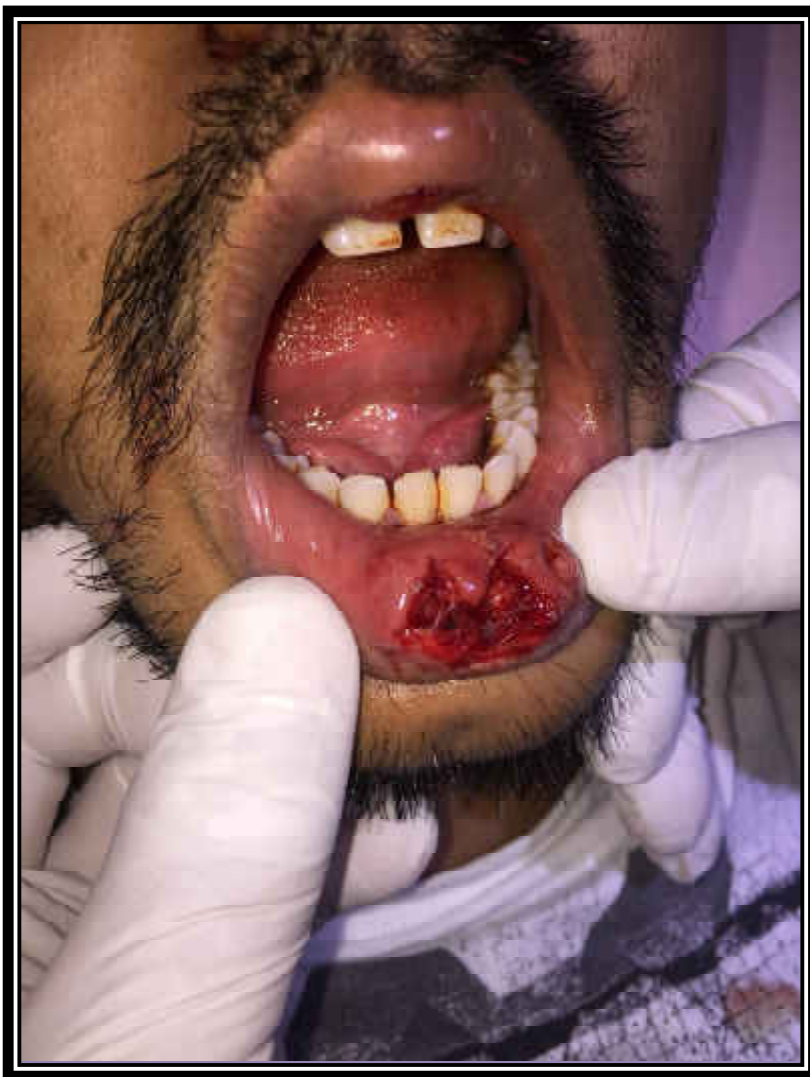

**POST-OP**

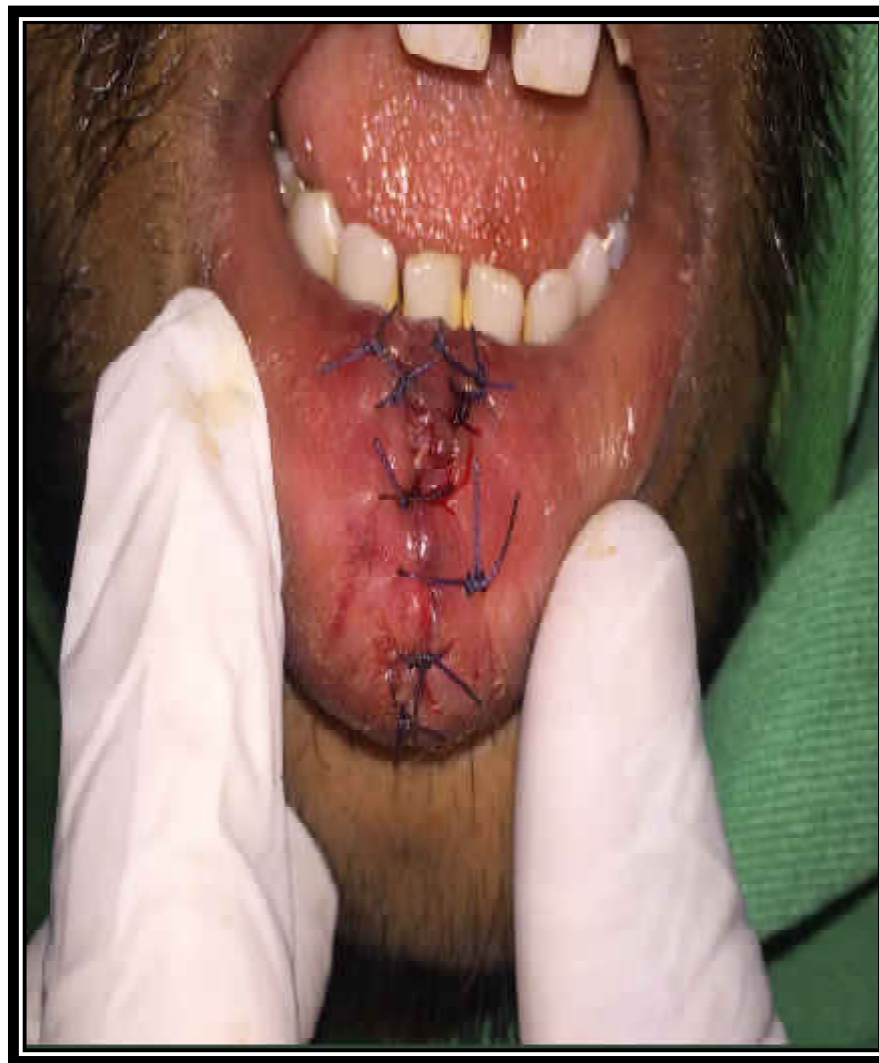




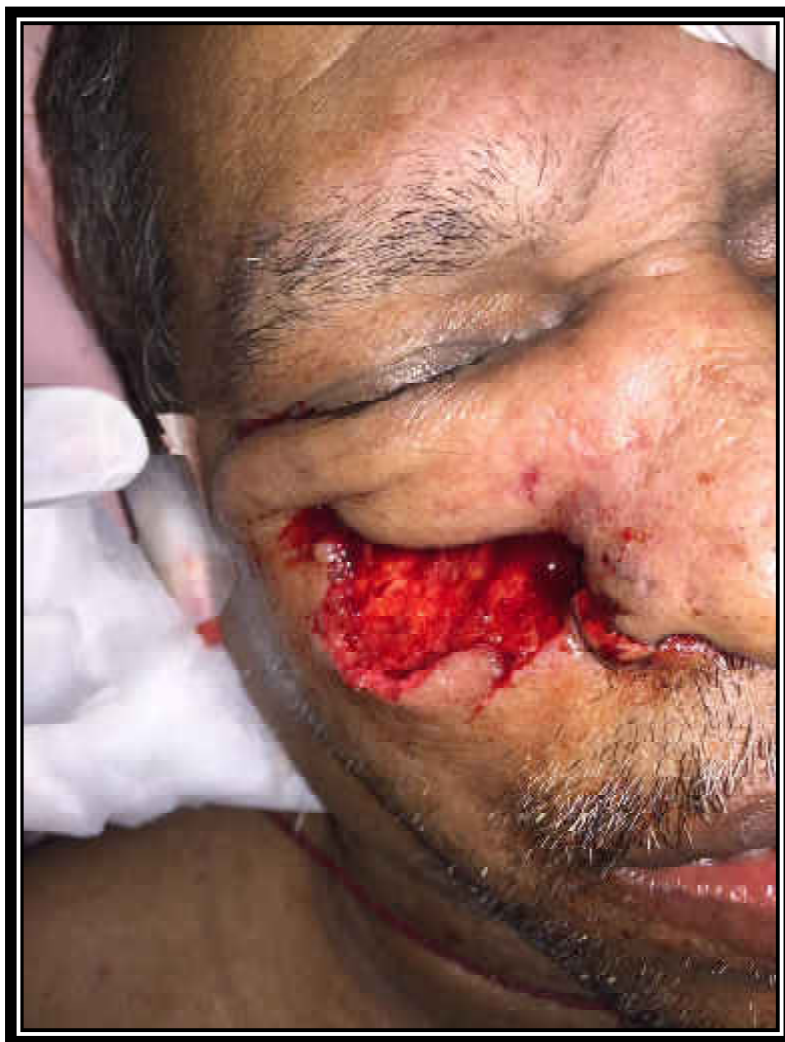**PRE-OP**



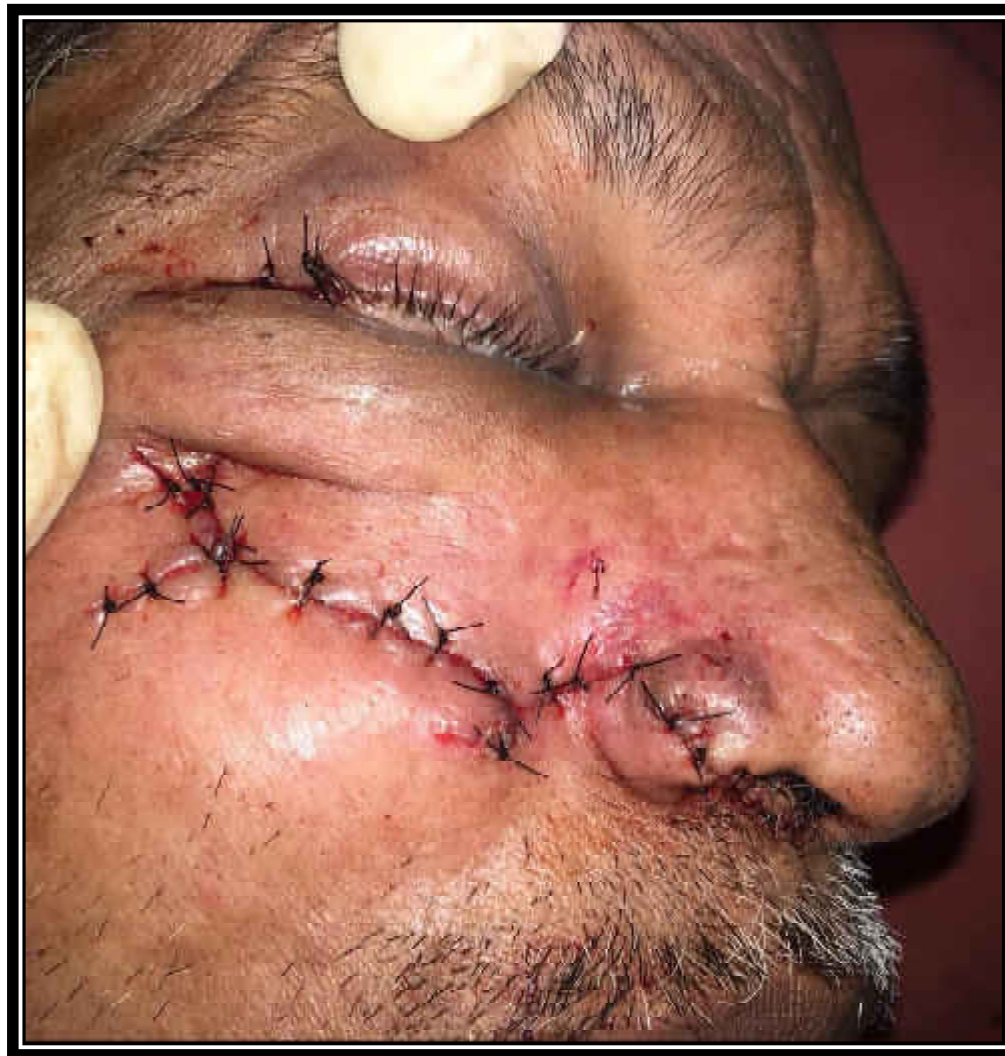**POST-OP**



**PRE-OP**

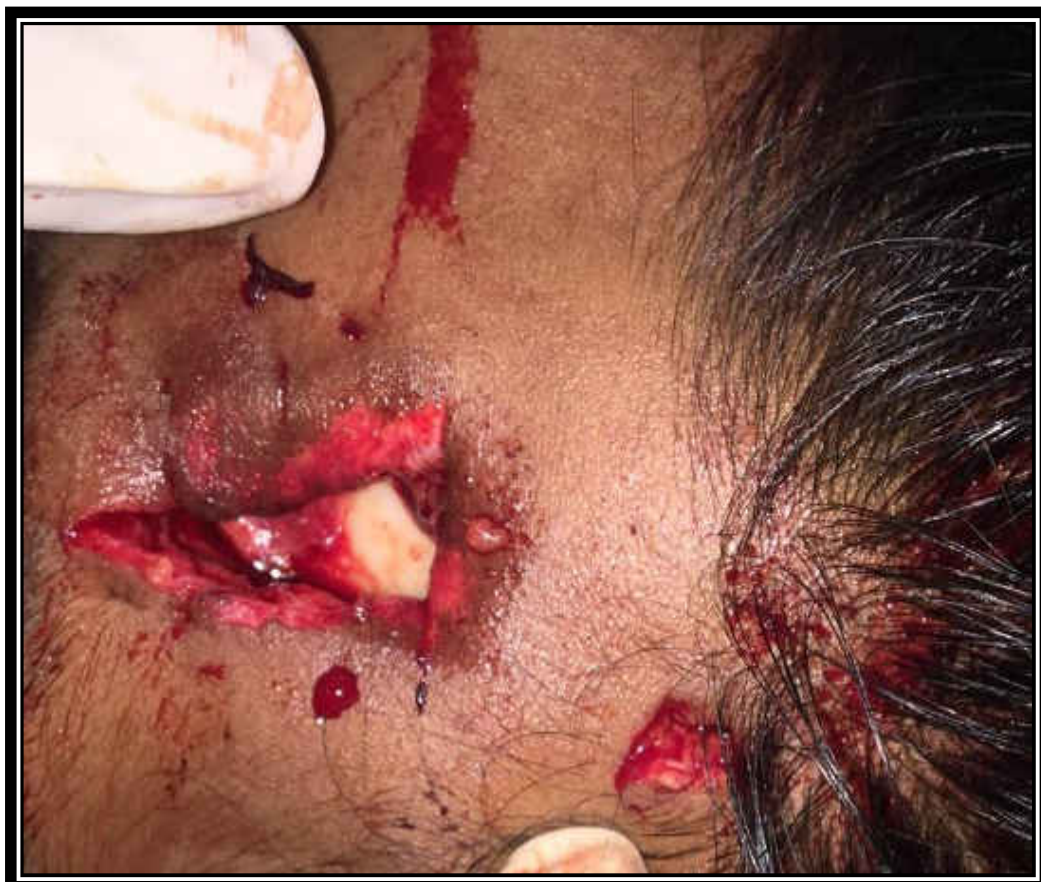

**POST-OP**

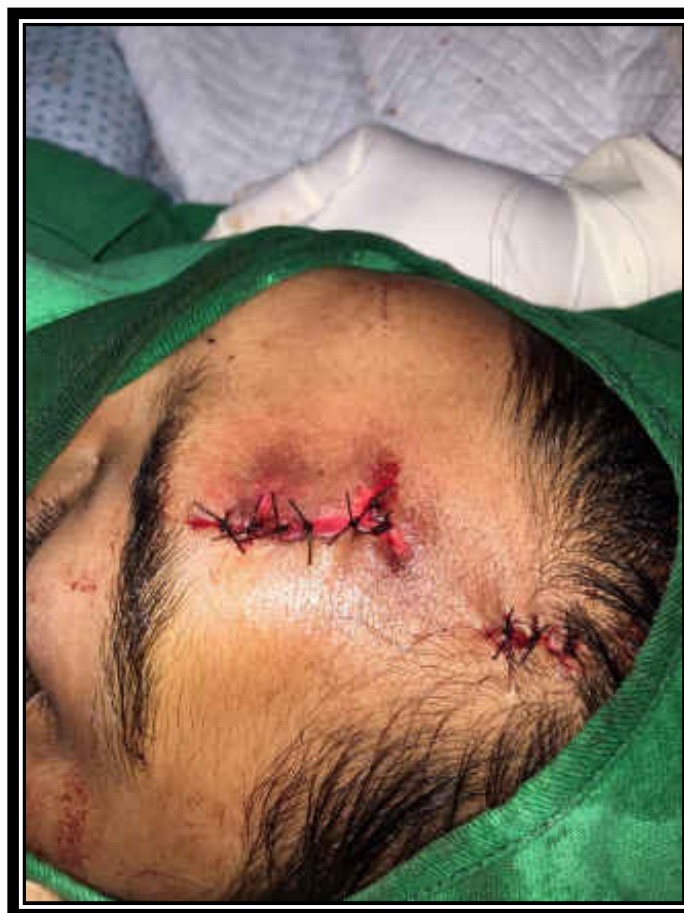



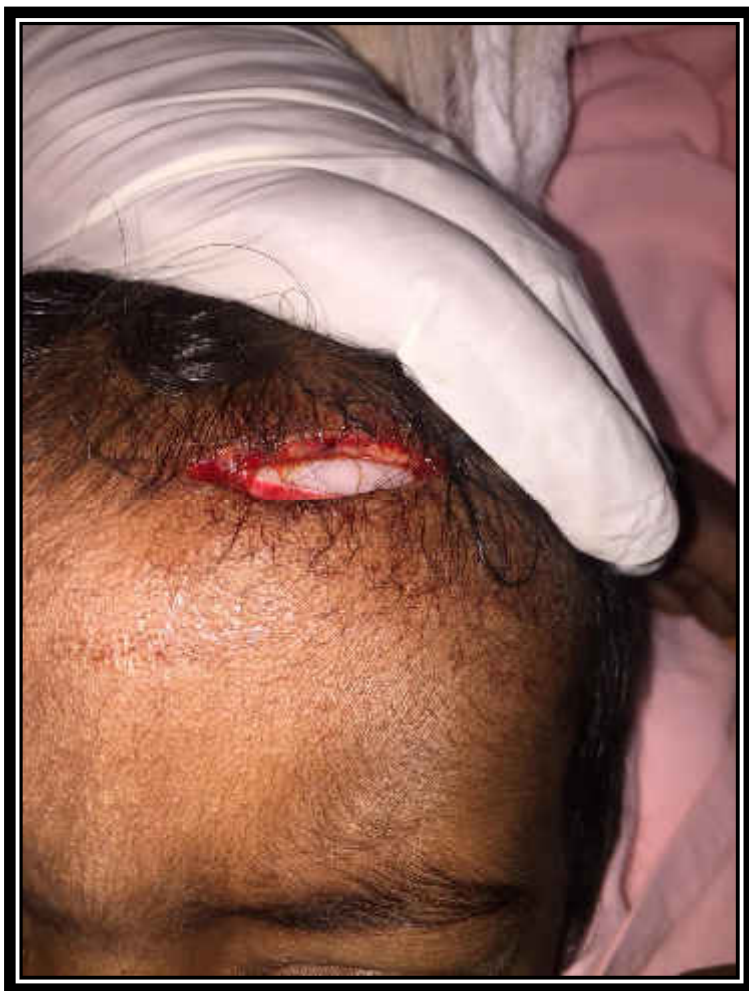**PRE-OP**



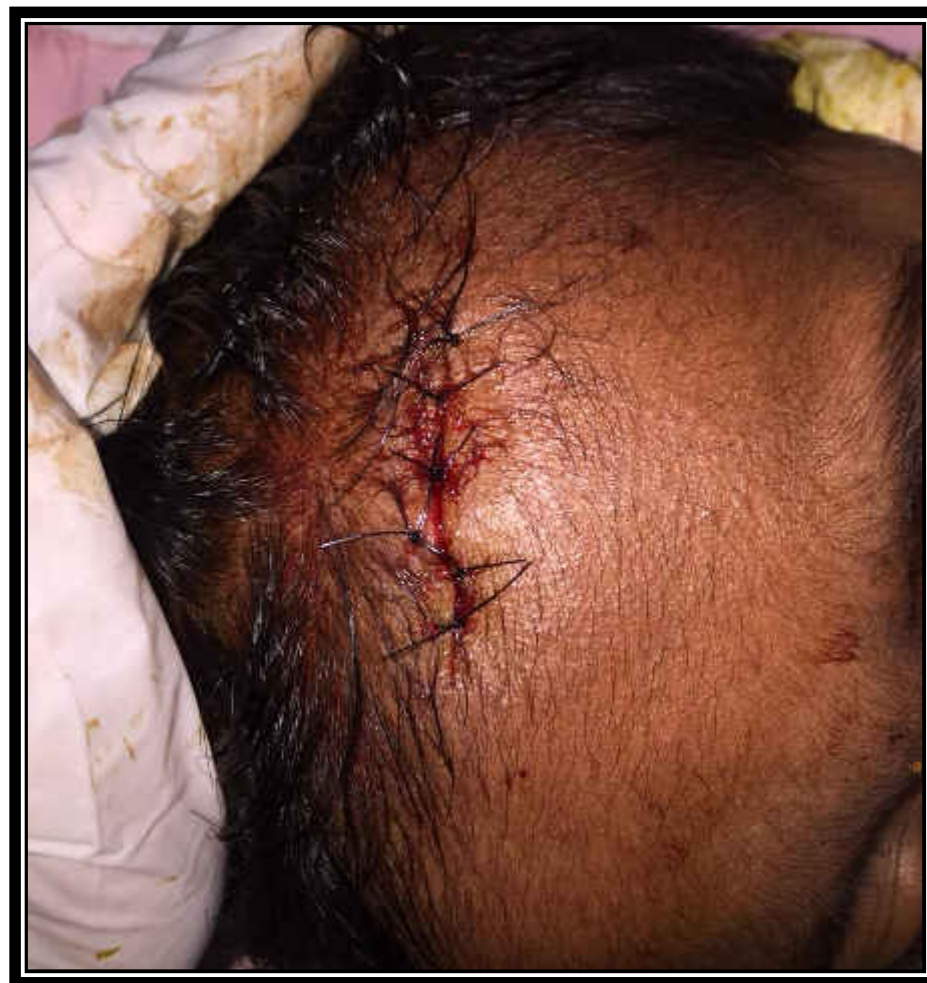**POST-OP**



**PRE-OP**

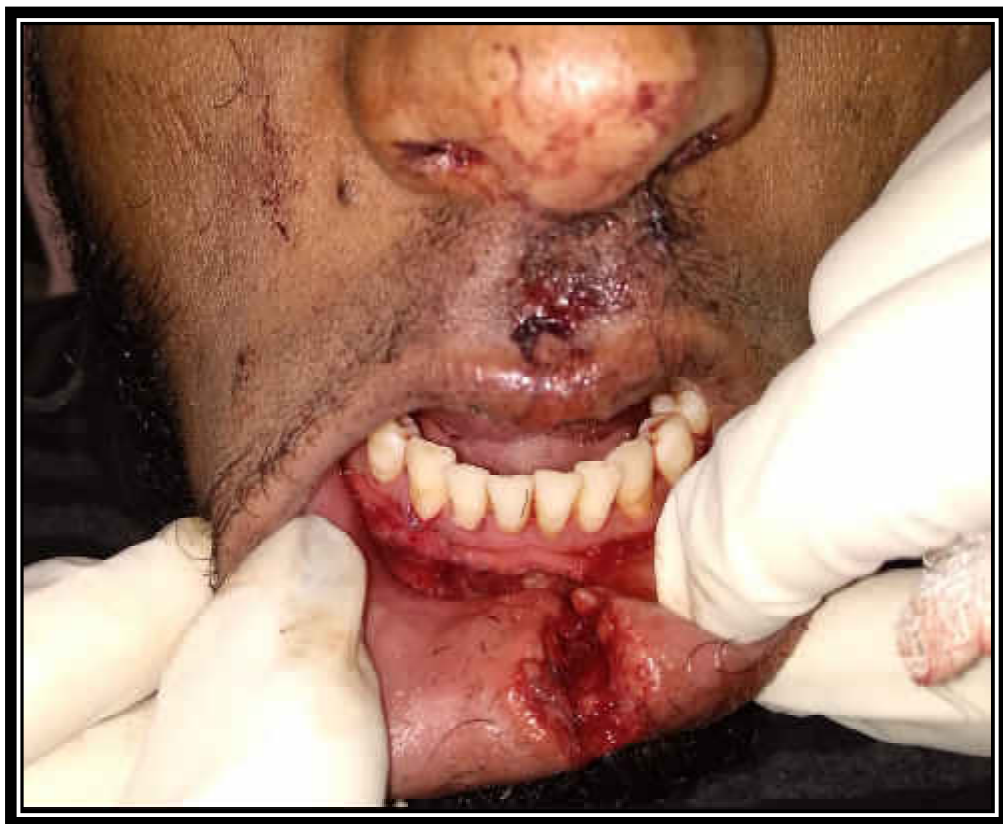

**POST-OP**

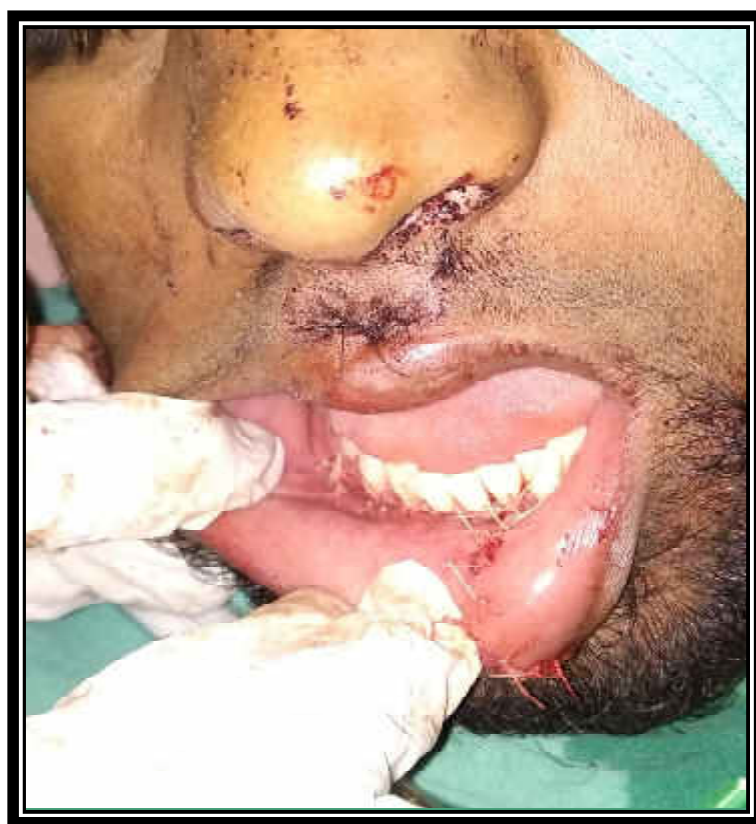




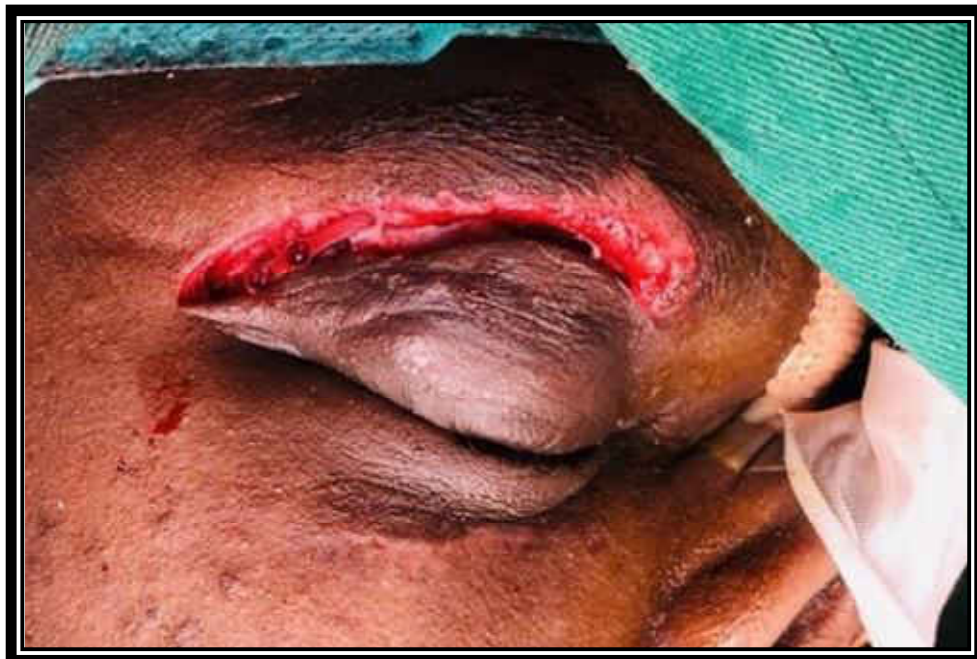**PRE-OP**



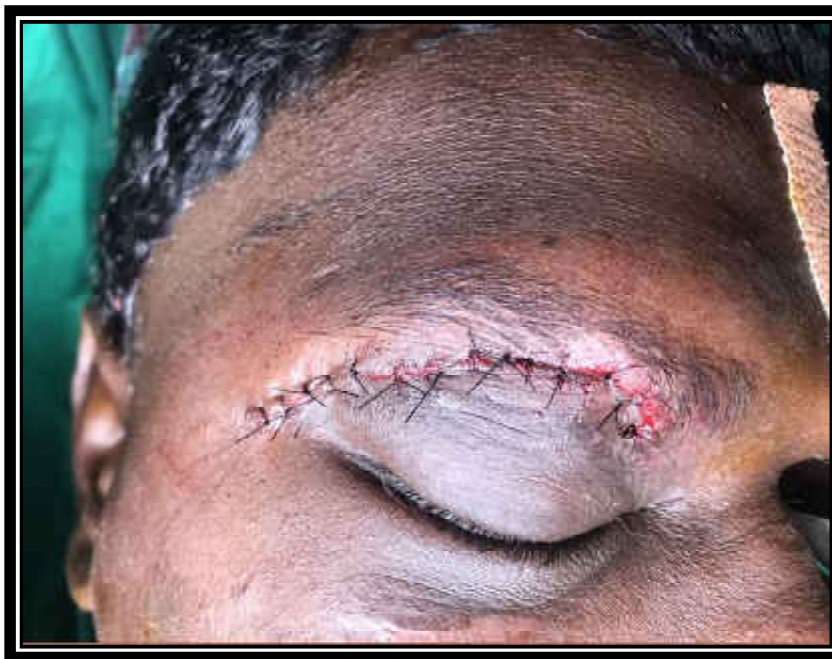**POST-OP**



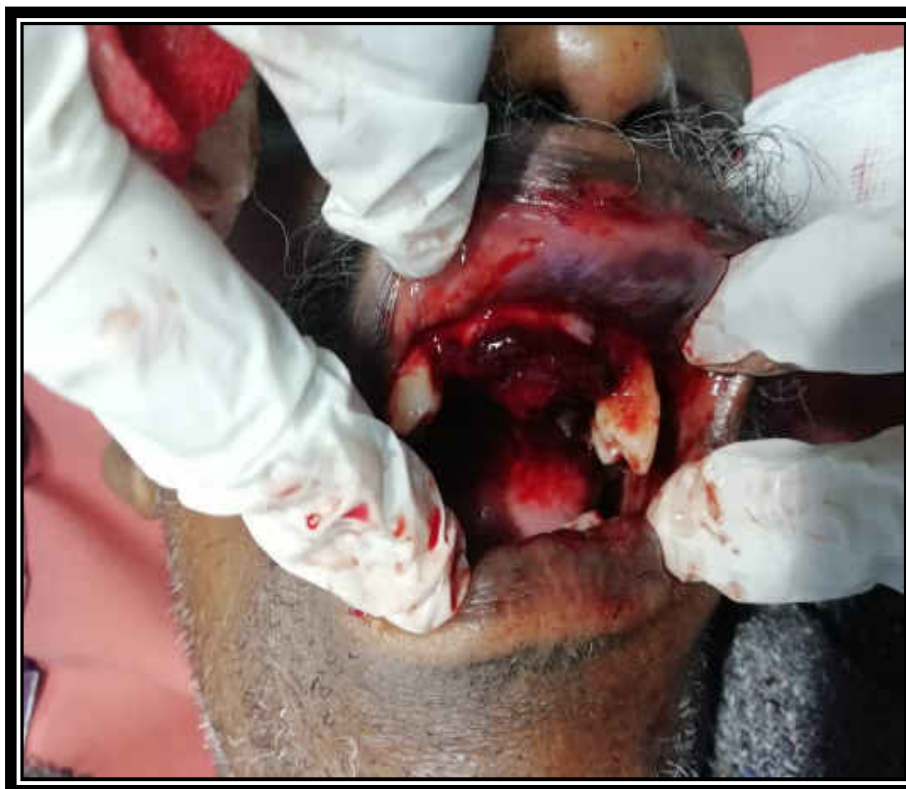**PRE-OP**



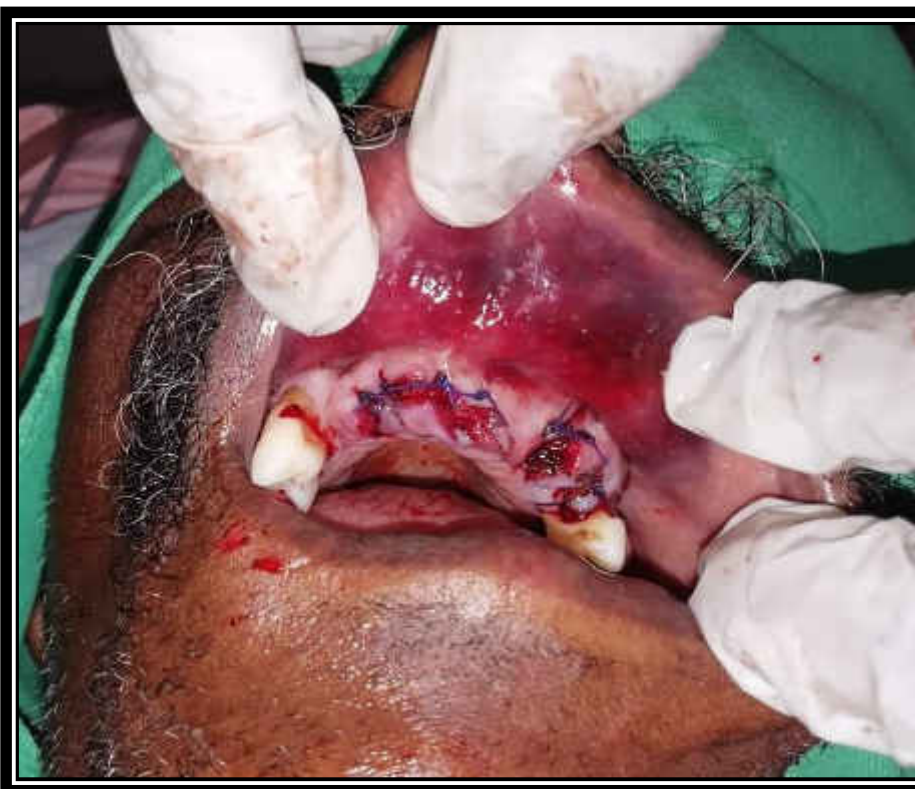
**POST-OP**



**PRE-OP**

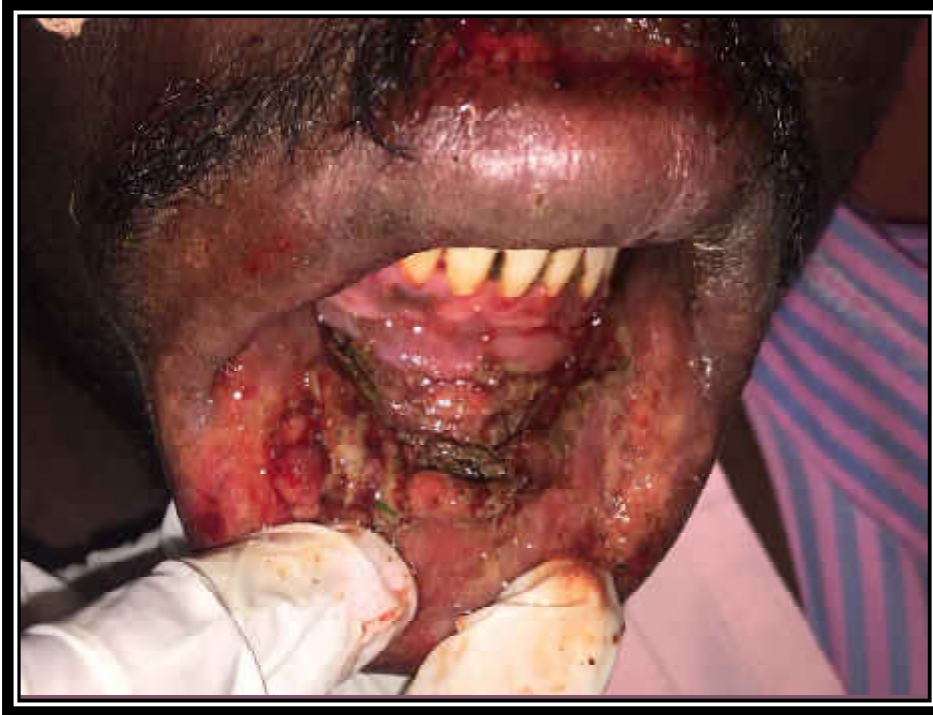

**POST-OP**

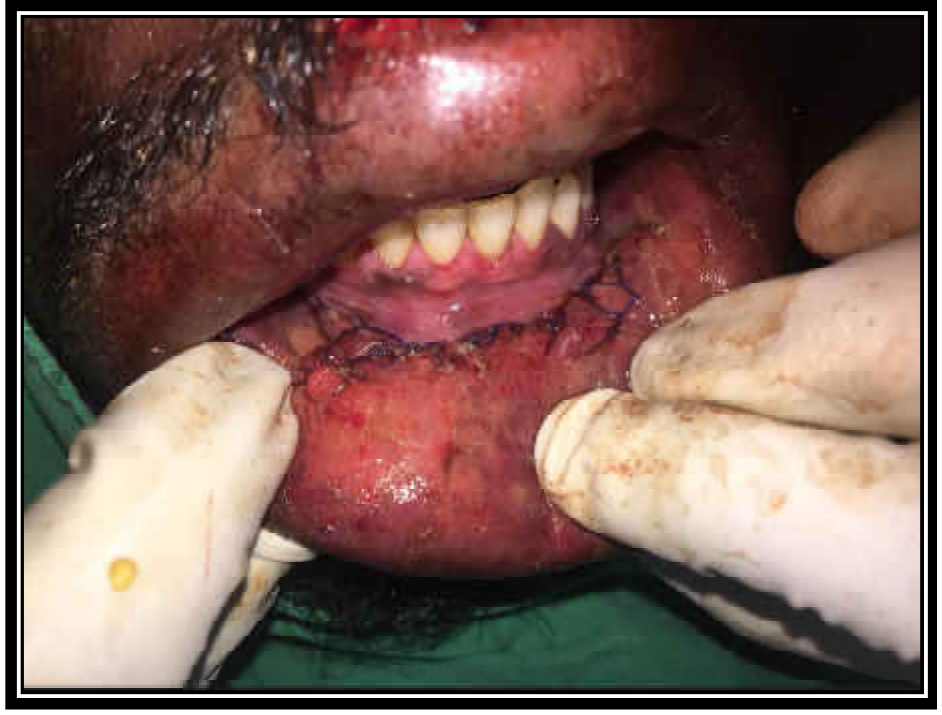



**PRE-OP**

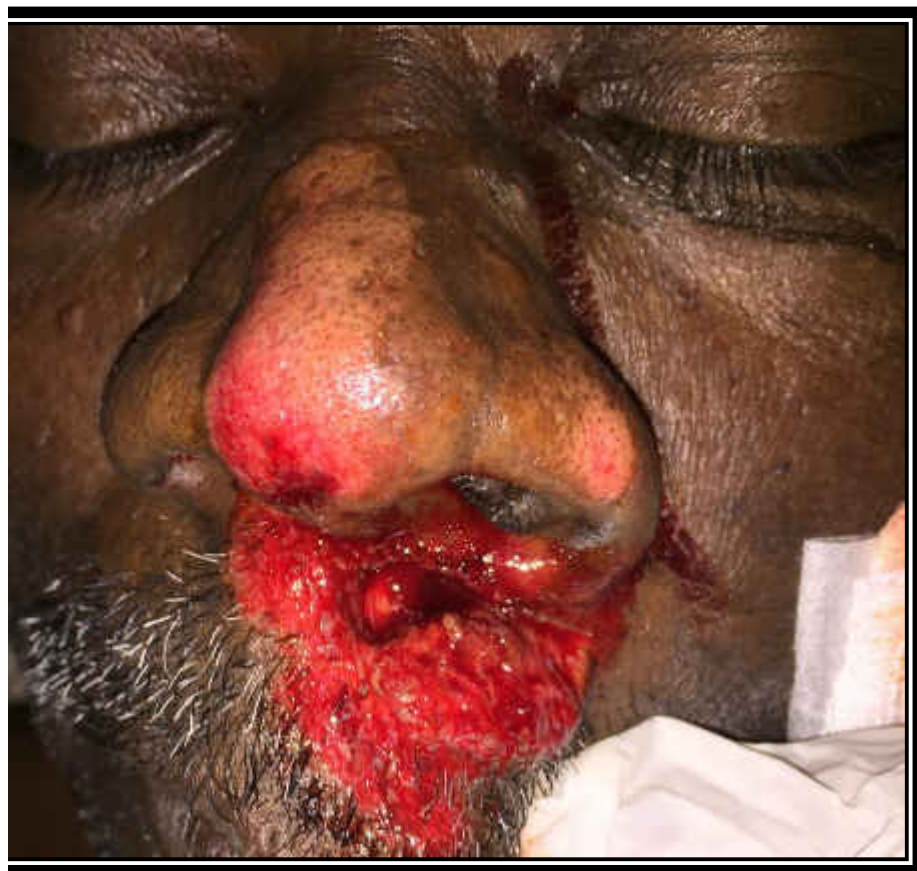

**POST-OP**

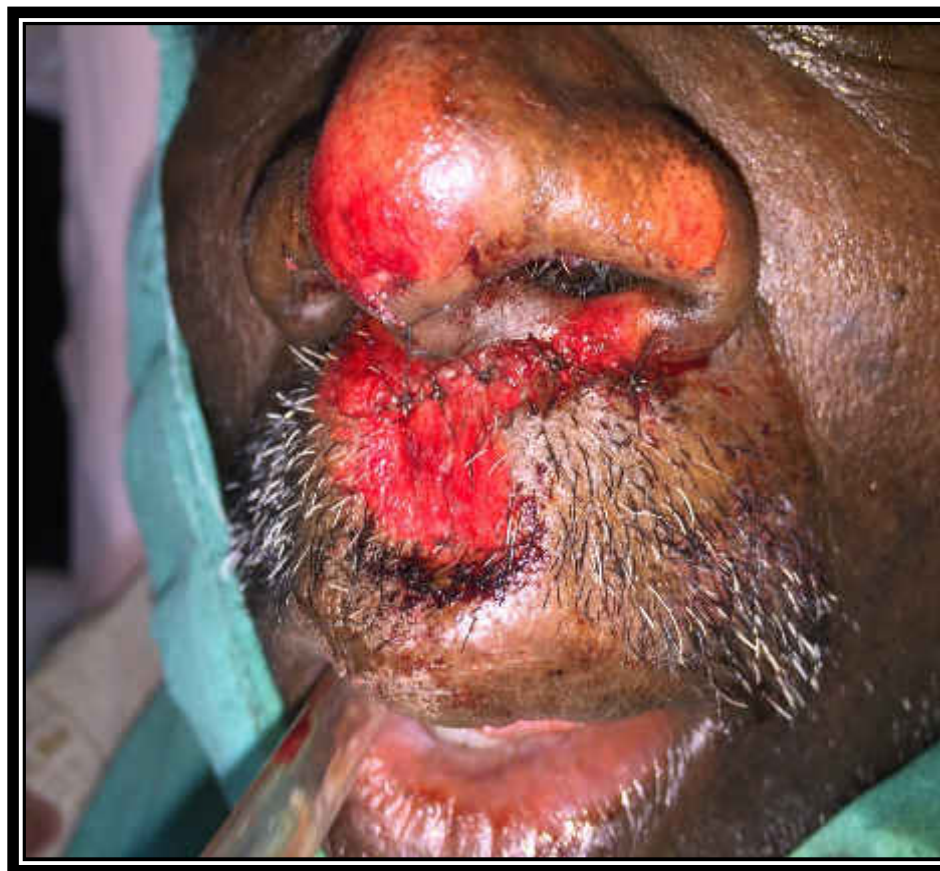



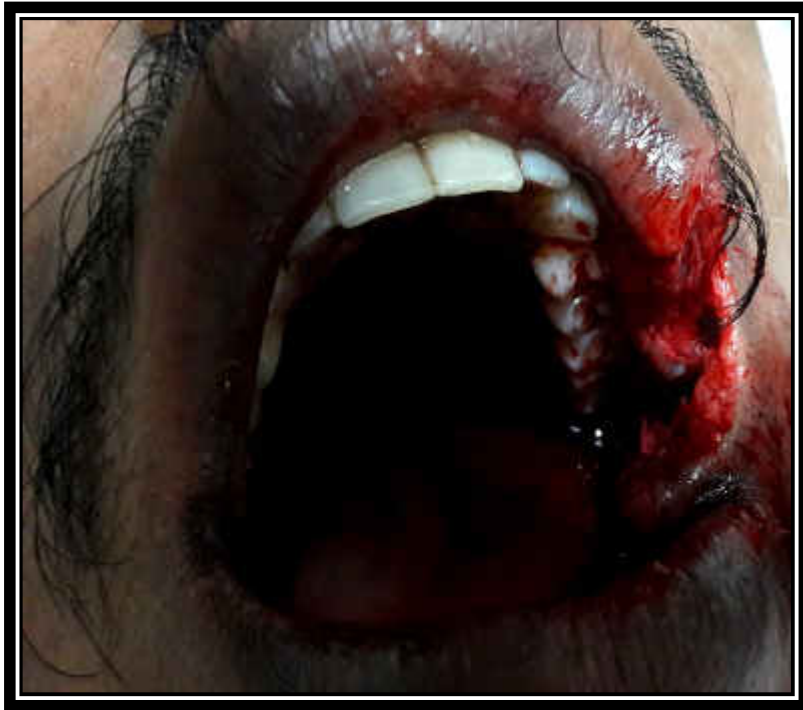**PRE-OP**



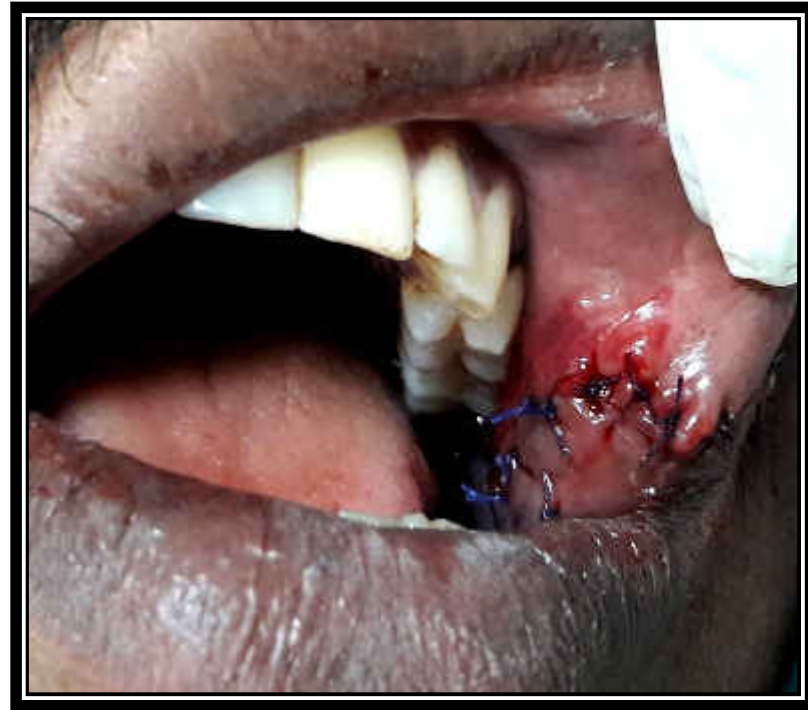**POST-OP**



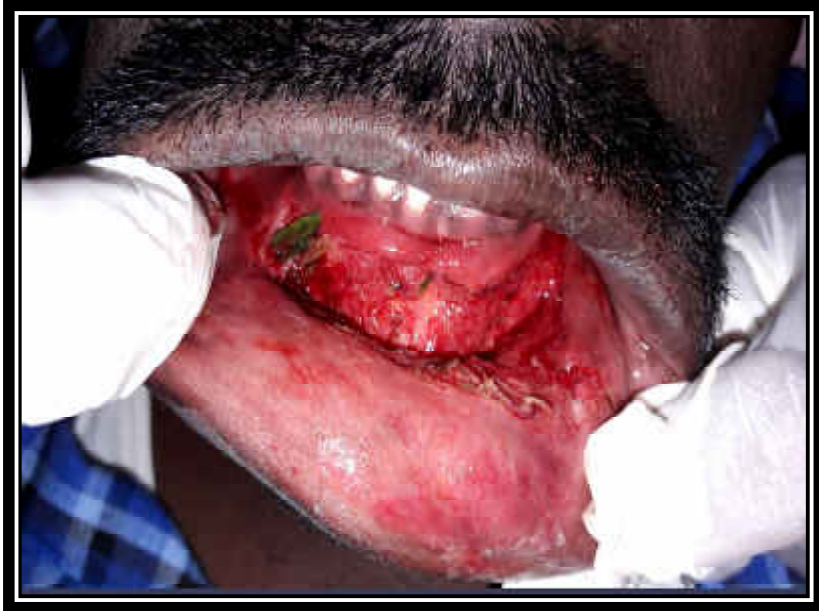**PRE OP**



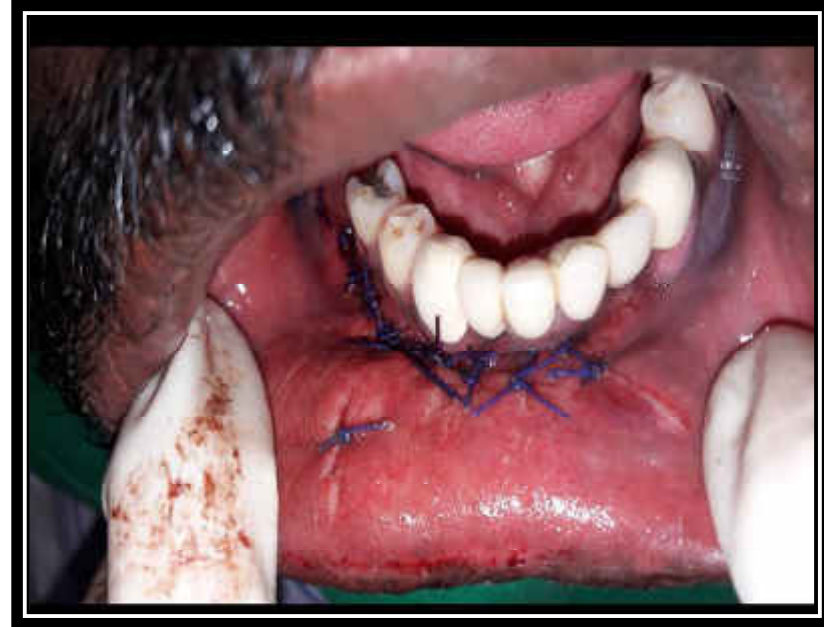**POST OP**



**PRE OP**

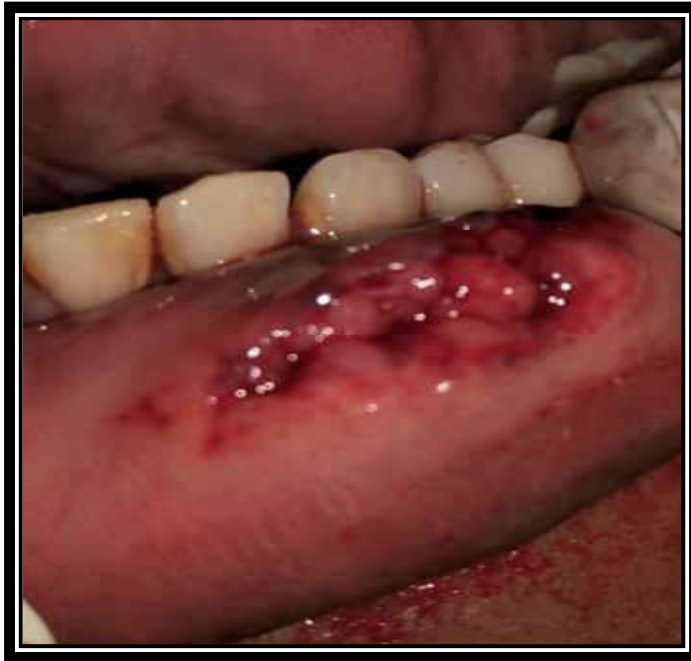

**POST OP**

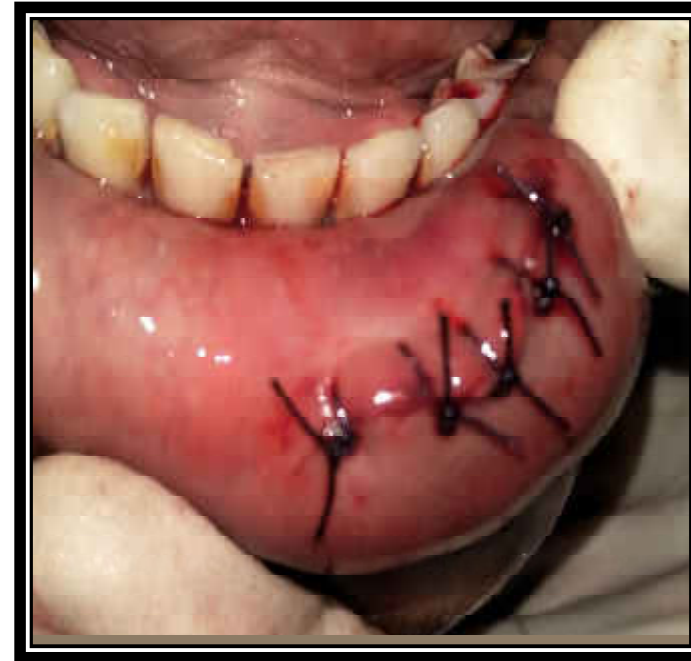




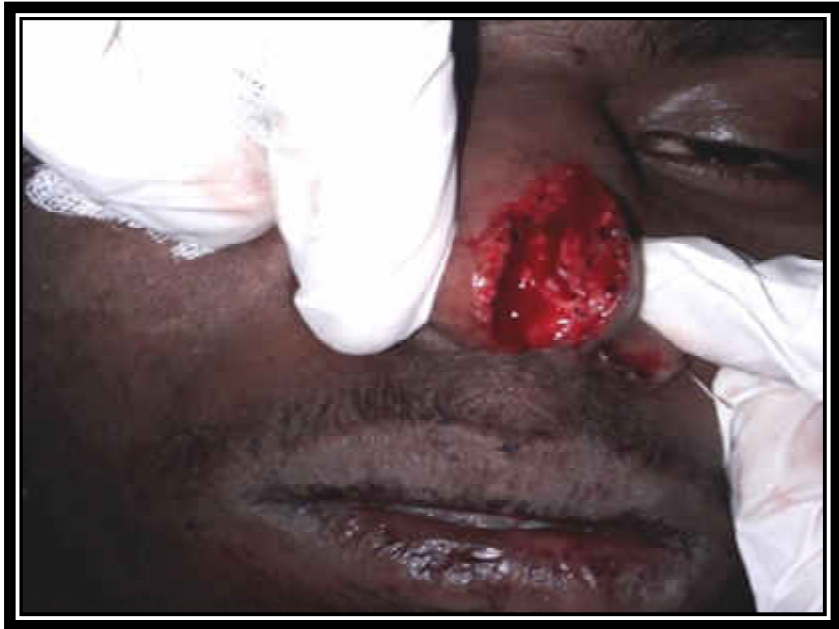**PRE OP**



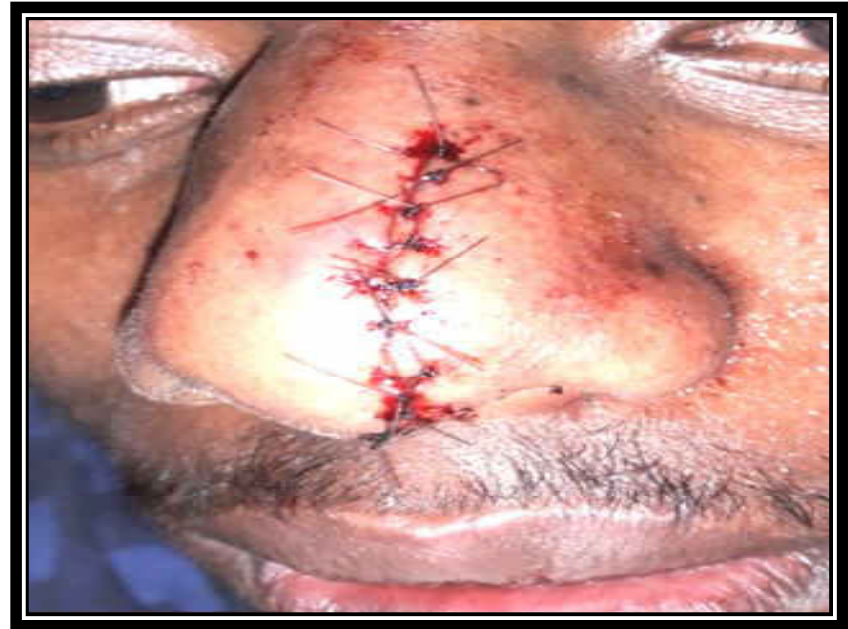**POST OP**



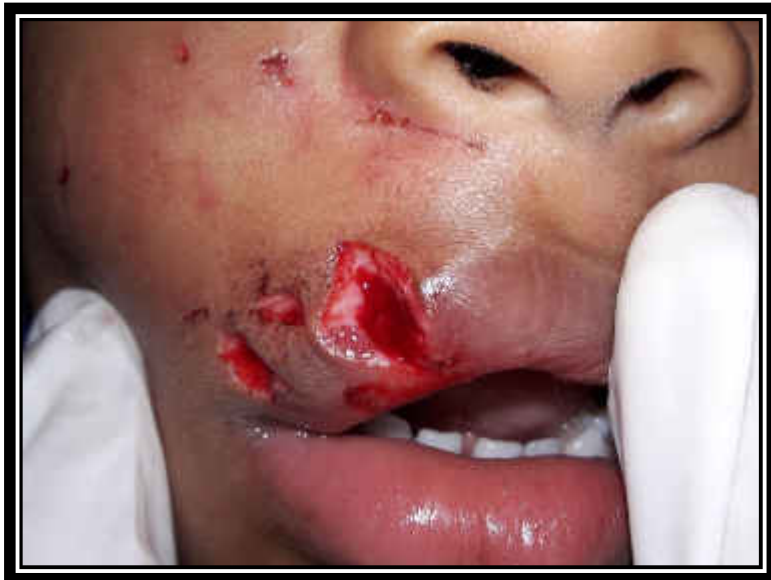**PRE OP**



**POST OP**



**PRE OP**



**POST OP**





