



DEPARTMENT OF PEDODONTICS AND PREVENTIVE DENTISTRY

SCHEDULE FOR INTERNS (13.4.2020-18.4.2020)

S. NO	DATE	TOPIC	FACULTY	NO.OF STUDENTS PARTICIPATED
1	13.4.2020	Cavity preparation in Primary teeth	Dr. Daya Srinivasan	Valarmathi Yuvaranjani
2	15.4.2020	Pulpotomy	Dr. Senthil Eagappan.AR	Valarmathi Yuvaranjani
3	16.4.2020	Pulpectomy	Dr Divya N	Valarmathi Yuvaranjani
4	17.4.2020	Apexogenesis & Apexification	Dr Devi Chandrika	Valarmathi Yuvaranjani
5	18.4.2020	Stainless steel Crowns	Dr Daya Srinivasan	Haritha Aswini Sruthi



Chettinad

Dental College & Research Institute

Topic : Cavity Preparation in Primary Teeth

Date : 13.04.2020

Faculty instructor: Dr. Daya Srinivasan.

Faculty attended: Dr. Senthil Eagappan AR, Dr.Divya.N, Dr. Devi Chandrika

Intern: 2

Platform : ZOOM

Daya Srinivasan is inviting you to a scheduled Zoom meeting.

Topic: Daya Srinivasan's Zoom Meeting

Time: Apr 13, 2020 11:30 AM India

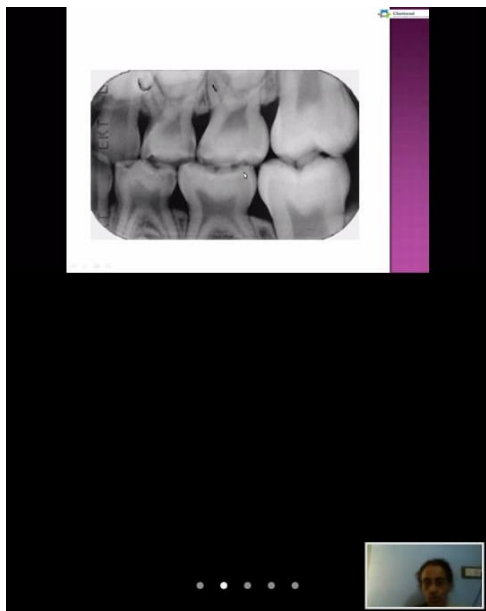
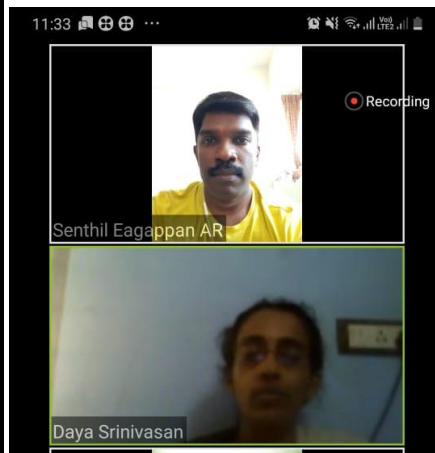
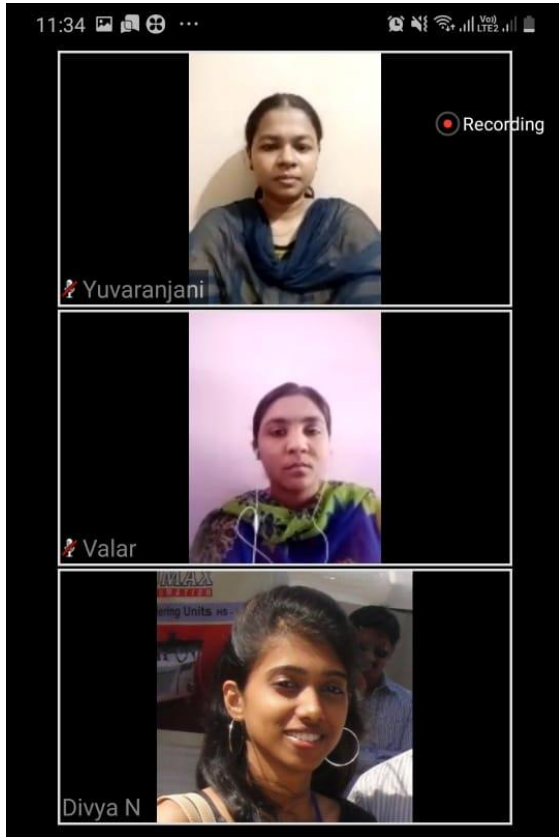
Join Zoom Meeting

<https://us04web.zoom.us/j/6664598002?pwd=bGFkZWdoVWZJcnc1MlMwczRlTUdMUT09>



Chettinad

Dental College & Research Institute





Chettinad

Dental College & Research Institute

T BAND CONSTRUCTION

Daya Srinivasan's screen

Recording

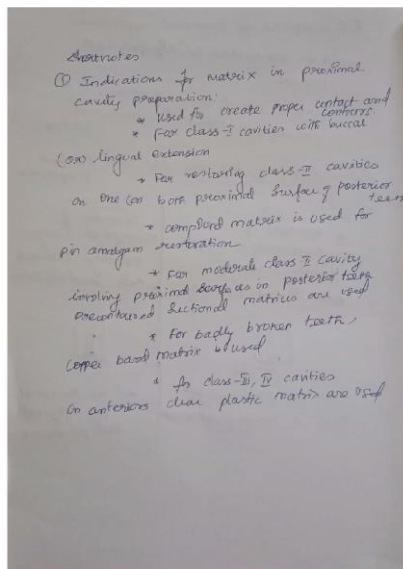
- SE Senthil Eagappan AR(me) >
- D Daya Srinivasan (host) >
- Divya N >
- V Valar >
- Y Yuvaranjani >



Chettinad

Dental College & Research Institute

Test for the Interns-13.3.2020



Scanned by CamScanner

Indications of matrix in proximal cavity preparation:

- It is used to establish proper contact & contour.
- Ivory matrix No. 1 is used when the contact on the unprepared side is very tight
- Ivory matrix No. 2 is used for restoration on both proximal surfaces of tooth.
- Precontoured sectional matrices are used for small to moderate class II cavities

Indications of wedges:

- Peggy back wedging is used when interproximal tissue seal has receded
- Double wedging is used for securing the matrix when the proximal bar is wide & irregular
- Wedge wedging is used when cavity is present on proximal surface

Web link:

<https://drive.google.com/open?id=1Pq4CMtI5797gikLUQAeZNu2h0dp9Q578>



Chettinad

Dental College & Research Institute

Topic : Pulpotomy

Date : 15.04.2020

Faculty instructor : Dr. Senthil Eagappan AR

Faculty attended : Dr. Daya Srinivasan, Dr.Divya.N, Dr. Devi Chandrika

Interns:2

Platform : ZOOM

Senthil Eagappan AR is inviting you to a scheduled Zoom meeting.

Topic: Intern E-Clinics Discussion - 15.04.2020

Join Zoom Meeting

<https://us04web.zoom.us/j/79669362831?pwd=dEx5dkxJeElCL3pCMUJ2U1o3VIJHUT09>

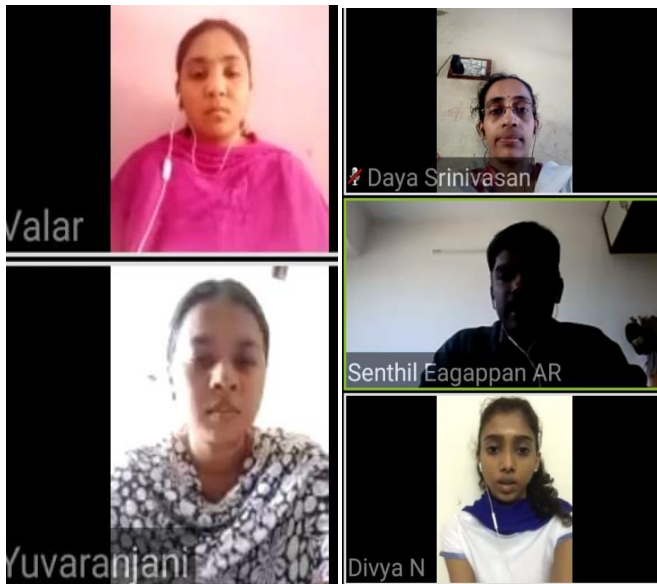Meeting ID: 796 6936 2831

Password: 0Ayq1v



Chettinad

Dental College & Research Institute







- DC Devi Chandrika (me)   >
- SE Senthil Eagappan AR (host)   >
- D Daya Srinivasan   >
- DN Divya N   >

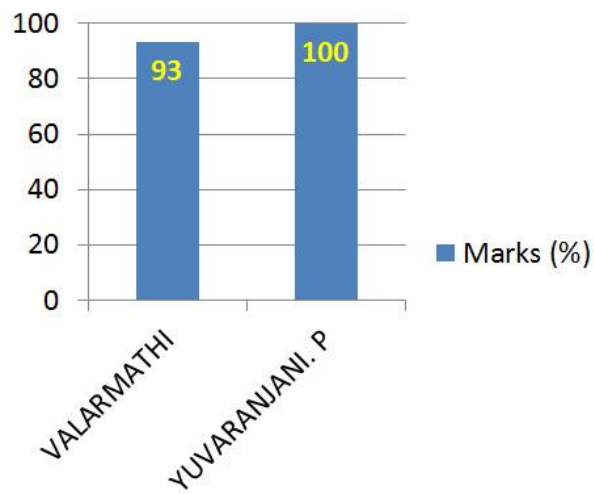


Chettinad

Dental College & Research Institute

- V Valar   >
- Y Yuvaranjani   >

PULPOTOMY E-TEST (15.04.2020) - INTERNS



Weblink:

https://drive.google.com/file/d/18GFmP7rdt_-5fXbl1YyKHEUL8LpAmr8-/view?usp=sharing



Chettinad

Dental College & Research Institute

Topic : Pulpectomy

Date : 16.04.2020

Faculty instructor : Dr.Divya.N

Faculty attended : Dr. Daya Srinivasan, Dr. Senthil Eagappan AR, Dr. Devi Chandrika

Interns: 2

Platform : ZOOM

Divya N is inviting you to a scheduled Zoom meeting.

Topic: Pulpectomy E-Clinic

Time: Apr 16, 2020

Join Zoom Meeting

<https://us04web.zoom.us/j/78495218961>

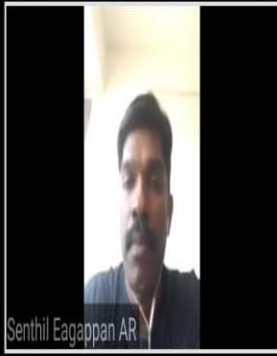

Chettinad

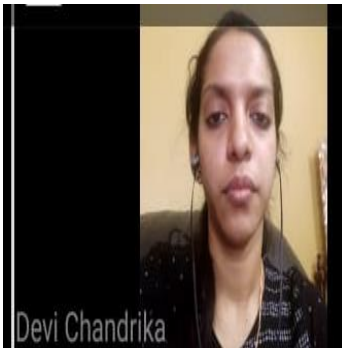Dental College & Research Institute



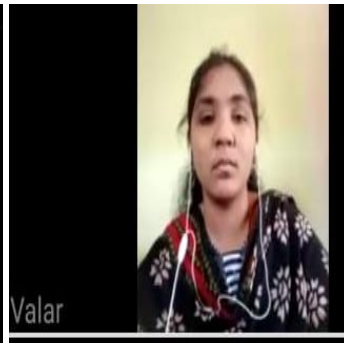Divya N



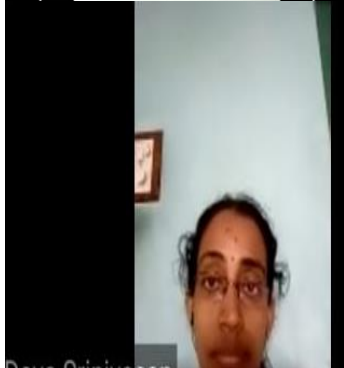Senthil Eagappan AR



Devi Chandrika



Valar



Dr. Princy



Chettinad

Dental College & Research Institute

V Valar   >

Y Yuvaranjani   >

DC Devi Chandrika (me)   >

 Divya N (host)   >

D Daya Srinivasan   >

SE Senthil Eagappan AR   >

Weblink:

https://drive.google.com/file/d/18GFmP7rdt_-5fXbl1YyKHEUL8LpAmr8-/view?usp=drivesdk



Chettinad

Dental College & Research Institute

Topic : Apexogenesis and Apexification

Date : 17.04.2020

Faculty instructor : Dr.Devi Chandrika

Faculty attended : Dr. Daya Srinivasan, Dr. Senthil Eagappan AR, Dr. Divya.N

Interns:2

Platform : ZOOM

Devi Chandrika is inviting you to a scheduled Zoom meeting.

Topic: Final year clinical discussion

Time: Apr 17, 2020

Join Zoom Meeting

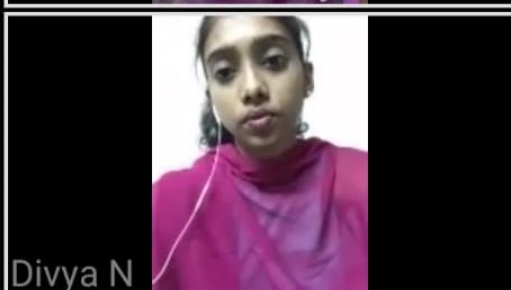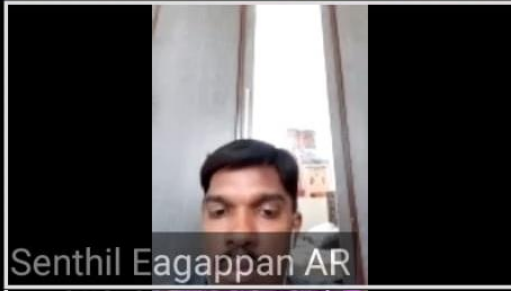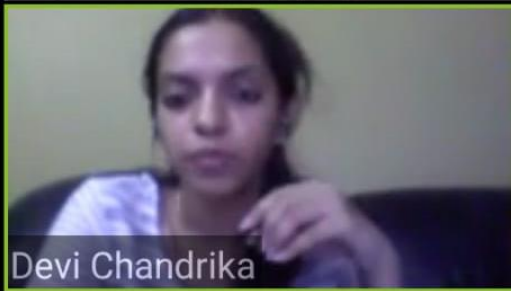
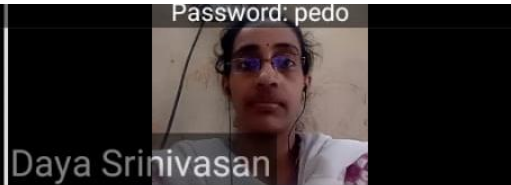<https://us04web.zoom.us/j/72083023646?pwd=dkFxL3NrMFJKaHo4eTFZTEF1Y3NTQT09>



Chettinad

Dental College & Research Institute

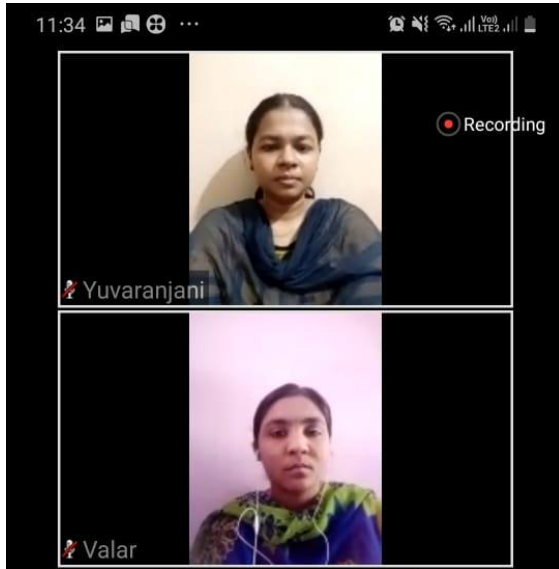
Password: pedo

















Chettinad

Dental College & Research Institute



SE	Senthil Eagappan AR(me)	  >
D	Daya Srinivasan (host)	   >
	Divya N	  >
V	Valar	  >
Y	Yuvaranjani	  >

Weblink:

<https://drive.google.com/file/d/1upGRk1sESTbnqSdZzqaiDslCdMfEFgNs/view>



Chettinad

Dental College & Research Institute

Topic : Stainless Steel Crowns

Date : 17.04.2020

Faculty instructor : Dr.Daya Srinivasan

Faculty attended : Dr. Senthil Eagappan AR, Dr. Divya N, Dr.Devi Chandrika

Interns:3

Platform : ZOOM

Daya Srinivasan is inviting you to a scheduled Zoom meeting.

Topic: Daya Srinivasan's Zoom Meeting

Time: Apr 18, 2020 11:30 AM India

Join Zoom Meeting

<https://us04web.zoom.us/j/6664598002?pwd=bGFkZWdoVWZJcnc1MlMwc2F5TUdMUT09>

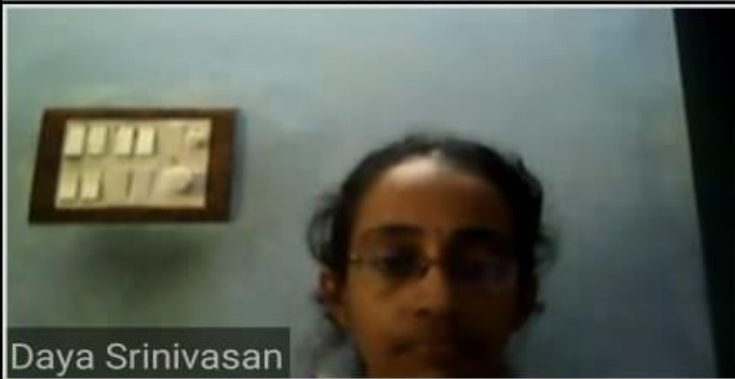Meeting ID: 666 459 8002

Password: pedo

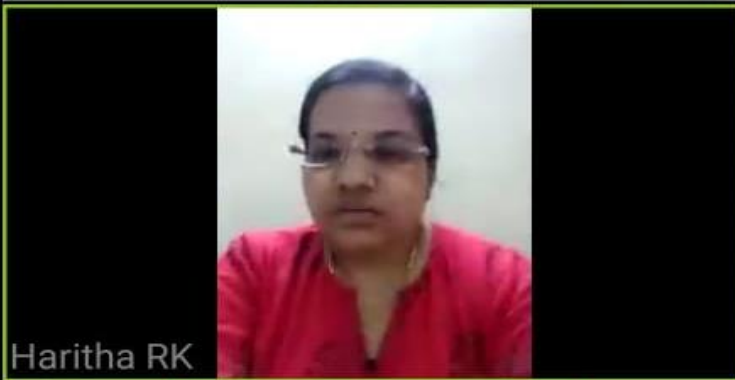

Chettinad

Dental College & Research Institute



Daya Srinivasan



Haritha RK



Aswini S





Chettinad

Dental College & Research Institute

11:39 🕒 📷 📧 ... 🔔 📶 VoLTE LTE2 📶 🔋

Senthil Eagappan

Sruthi Praveen

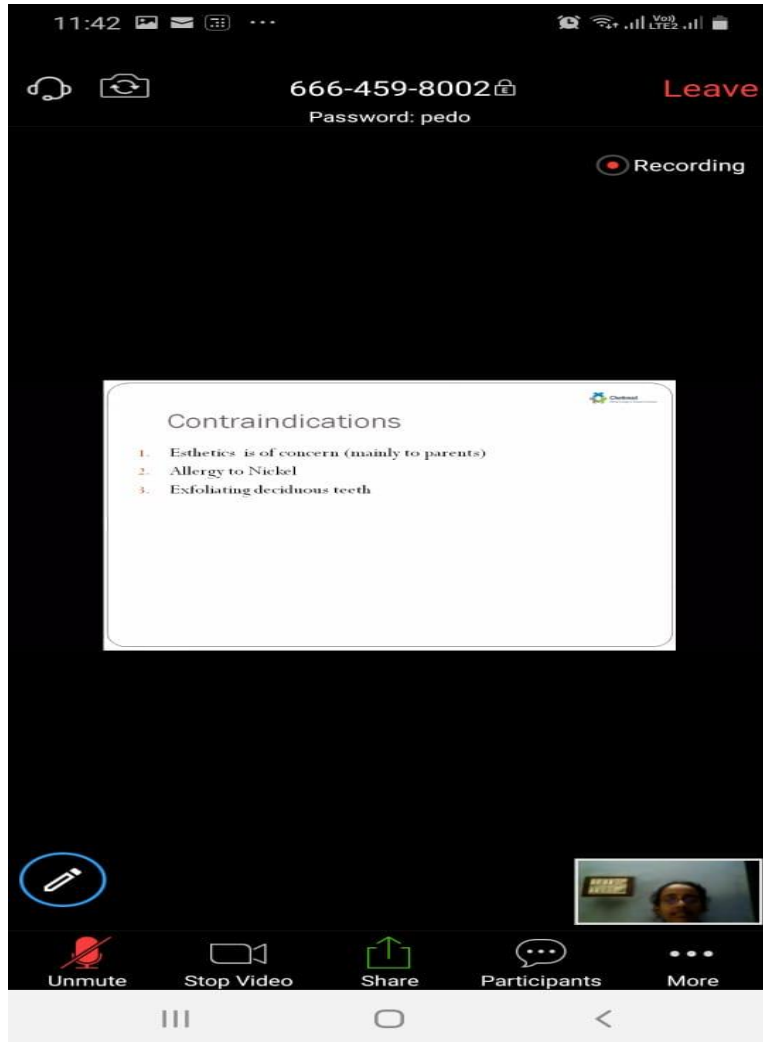
Daya Srinivasan is starting record

A screenshot of a mobile video call interface. The top status bar shows the time 11:39 and various icons for notifications, camera, messages, and connectivity. The call area is divided into two video windows. The top window shows a man with a mustache, identified as Senthil Eagappan. The bottom window shows a woman with dark hair, identified as Sruthi Praveen. At the bottom of the screen, a grey bar contains the text 'Daya Srinivasan is starting record'.



Chettinad

Dental College & Research Institute





Google form test for Interns

QUESTION Department of Pediatric & Preventive Dentistry

Department of Pediatric & Preventive Dentistry

Resilient steel crown

Email address *

anilganesan13@gmail.com

What is the composition of SS crown, which makes it strong? *

Iron 45, nickel 10-12%, chromium 17-19%

The newer technique wherein SS crown is placed on an unremoved caries is called? *

Hot

How SS crown can be used for correction of malocclusion? *

Anterior open bite and form inclined plane

Name a hypoplastic tooth condition where SS crown is indicated? *

Dentogenesis imperfecta

Name one inferior crown with metal backing? *

Hot

Write why one contraindication of SS crown? *

Including dentulous tooth

What will you do if you have a large SS crown but tooth is small? *

Carburize

Adaptation of cervical margin of SS crown towards tooth surface is called? *

Chipping

Adaptation of Proximal surface of SS crown is called? *

Overhang

Give one indication of SS crown? *

Carious lesion

The content is neither correct nor will not be judged

Google Forms



Department of Pediatric & Preventive Dentistry

Write your name

Email address *

What is the composition of SS crown, which makes it shiny? *

Composition includes base, axial and occlusal. Oxidation makes it shiny

The newer technique wherein SS crown is placed on an unremoved caries is called? *

Hot technique

How SS crown can be used for correction of malocclusion? *

Can be used in correction of anterior cross bite, where in the crown is placed overjetly

Name a hypoplastic tooth condition where SS crown is indicated? *

Denticogenesis hypoplasia

Name one anterior crown with metal backing? *

Resin on crown

Write any one contraindication of SS crown *

Severe allergy

What will you do if you have a large SS crown but tooth is small? *

Put wax should place a band material and crown on top of it.

Adaptation of cervical margin of SS crown towards tooth surface is called? *

Chipping

Adaptation of Proximal surface of SS crown is called? *

Flare

Give one indication of SS crown *

Severely damaged tooth

Google Forms

