


CDCRI/OP/2020/06821.05.2020

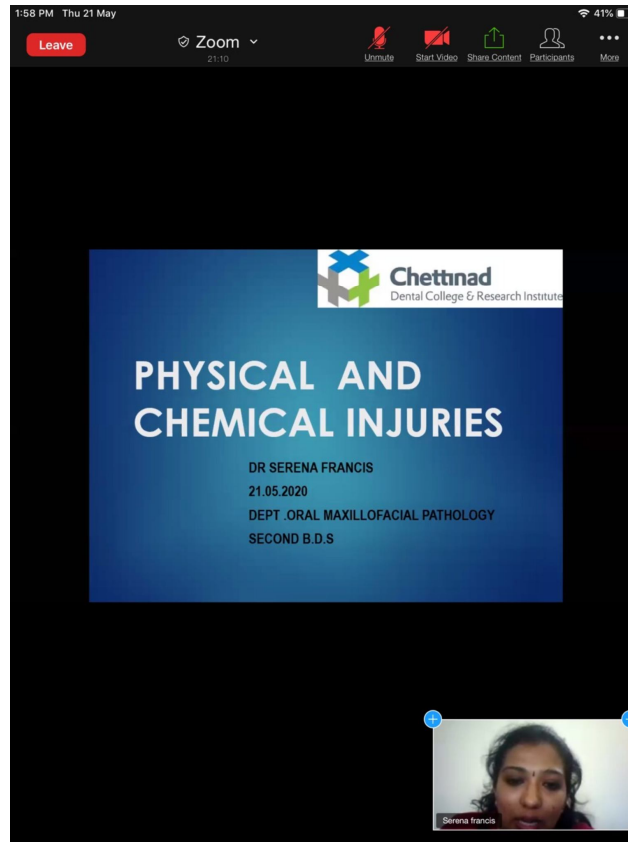
DEPARTMENT OF ORAL PATHOLOGY AND MICROBIOLOGY

RECORD OF e CLASS

PLATFORM	 https://us04web.zoom.us/j/72846571134?pwd=c0N5eFdFeFNsY0RwYTdnQnhpV0lJZz09
SESSION	WEBINAR –PHYSICAL AND CHEMICAL INJURIES
PRESENTING FACULTY	Dr. SERENA FRANCIS
DATE	21.05.2020
TIMING	1:30 to 3:30 pm
UG PARTICIPANTS	Second BDS-93 participants
FACULTIES ATTENDED	DrSathishMuthukumar,DrSreeja,DrNachiammai,DrMerlin,DrSerena,DrHariniPriya

FACULTY: DR.SERENAFRANCISPRESENTATION


SHARED SCREEN



1:58 PM Thu 21 May

Zoom 21:10

Leave Unmute Start Video Share Content Participants More

 **Chettinad**
Dental College & Research Institute

**PHYSICAL AND
CHEMICAL INJURIES**

DR SERENA FRANCIS
21.05.2020
DEPT .ORAL MAXILLOFACIAL PATHOLOGY
SECOND B.D.S

Serena Francis



FACULTY: DR.SERENA FRANCIS PRESENTATION

SHARED SCREEN

A screenshot of a Zoom meeting interface. The top status bar shows the time as 2:14 PM on Thursday, May 21st, and a battery level of 35%. The Zoom toolbar includes a 'Leave' button, the Zoom logo, and icons for Mute, Stop Video, Share Content, Participants, and More. The main content area displays a presentation slide with a blue gradient background. The slide title is 'Traumatic Ulcerative Granuloma with Stromal Eosinophilia(TUGSE)'. Below the title, there are two bullet points: '▶ Most often seen on tongue secondary to muscle damage' and '▶ Deep "pseudo-invasive" inflammatory reaction that is slow to resolve'. In the bottom right corner, there is a small video feed window showing a woman with dark hair, identified as 'Serena Francis'. A camera icon is visible in the bottom left corner of the Zoom window.



FACULTY: DR.SERENA FRANCIS PRESENTATION

SHARED SCREEN

2:05 PM Thu 21 May

Zoom 28/15

Leave Unmute Start Video Share Content Participants More

—Toothbrush Trauma.

- This injury occurs to the gingiva and is produced by the tooth brush.
- Appears as white, reddish or ulcerative lesions or linear superficial erosions,
- Involving marginal & attached gingiva of maxillary canine & premolar region.

A clinical photograph showing a close-up of a toothbrush head being used on a patient's teeth. The gingiva (gum tissue) is visibly irritated, showing white, reddish, and ulcerative lesions, particularly around the maxillary canine and premolar regions.

Serena Francis



FACULTY: DR. SERENA FRANCIS PRESENTATION
PARTICIPANT VIDEO TILE

The screenshot displays a Zoom meeting interface with 42 participants arranged in a 6x7 grid. The top bar shows 'Recording' and 'Speaker View'. The bottom toolbar includes 'Unmute', 'Stop Video', 'Participants' (100), 'Chat', 'Share Screen', 'Record', 'Reactions', and a 'Leave' button. The participants' names are listed below their respective video tiles.

Row	Column	Participant Name
1	1	Serena francis
1	2	Merlin Jayaraj
1	3	Gladson Samuel
1	4	gokulakannan.r
1	5	Joshini_M
1	6	Sujith Supradeep
1	7	Suweadha K
2	1	Marajitha Devi M
2	2	Gayathri P
2	3	Sinduja R
2	4	Shirin Sumaya
2	5	Prithivraj V
2	6	Subashini K
2	7	Sugi Rathna
3	1	Raja Rajeswari
3	2	Priyadarshini. C
3	3	Kansitha Kannan
3	4	AR anandhi
3	5	Sandhya
3	6	Sneha M.S.
3	7	Priya Sriram
4	1	arthick Sharan
4	2	Gayathri Sathiyamoo...
4	3	AlaguPriyadarshini...
4	4	Anandhi S
4	5	Krithika G
4	6	Dayanisha G
4	7	Sobana Kuppuraman
5	1	Riyukta Talupur
5	2	Lakshana Dhyanesh...
5	3	siva priya B
5	4	Roshni Ramesh
5	5	Max Million
5	6	Pooja Ravi
5	7	Akarna R
6	1	Sanjna Narendran
6	2	Bhavana Priyanka re...
6	3	Rekha Dillibabu
6	4	Janani J
6	5	Sangetha Mahendran
6	6	Lakshikha Sree
6	7	PadmaPriyadarshine
7	1	Rohini Karthikeyan
7	2	NANDHINI DEVI
7	3	Hyma Edward
7	4	Lovisha Seles
7	5	Lincy Jenisha J
7	6	Sathyapriya L
7	7	Lakshmi Priya



FACULTY: DR. SERENA FRANCIS PRESENTATION

PARTICIPANT VIDEO TILES