

**CHETTINAD DENTAL COLLEGE AND RESEARCH**  
**INSTITUTE DEPARTMENT OF PERIODONTICS AND**  
**IMPLANTOLOGY**  
**FINAL YEAR -(22.06.2020 to 27.06.2020)**

**THEORY CLASS E-DISCUSSIONS:**

S.No	Date	Lecture topic	Faculty	No of students participated
1.	26.06.2020	BONE LOSS AND PATTERNS OF BONE DESTRUCTION	Dr. SHANMUGAM	7

**CLINICAL DISCUSSIONS:**

S.No	Date	Lecture topic	Faculty	No of students participated
1.	25/06/2020	TRAUMA FROM OCCLUSION - JANANIS	All Faculty	31
2.	26/06/2020	FURCATION- PADMAJEE.S	All Faculty	35
3.	27/06/2020	CHRONIC PERIODONTITIS – AAKIFA.M	All Faculty	34



























**THEORY E--DISCUSSION ON 26/06/2020**

<b>NAME OF THE FACULTY</b>	Dr. SHANMUGAM
<b>TOPIC</b>	BONE LOSS AND PATTERNS OF BONE DESTRUCTION
<b>BATCH</b>	FINAL YEAR SUPPLEMENTARY BATCH

09:41 AM | 116KB/s | 🔊 🔋  
Close Participants (8)

🔍 Search

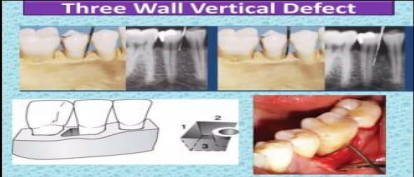
-  M. Thouseef Ahmed (me, host)  
-  M Shanmugam  
-  Dhanesh Bala  
-  Harini Prabha  
-  Harish Raghav  
-  Priyanga.V  
-  Ragavi vijayan  
-  Vishnu Kumar  

09:44 AM | 78.3KB/s | 🔊 🔋

🔊 📷 Zoom 15:05 End

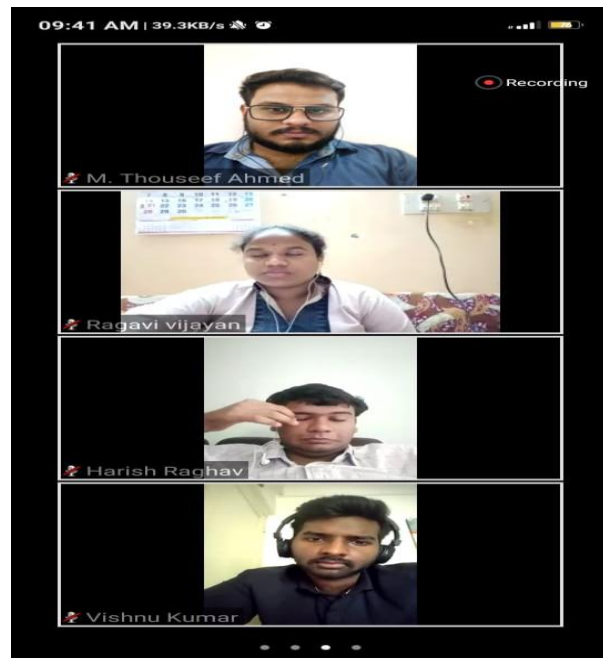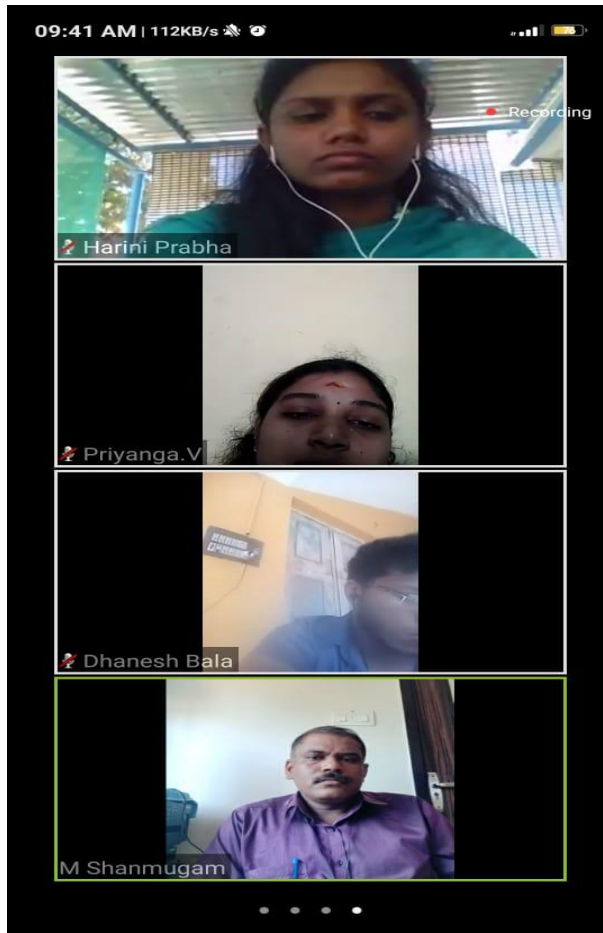
🔴 Recording

**Three Wall Vertical Defect**



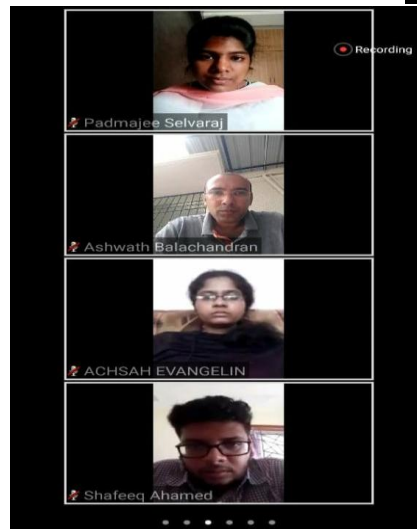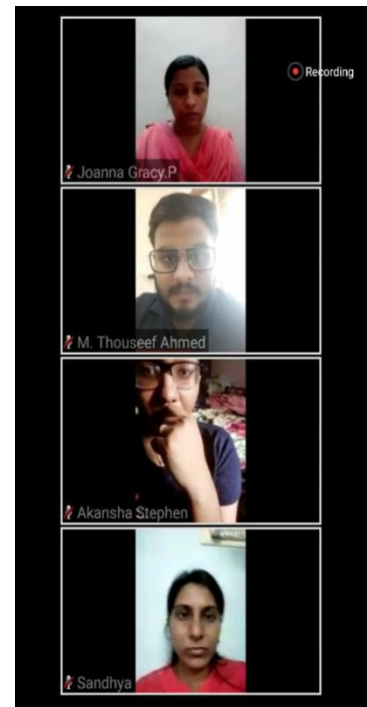
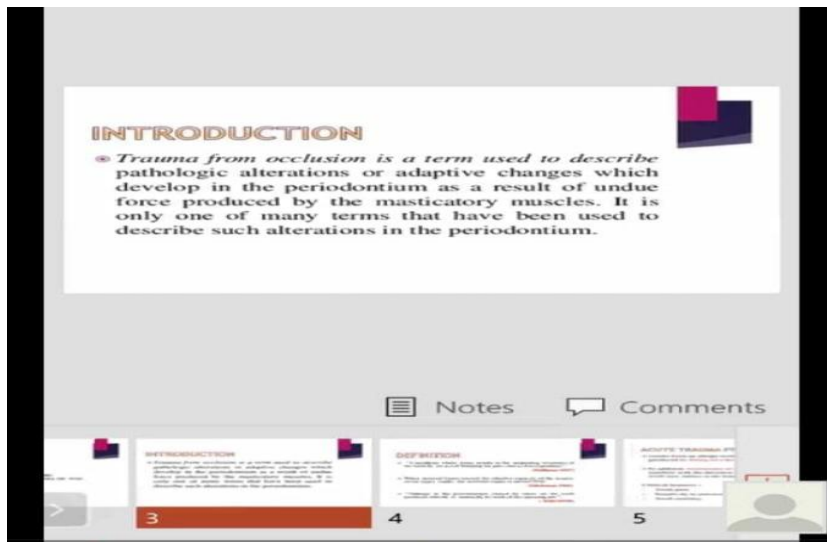🔴 📷 🗑️ 👤 ⋮

🔴 Stop Video Share Participants More



**CLINICAL E--DISCUSSION ON 25/06/2020**

<b>NAME OF THE FACULTY</b>	ALL FACULTY
<b>TOPIC</b>	TRAUMA FROM OCCLUSION – JANANIS
<b>BATCH</b>	FINAL YEAR BATCH

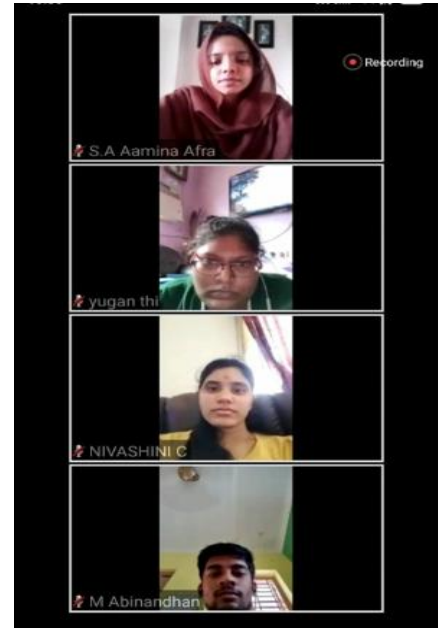



# Chettinad

Dental College & Research Institute

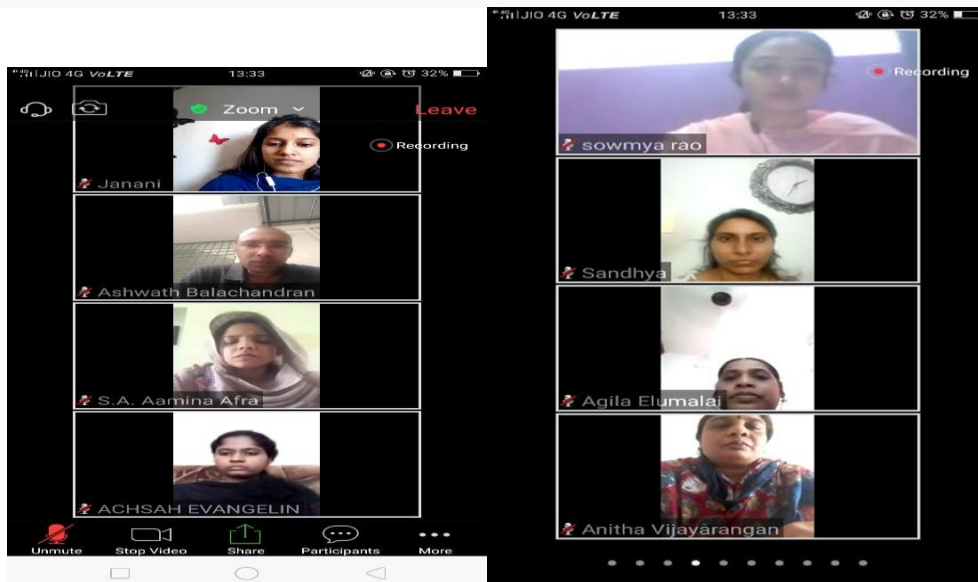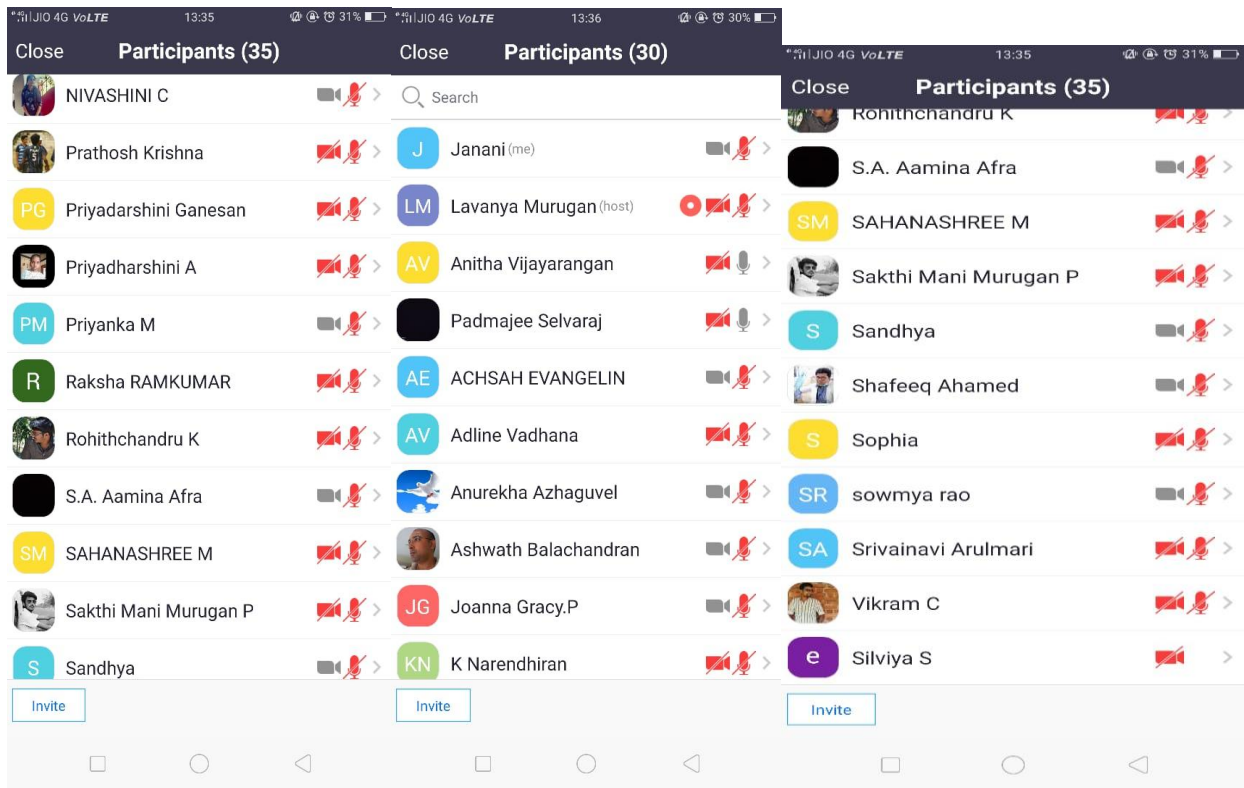
Close	Participants (31)
KN	K Narendhiran
MA	M Aakifa
MA	M Abinandhan
	M Shanmugam
	M. Thouseef Ahmed
	Martina Allen
	NIVASHINI C
	Prathosh Krishna
PG	Priyadarshini Ganesan
	Priyadharshini A
R	Raksha RAMKUMAR



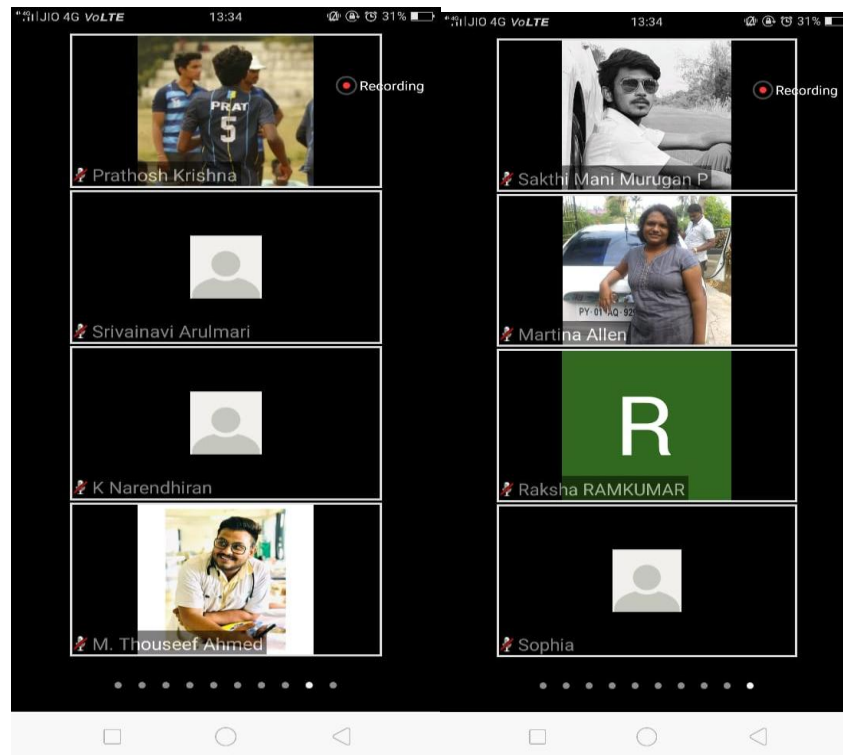
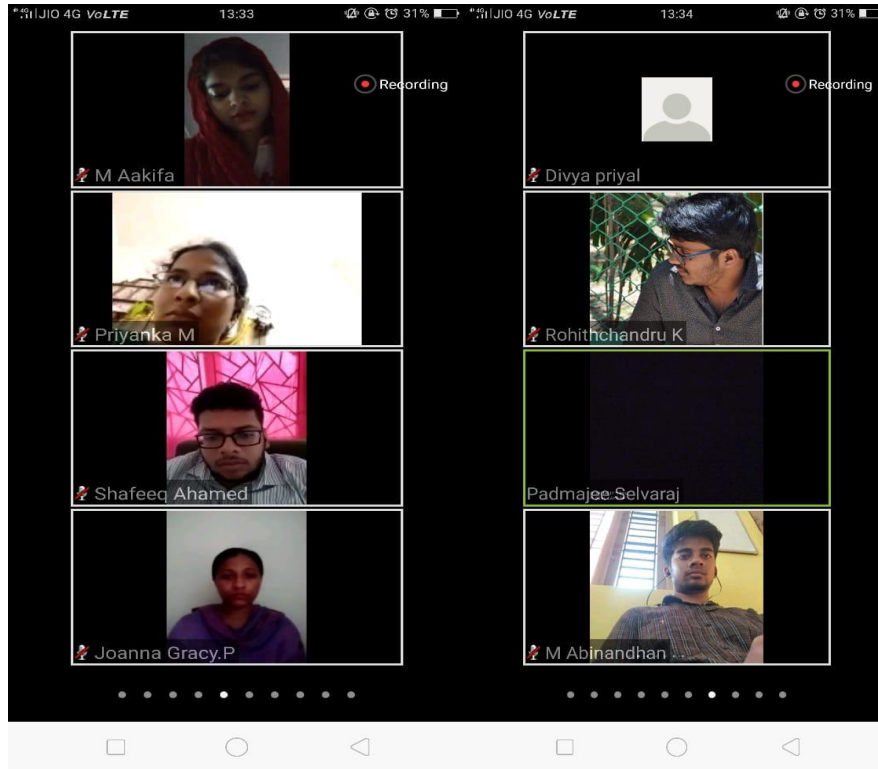
Close	Participants (31)
PG	Priyadarshini Ganesan
	Priyadharshini A
R	Raksha RAMKUMAR
	Rohithchandru K
	S.A. Aamina Afra
	Sakthi Mani Marugan P
S	Sandhya
	Shafesq Ahamed
e	Silviya S

**CLINICAL E--DISCUSSION ON 26/06/2020**

<b>NAME OF THE FACULTY</b>	ALL FACULTY
<b>TOPIC</b>	FURCATION- PADMAJEE.S
<b>BATCH</b>	FINAL YEAR BATCH









JIO 4G VoLTE 13:33 32%

Zoom Leave Recording

*\* Supra bony pocket involving soft tissue*  
*\* No radiographic changes*

**GRADE II**

Class I Class II

*\* Bone is destroyed in one or more aspects of the furcation, but a portion of alveolar bone and periodontal ligament remains intact*  
*\* Radiographic changes may or may not reveal the grade II involvement*

Unmute Stop Video Share Participants More



**CLINICAL E--DISCUSSION ON 27/06/2020**

<b>NAME OF THE FACULTY</b>	ALL FACULTY
<b>TOPIC</b>	CHRONIC PERIODONTITIS-AAKIFA.M
<b>BATCH</b>	FINAL YEAR BATCH

The screenshot displays three overlapping Zoom meeting participant lists. Each list includes a 'Close' button, a title, and a list of participants with their names, profile pictures, and status icons (mute, video off). At the bottom of each list is an 'Invite' button.

- Participants (33):**
  - Raksha RAMKUMAR
  - Rohithchandru K
  - S.A. Aamina Afra
  - SAHANASHREE M
  - Sakthi Mani Murugan P
  - Shafeeq Ahamed
  - Silviya S
  - Sophia
  - Sowmya rao
  - Srivainavi Arulmari
- Participants (34):**
  - Padmajee Selvaraj
  - Prathosh Krishna
  - Priyadarshini Ganesan
  - Raksha RAMKUMAR
  - Rohithchandru K
  - S.A. Aamina Afra
  - SAHANASHREE M
  - Sakthi Mani Murugan P
  - Shafeeq Ahamed
  - Silviya S
- Participants (34):**
  - C Achshah Evangelin (me)
  - Lavanya Murugan (host)
  - M Aakifa
  - Abirami Tm
  - Agila Elumalai
  - aishu durai
  - Akansha Stephen
  - Anitha Vijayarangan
  - Anurekha Azhaguel
  - Divya priyal



**Participants (34)**

- Diya
- Gayathri S
- Janani
- Joanna Gracy.P
- K Narendhiran
- M Abinandhan
- M Shanmugam
- M. Thouseef Ahmed
- Martina Allen
- NIVASHINI C

Zoom 12:48

Recording

**Localized:**  
Periodontitis is considered localized when <30% of the sites assessed in oral cavity demonstrate attachment loss and bone loss.

**Generalized:**  
Periodontitis is considered generalized when >30% of the sites assessed demonstrate attachment loss and bone loss. The pattern of bone loss in chronic periodontitis can be vertical or horizontal.

Unmute Stop Video Share Participants More

Recording

M Shanmugam

NIVASHINI C

R

Raksha RAMKUMAR

Janani

SAHANASHREE M

Agila Elumalai

A

Abirami Tm

Diya

Recording

Recording

**DISEASE PROGRESSION**

- The rate of disease progression is usually slow but may be modified by systemic and/or environmental and behavioral factors.
- Chronic periodontitis does not progress at an equal rate in all affected sites throughout the mouth.
- More rapidly progressive lesions occur:
  - Interproximal areas
  - Areas of greater plaque accumulation
  - Inaccessibility to plaque control measures (e.g., furcative areas, overhanging margins, sites of malposed teeth, or areas of food impaction)



Recording

Akansha Stephen

M. Abinandhan

Rohithchandru K.

Padmajee Selvara.j

Recording

Prathosh Krishna

Priyadarshini A

Silviya S

Priyadarshini Ganesan

Recording

Joanna Gracy.P

M. Akkifa

Shafeeq Ahmed

Lavanya Murugan

S.A. Aamina Afra

Srivainavi Arulmani

Anurekha Azhaguvel

M. Thouseef Ahmed